Turkish Archives of Otorhinolaryngology

Case Report

Turk Arch Otorhinolaryngol
DOI: 10.4274/tao.2025.2025-9-13

Oncocytic Sialolipoma of the Submandibular Gland: Case Report and Literature Review

Uğur Kamiloğlu[1], Mürsel Delil[1], Sabri Mutlu[1], Ayça Tan[2], Görkem Eskiizmir[1]

[1]Manisa Celal Bayar University Faculty of Medicine, Department of Otorhinolaryngology, Manisa, Türkiye
[2]Manisa Celal Bayar University Faculty of Medicine, Department of Pathology, Manisa, Türkiye

Abstract

Sialolipoma is a rare benign salivary gland tumor, most commonly arising in the parotid gland. Its oncocytic variant is exceedingly uncommon, particularly in the submandibular gland. We report a 58-year-old woman presenting with a painless, enlarging left submandibular mass. Imaging revealed a heterogeneous fat-containing lesion with calcifications and suspicious lymphadenopathy, and fine-needle aspiration suggested a salivary gland neoplasm of uncertain malignant potential. The patient underwent submandibular gland excision with selective neck dissection. Histopathological examination confirmed oncocytic sialolipoma, and no recurrence was observed during 24 months of follow-up. A literature review identified only nine previously reported submandibular sialolipoma cases, several with oncocytic features. Preoperative findings, including calcifications and oncocytic cytology, may mimic malignancy. However, a well-circumscribed lesion composed of mature adipose tissue with salivary gland elements is diagnostic. Oncocytic sialolipoma of the submandibular gland is exceptionally rare. Despite its potential to mimic malignancy, it is benign, and complete excision provides definitive diagnosis and excellent prognosis.

Keywords: Sialolipoma, submandibular gland, salivary gland neoplasms, lipoma, case reports

ORCID IDs of the authors:
U.K. 0000-0001-7257-7536
M.D. 0000-0002-5314-3115
S.M. 0000-0001-8922-9415
A.T. 0000-0003-4450-5425
G.E. 0000-0002-3125-8288

Cite this article as: *Kamiloğlu U, Delil M, Mutlu S, Tan A, Eskiizmir G. Oncocytic sialolipoma of the submandibular gland: case report and literature review. Turk Arch Otorhinolaryngol. [Epub Ahead of Print]*

Corresponding Author:
Uğur Kamiloğlu, MD;
ukamiloglu@gmail.com

Received Date: 16.10.2025
Accepted Date: 18.12.2025
Epub: 27.03.2026

Introduction

Sialolipoma is a rare benign salivary gland tumor characterized by islands of normal salivary gland tissue encased by mature adipose tissue without any atypia, preserving the normal ductal and acinar structures. First described by Nagao et al. (1) in 2001, it accounts for 0.3-0.5% of all salivary gland tumors. While it is most commonly observed in the parotid gland, its occurrence in the submandibular gland is exceedingly rare (1). An uncommon subtype of sialolipoma, known as oncocytic sialolipoma, is characterized by oncocytic metaplasia and has been reported in a limited number of cases in the literature (2).

In this case report, we present the clinical, radiological, and histopathological findings of a submandibular sialolipoma, a tumor rarely reported in the literature.

Case Report

A 58-year-old female patient presented to our clinic with a complaint of swelling in the left submandibular region. She reported that the swelling had been present for eight years

©Copyright 2026 by Turkish Otorhinolaryngology-Head and Neck Surgery Society / Turkish Archives of Otorhinolaryngology is published by Galenos Publishing House.
Licenced under Creative Commons Attribution-NonCommercial 4.0 International (CC BY-NC 4.0).

but had progressively enlarged following a recent dental procedure. At the time of presentation, there were no signs of compression or infiltration associated with the mass. There was no evidence of facial nerve involvement. The patient had no history of prior surgical procedures, no personal or family history of malignancy or radiotherapy. The mass measured 4×3 cm in size, was mobile and painless, had irregular borders without causing any skin involvement or discoloration.

Ultrasonography revealed a hypoechoic solid mass measuring 41×32×25 mm with irregular borders occupying nearly the entire left submandibular gland and exhibiting minimal vascularity on Doppler imaging. Additionally, two adjacent lymph nodes measuring 8.5 mm and 6.5 mm in short-axis diameter were noted; both were round, showed cortical thickening and a markedly narrow/effaced fatty hilum, and were therefore considered suspicious. Computed tomography (CT) revealed a lobulated mass within the left submandibular gland containing calcifications and heterogeneous fat density separated by septa, accompanied by adjacent lymph nodes with loss of fatty hilum and heterogeneous enhancement as shown in Figure 1. Fine-needle aspiration biopsy (FNAB) revealed groups of oncocytic cells, leading to a diagnosis of salivary gland neoplasm of uncertain malignant potential (SUMP). Considering the suspicion of malignancy based on preoperative radiological and FNAB results, the mass was excised along with the submandibular gland and selective neck dissection of levels I-III lymph nodes. Intraoperatively, a lobulated, lipomatous mass was observed in the left submandibular gland as shown in Figure 2. No complications occurred intra- or post-operatively.

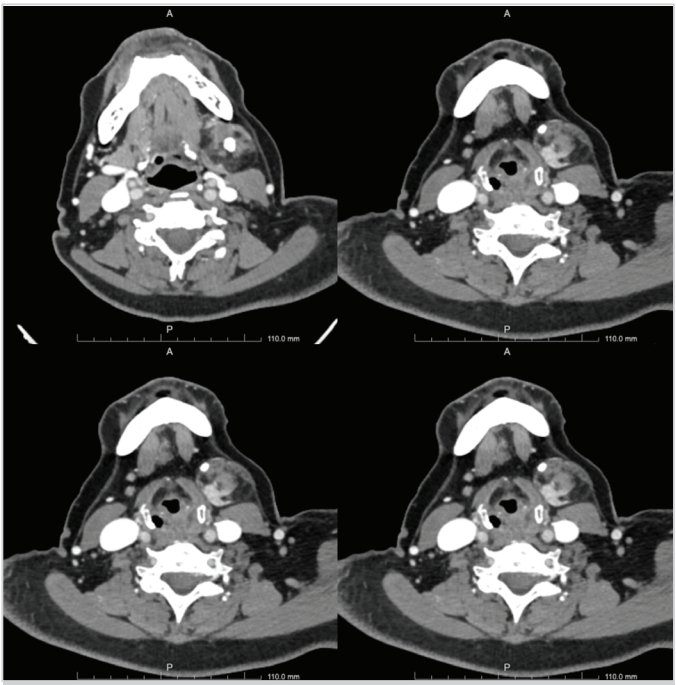

Figure 1. Contrast-enhanced axial CT images of the case
CT: Computed tomography

Histopathological examination revealed a 35 mm lesion with extensive intercalated ductal hyperplasia and focal areas of ossification. Normal salivary gland tissue and clusters of oncocytic cells were observed within mature adipose tissue. The oncocytic cells had eosinophilic cytoplasm and prominent nuclei as shown in Figure 3. Surgical margins were negative. The pathological diagnosis was oncocytic sialolipoma. The patient expressed satisfaction with the surgical outcome and relief upon confirmation of the benign nature of the lesion. No signs of recurrence were detected during 24 months of clinical and radiological follow-up. Written informed consent for publication was obtained from the patient for the data included in this case report.

Discussion

Our case was diagnosed as oncocytic sialolipoma. These tumors are exceedingly rare in the literature, with most reported cases originating from the parotid gland (3). This pathological entity, oncocytic sialolipoma, was first described by Pusiol et al. (2) in 2009, and the scarcity of the cases involving the submandibular gland highlight the significance of this report.

A review of the English-language literature indexed in PubMed was conducted to identify the reported cases of sialolipoma and oncocytic sialolipoma arising in the submandibular gland demonstrated a limited number of case reports. Based on this search, a total of nine well-documented cases of submandibular sialolipoma were identified in the literature as shown in Table 1 (2,4-11).

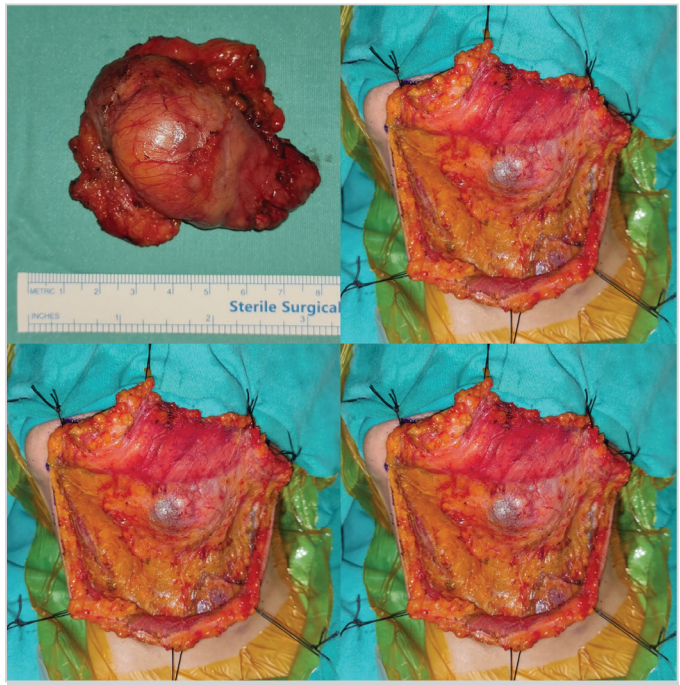

Figure 2. Intraoperative view of the mass

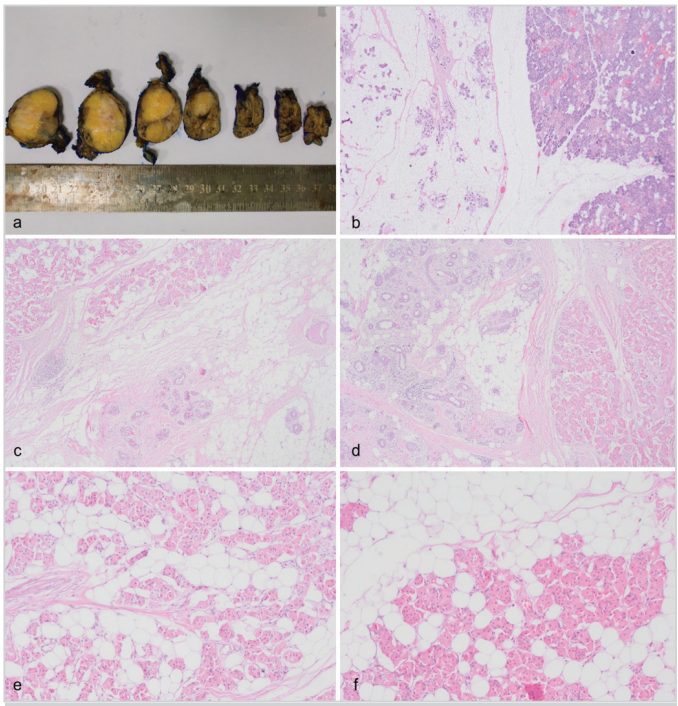

Figure 3. a) The cut surface is composed of well-circumscribed and bright yellow to pale brown tumoral lesion. **b)** Tumoral lesion (left side) with a sharp transition to the salivary gland parenchyma (right side) (H&E×40). **c-d)** Oncocytic and non-oncocytic epithelium and intercalated duct hyperplasia within the adipose tissue (H&E×100, H&E×100). **e-f)** The tumor consisted of salivary gland lobules with oncocytic features and mature adipose tissue (H&E×200, H&E×400)
H&E: Hematoxylin and eosin

The mean age of the reported patients was 49.1±22.3 years, indicating that sialolipoma in the submandibular gland generally affects adults. With the exception of a single pediatric case reported by Sato et al. (4), all cases occurred in older individuals, with a higher incidence after the fifth decade of life. The mean tumor size across the reported cases was 53.0±32.8 mm. Notably, several of these cases, including our case, demonstrated oncocytic metaplasia, supporting the proposition that oncocytic sialolipoma may constitute a distinct histological variant (2,8,10).

Despite being a benign tumor, this lesion, which is extremely rare in the submandibular gland, can display features of malignancy in preoperative imaging and/or FNAB. Due to radiological features mimicking malignancy, such as irregular borders and/or suspicious lymphadenopathy, the differential diagnosis can be confusing.

In major salivary gland tumors categorized as SUMP on FNAB, most contemporary algorithms recommend surgical excision of the involved gland for definitive diagnosis and treatment. The need for additional neck management is then tailored to the clinical and radiologic suspicion of lymph node involvement, rather than to the SUMP category alone (12). Consequently, the diagnostic value of FNAB in sialolipoma is considered limited.

Table 1. Clinicopathologic features of submandibular sialolipoma

Case no	Reference	Date	Age	Sex	Duration (months)	Region	Side	Tumor size (mm)	LN count	Largest LN size (mm)	Diagnosis	Oncocytic metaplasia	Treatment	Follow-up (month)	Recurrence
1	Presented case	2025	58	F	96	SMG	L	41×32×25	2	8.5	Oncocytic sialolipoma	Yes	SMG excision + level I-III ND	24	No
2	Parente et al. (5)	2008	77	F	Several months	SMG	R	30×20×18	NR	-	Sialolipoma	Yes	SMG excision	22	No
3	Pusiol et al. (2)	2009	73	M	NR	SMG	R	90	NR	-	Oncocytic sialolipoma	Yes	Tumor excision, gland preserved	NR	No
4	Jang et al. (6)	2009	62	F	36	SMG	R	50	NR	-	Sialolipoma	Yes	SMG excision	17	No
5	Sato et al. (4)	2011	3	M	2	SMG	L	40×30	0	-	Sialolipoma	NR	SMG excision	36	No
6	Akrish et al. (7)	2011	52	M	NR	SMG	NR	35×20×15	NR	-	Sialolipoma	Yes	SMG excision	12	No
7	Ahn et al. (8)	2014	43	F	2	SMG+PPS	R	40	NR	-	Oncocytic sialolipoma	Yes	Tumor excision, gland preserved	NR	NR
8	O'Rourke et al. (9)	2015	33	F	36	SMG	R	40×30	NR	-	Sialolipoma	NR	SMG excision	12	No
9	Parmar (10)	2015	45	M	12	SMG	L	27×17	0	-	Oncocytic sialolipoma	Yes	Tumor excision, gland preserved	NR	No
10	Subramaniam et al. (11)	2020	54	M	84	SMG+PPS	R	125×95×85	0	-	Sialolipoma	NR	SMG excision	1	No

SMG: Submandibular gland, PPS: Parapharyngeal space, ND: Neck dissection, LN: Lymph node, NR: Not reported, F: Female, M: Male, L: Left, R: Right

In our case, several features raised a strong preoperative suspicion of malignancy: (i) a long-standing mass with recent enlargement, (ii) heterogeneous fat-containing lesion with calcifications on CT, (iii) radiologically suspicious level I lymph nodes with round morphology, cortical thickening and loss of fatty hilum, and (iv) FNAB categorized as SUMP with oncocytic cells. Taken together, these findings were considered worrisome for a primary submandibular gland carcinoma with possible nodal involvement. For this reason, and in line with common practice for suspected submandibular gland malignancies, we elected to perform submandibular gland excision with selective neck dissection of levels I-III in a single stage.

Final histopathology confirmed a benign oncocytic sialolipoma with negative lymph nodes, and no recurrence was observed at 24 months. In light of the published literature, we do not propose routine neck dissection for sialolipoma; rather, we emphasize that neck dissection should be reserved for cases with convincing radiologic and/or intraoperative suspicion of malignant disease.

From a surgical decision-making standpoint, intraoperative frozen-section examination of the gland and/or lymph nodes or a staged approach (initial gland excision with or without node sampling, followed by delayed neck dissection only in case of malignancy on permanent sections) could also be considered in similar scenarios. In our case, because of the combination of a SUMP cytology with oncocytic cells, radiologically suspicious lymph nodes, and the heterogeneous calcified fatty mass, the multidisciplinary team favored a one-stage procedure including selective neck dissection. Nevertheless, we acknowledge that in retrospect, and particularly in light of the final benign diagnosis, a more conservative strategy such as gland excision with intraoperative frozen section followed by selective neck dissection only if malignancy was confirmed may have reduced the risk of overtreatment. We therefore highlight these alternative strategies in order to guide individualized management in future cases.

All published cases of submandibular sialolipoma, surgical resection was the definitive and uniformly applied treatment modality as shown in Table 1 (2,4-11). This consistent management approach underscores that complete surgical excision is both the diagnostic and therapeutic gold standard for sialolipoma.

Conclusion

Oncocytic sialolipoma is a rare salivary gland tumor, and its presence in the submandibular gland is particularly unusual only 10 cases, including our case, have been described in literature. The clinical, radiological, and cytological differential diagnosis is challenging. To date, no recurrences have been reported in sialolipoma of the submandibular gland which may indicate the benign nature and clinical course of these tumors. Complete surgical excision remains the gold standard for both definitive diagnosis and treatment.

Ethics

Informed Consent: Written informed consent for publication was obtained from the patient for the data included in this case report.

Footnotes

Authorship Contributions

Surgical and Medical Practices: U.K., G.E., Concept: U.K., G.E., Design: G.E., Data Collection and/or Processing: U.K., M.D., S.M., A.T., Analysis or Interpretation: U.K., M.D., A.T., G.E., Literature Search: U.K., S.M., Writing: U.K., G.E.

Conflict of Interest: The authors declare that they have no conflict of interest.

Financial Disclosure: The authors declare that this study has received no financial support.

Main Points

- Oncocytic sialolipoma of the submandibulary gland is an exceptionally rare bening tumor that can mimic malignancy on imagining and cytology.
- Heterogeneous fat-containing lesions with suspicious lymph nodes should include sialolipoma in the differential diagnosis to avoid misinterpretation and over treatment.
- Definitive diagnosis is histopathological, and complete surgical excision ensure an excellent prognosis with no reported recurrence.

References

1. Nagao T, Sugano I, Ishida Y, Asoh A, Munakata S, Yamazaki K, et al. Sialolipoma: a report of seven cases of a new variant of salivary gland lipoma. Histopathology. 2001; 38: 30-6. [Crossref]
2. Pusiol T, Franceschetti I, Scialpi M, Piscioli I. Oncocytic sialolipoma of the submandibular gland with sebaceous differentiation: a new pathological entity. Indian J Pathol Microbiol. 2009; 52: 379-82. [Crossref]
3. Sureja VP, Tagore KR. Oncocytic sialolipoma of parotid gland: case report and literature review. Indian J Pathol Microbiol. 2023; 66: 591-3. [Crossref]
4. Sato K, Gotoh C, Uchida H, Kawashima H, Yoshida M, Kitano Y, et al. Sialolipoma of the submandibular gland in a child. J Pediatr Surg. 2011; 46: 408-10. [Crossref]
5. Parente P, Longobardi G, Bigotti G. Hamartomatous sialolipoma of the submandibular gland: case report. Br J Oral Maxillofac Surg. 2008; 46: 599-600. [Crossref]

6. Jang YW, Kim SG, Pai H, Park JW, Lee YC, Rotaru H. Sialolipoma: case report and review of 27 cases. Oral Maxillofac Surg. 2009; 13: 109-13. [Crossref]
7. Akrish S, Leiser Y, Shamira D, Peled M. Sialolipoma of the salivary gland: two new cases, literature review, and histogenetic hypothesis. J Oral Maxillofac Surg. 2011; 69: 1380-4. [Crossref]
8. Ahn D, Park TI, Park J, Heo SJ. Oncocytic sialolipoma of the submandibular gland. Clin Exp Otorhinolaryngol. 2014; 7: 149-52. [Crossref]
9. O'Rourke C, Khan H, Wallis F, Fenton JE. Lipomas of the submandibular space: case report of a sialolipoma and review of diagnostic investigations available. J Oral Maxillofac Surg. 2015; 73: 99-105. [Crossref]
10. Parmar HV. Oncocytic lipoadenoma of submandibular gland: a case report. J Clin Diagn Res. 2015; 9: ED05-6. [Crossref]
11. Subramaniam S, Johan S, Hayati F, Ng CY, Azizan N, Chuah JA, et al. Giant submandibular sialolipoma masquerading as huge goitre: a case report. BMC Surg. 2020; 20: 130. [Crossref]
12. Rossi ED, Faquin WC, Vielh P, editors. The Milan system for reporting salivary gland cytopathology. 2nd ed. Cham: Springer; 2023. [Crossref]