



Unusual Case of Fishhook Lodged in the Neck: A Case Report and Literature Review

Case Report

✉ Anne Marie Daou¹, ✉ Omar Aboul Hosn¹, ✉ Jad Hosri¹, ✉ Afif Mufarrij²,
✉ Zeina Korban¹

¹American University of Beirut Medical Center, Clinic of Otolaryngology-Head and Neck Surgery, Beirut, Lebanon

²American University of Beirut Medical Center, Clinic of Emergency Medicine, Beirut, Lebanon

Abstract

Fishing constitutes a widely practiced sport considered pleasant and harmless. Yet, there are specific risks associated with fishhook injuries specifically in the neck. To the best of our knowledge, only few articles on fishhook injury in the neck were reported in the literature. We present the case of a 57-year-old previously healthy male coming to the emergency department with a J-type fishhook accidentally lodged in his neck. Prompt management with bedside removal of the sharp foreign body from the neck was achieved with no subsequent complications. In this case report, literature review of fishhook types and injuries as well as management options of such penetrating injuries will be detailed.

Keywords: Neck injuries, penetrating trauma, penetrating wounds, foreign bodies, fishhooks, wound management, case report

Introduction

Fishing is a widely practiced and seemingly harmless sport, yet fishhook incidents present specific risks. These injuries most commonly affect the hands but can also impact the head and neck, with the eyes and nose being the most frequently involved areas. Notably, fishhook injuries to the neck, which can be classified as penetrating anterior neck injuries, have not been documented in the literature. The neck's intricate anatomy includes essential, relatively unprotected structures, rendering it susceptible to severe vascular injuries such as occlusion, dissection, pseudoaneurysm, blood extravasation, or arteriovenous fistula formation. Approximately 25% of

penetrating neck injuries involve arterial damage (1). Currently, no international consensus guidelines exist for managing these injuries, and published guidelines typically emphasize traditional zonal approaches.

Case Presentation

The authors present the case of a 57-year-old previously healthy male who arrived at the emergency department with a fishhook injury to the neck. The injury occurred while the patient was walking by the seaside, when a fisher accidentally cast his rod in the wrong direction, lodging the hook in the patient's neck. The patient arrived at the hospital ambulating and breathing comfortably, with stable

ORCID IDs of the authors:

A.M.D. 0009-0004-2794-7795
O.A.H. 0009-0000-0891-2395
J.H. 0000-0002-7781-3486
A.M. 0000-0001-7323-4359
Z.K. 0000-0003-3233-9642

Cite this article as: Daou AM, Hosn OA, Hosri J, Mufarrij A, Korban Z. Unusual case of fishhook lodged in the neck: a case report and literature review. *Turk Arch Otorhinolaryngol.* 2025; 63(1): 44-47

Corresponding Author:

Zeina Korban, MD;
zk27@aub.edu.lb

Received Date: 08.10.2024

Accepted Date: 28.01.2025

Epub: 10.04.2025

Publication Date: 19.06.2025

DOI: 10.4274/tao.2025.2024-9-2



vital signs. He reported no neck pain, drooling, dysphonia, respiratory distress, dysphagia, or odynophagia.

Physical examination revealed a palpable fishhook on the right side of the neck, with its shank external to the skin and the sharp, curved part palpable in the subcutaneous plane Figure 1. There was no palpable collection or rapidly expanding hematoma. A bedside flexible laryngoscopy showed no evidence of a foreign body in the upper airway.

Neck X-ray and ultrasound (US) were performed Figures 2-3. The US revealed a J-type fishhook traversing the

deep subcutaneous fat planes medially, with its tip oriented anteriorly and near a small vein, likely a branch of the anterior jugular vein. No major vessels were in proximity to the hook, and no hematoma was detected Figure 4.

The hook was removed in the radiology room under local anesthesia with lidocaine injections to the anterior neck. The hook was advanced to pierce the skin, externalizing its tip. The sharp tip and barb were cut and separated from the rest of the hook using a ring cutter and forceps, and the remaining smooth part was then retrieved Figures 5-6. A post-procedural US confirmed no acute injury to major vessels and no hematoma. The patient tolerated the procedure with minimal discomfort. He received a tetanus vaccine and was discharged home the same day with a course of amoxicillin-clavulanic acid.

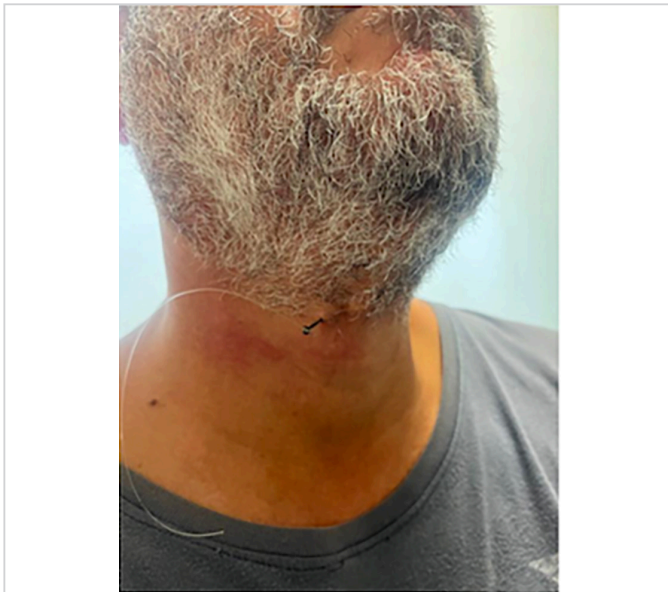

Figure 1. Fishhook in the neck upon patient presentation to the emergency department

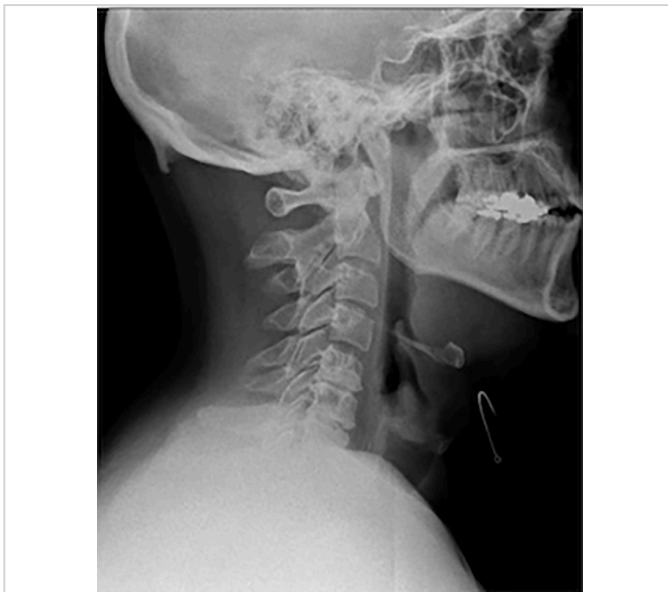

Figure 2. Neck X-ray in sagittal view of the fishhook stuck in the anterior subcutaneous fat of the neck, midline position. Note that the upper airways are intact

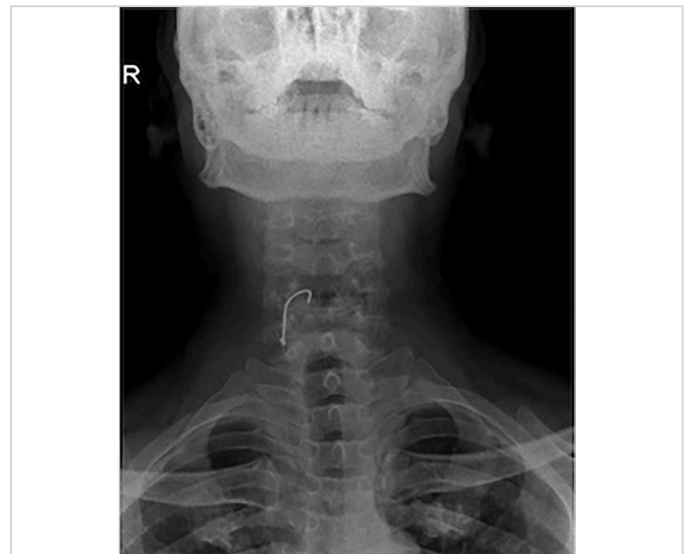

Figure 3. Neck X-ray in coronal view of the fishhook stuck in the anterior subcutaneous fat of the neck, midline position. Note that the upper airways are intact

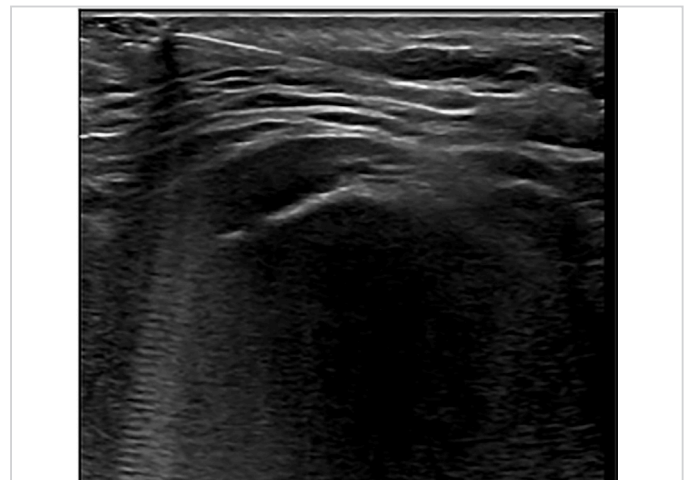


Figure 4. Ultrasound of the neck done prior to removal of fishhook showing the sharp foreign body penetrating in the subcutaneous plane with its tip inside

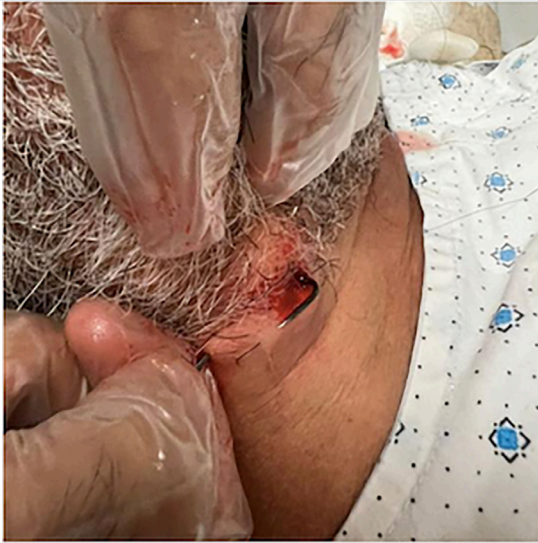

Figure 5. Successful advancement and cutting technique of the fishhook

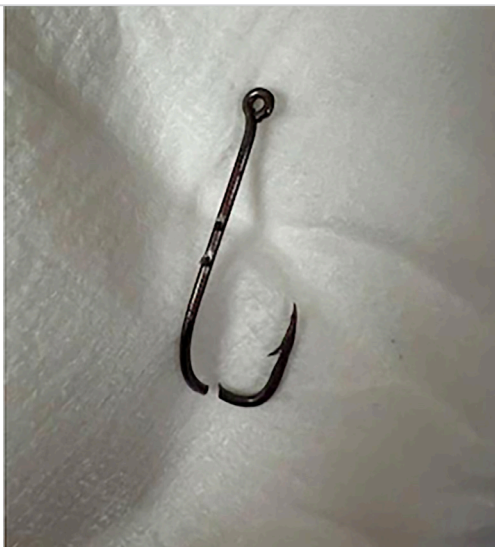

Figure 6. J-type fishhook with its barb

Discussion

Fishing carries inherent risks particularly due to the sharply curved metal hooks used. There are various types of fishing hooks, including bait hooks, J hooks, circle hooks, and treble hooks, which can be equipped with or without barbs near the tip to secure the fish on the line. Barbless fishhooks reduce the likelihood of severe injuries (1). In our case, the neck was injured by a barbed J hook. Despite their superficial appearance, barbed hooks introduce a significant risk of dangerous internal injuries, especially when located near vital structures such as vessels, nerves, or tendons (2).

Historical reports like the one by Townsend (3) in 1848 highlight the challenges of removing fishhooks from

sensitive areas such as the neck. Townsend's (3) description of extracting a fishhook from the neck underscores the persistent need for effective removal techniques when hooks embed near critical structures. The most commonly affected body part is the hand, followed by the head and eyes (2, 4). Rare instances of fishhook injuries to the nose and pinna have been reported only twice and once, respectively (4-6). An unusual case reported by Sa'adudeen Idris et al. (7) in 2023 involved the unintentional ingestion of a fishhook by an elderly woman, with the hook becoming entangled over the left greater horn of the hyoid bone, necessitating surgical removal.

Although there are no established guidelines for safe fishhook removal, the literature describes four main techniques: retrograde, string pull, needle cover, and advance/cut techniques. The latter involves advancing the hook through the skin surface, clipping the barb with ring cutters or flattening it with pliers, and then performing a smooth retrograde removal of the fishhook. The choice of removal method depends on factors such as the type of fishhook, its location, and the depth of tissue penetration (4). A single study assessing success rates identified the advance and cut technique as the most effective (8). Remarkably, fishhook injuries involving the anterior neck remain unreported.

Penetrating neck injuries, accounting for 5% to 10% of all trauma cases, have a mortality rate up to 10%, with vascular injuries being the leading cause of death (9). Injuries breaching the platysma layer are considered more severe. Anatomically, these injuries are categorized into three zones, each requiring different management strategies. Zone I, spanning from the clavicles to the cricoid cartilage, is the most serious and potentially lethal. Zone II, extending from the cricoid cartilage to the angle of the mandible, is the most commonly injured and is the easiest to access surgically, with a low risk of adverse outcomes. Zone III, covering the area between the angle of the mandible and the skull base, is challenging to examine and surgically explore. Management of these injuries depends on the zone involved and the specific vascular and anatomical structures within each zone (10).

Our case involved a zone II penetrating injury that reached the subcutaneous plane. Although the tip of the hook was near a small branch of the anterior jugular vein, there was no vascular injury or expanding hematoma. The patient remained asymptomatic during serial examinations. Given the absence of expanding or pulsatile hematoma, bleeding, neurological deficits, hemoptysis, or dysphonia, we opted for bedside fishhook removal. The advance and cut technique was chosen due to its documented success rates in the literature. The decision was supported by the patient's hemodynamic stability, the superficial positioning of the fishhook, and the use of duplex ultrasonography for guidance.

Conclusion

Fishhook lodged in the neck is an extremely rare injury with only few previously reported cases. Prompt recognition and appropriate management of such injuries are crucial to prevent complications such as bleeding, pulsatile hematoma, or neurological injury. In our case, US-guided removal was performed, with pre- and post-procedural radiologic evaluation of the neck. In severe cases with a higher risk of major vessel injury, surgical removal in a controlled setting is recommended.

Ethics

Informed Consent: Since patient-identifying information were not presented in this case report, only verbal informed consent was obtained from the patient's caregivers to participate in this study.

Footnotes

Authorship Contributions

Surgical and Medical Practices: A.M., Z.K., Concept: A.M., Z.K., Design: A.M., Z.K., Data Collection and/or Processing: A.M.D., Analysis and/or Interpretation: A.M.D., O.A.H., Literature Search: A.M.D., O.A.H., J.H., Writing: A.M.D., O.A.H., J.H.

Conflict of Interest: There is no conflict of interest to disclose.

Financial Disclosure: The authors declared that this study has received no financial support.

Main Points

- Fishing carries rare but serious risks, particularly related to fishhook injuries in the neck.
- The fishhook can be safely extracted at the bedside without the need for more invasive procedures.
- Careful removal was crucial in avoiding complications such as infection, damage to surrounding structures, or further injury.
- Monitoring for any delayed complications and providing appropriate wound care are essential to ensure the patient's full recovery.

References

1. Nowicki JL, Stew B, Ooi E. Penetrating neck injuries: a guide to evaluation and management. *Ann R Coll Surg Engl.* 2018; 100: 6-11. [Crossref]
2. Ahmad Khan H, Kamal Y, Lone AU. Fish hook injury: removal by "push through and cut off" technique: a case report and brief literature review. *Trauma Mon.* 2014; 19: 17728. [Crossref]
3. Townsend SD. Extraction of a fish-hook from the neck. *NEJM.* 1848; 39: 169-70. [Crossref]
4. Kiu KL, Chew SC, Heng PS. Fishing at home during Covid-19 lockdown period: a rare presentation of penetration fishhook at nasal bridge. *J Otolaryngol Rhinol.* 2020; 6: 086. [Crossref]
5. Kar R, Jagade MV, Anoop A, Kedar S, Rohe D, Khairnar P, et al. An entangled fishhook in nose: a tricky case. *Int J Otolaryngol Head Neck Surg.* 2014; 3: 137-9. [Crossref]
6. Mohamed Awang K, Abdullah SN, Mohamad I. Reprint of: fishhook removal from the pinna of the ear. *Dis Mon.* 2022; 68: 101394. [Crossref]
7. Sa'adudeen Idris O, Omokanye HK, Peter Adeoye O, Ige OA, Jimoh M, Ominigbo OB, et al. Pharyngeal fish hook impaction: case report and literature review. *Ear Nose Throat J.* 2023: 1455613231189951. [Crossref]
8. Doser C, Cooper WL, Ediger WM, Magen NA, Mildbrand CS, Schulte CD. Fishhook injuries: a prospective evaluation. *Am J Emerg Med.* 1991; 9: 413-5. [Crossref]
9. Varghese A. Penetrating neck injury: a case report and review of management. *Indian J Surg.* 2013; 75: 43-6. [Crossref]
10. Shiroff AM, Gale SC, Martin ND, Marchalik D, Petrov D, Ahmed HM, et al. Penetrating neck trauma: a review of management strategies and discussion of the 'No Zone' approach. *Am Surg.* 2013; 79: 23-9. [Crossref]