



# Post-Pandemic Surge in Complications of Acute Otitis Media

## Original Investigation

✉ Mehmet Korkmaz, ✉ Fakih Cihat Eravcı, ✉ Mehmet Akif Eryılmaz,  
✉ Hamdi Arbağ

Necmettin Erbakan University Faculty of Medicine, Department of Otorhinolaryngology, Konya, Türkiye

## Abstract

**Objective:** Acute otitis media (AOM), a common middle ear infection, can lead to severe complications if not properly managed. The coronavirus disease 2019 (COVID-19) pandemic significantly impacted healthcare delivery and disease management. This study aimed to evaluate the incidence of complicated AOM cases from the pre-pandemic to post-pandemic period.

**Methods:** A retrospective review was conducted at Necmettin Erbakan University, Department of Otolaryngology, on patients diagnosed with complicated AOM in the period from January 2014 to February 2024. Patients were categorized into three periods: pre-pandemic (2014-2020), pandemic (2020-2022), and post-pandemic (2023-2024). Clinical data, including demographics, types of AOM complications, and treatment methods, were analyzed.

**Results:** A total of 32 patients (20 females and 12 males) with AOM complications were identified. Mastoiditis was the most common complication, seen in 43.75% of the patients, with increased incidences of 64.3% in the post-pandemic period. Subperiosteal abscess was noted in 12.5 % of the patients, exclusively in the pandemic and post-pandemic periods. Facial nerve paralysis (12.5%) and labyrinthitis (9.3%) were noted only in the post-pandemic period. Meningitis was noted in 15.6% of the patients, with increased incidences in the post-pandemic period. Observed during the post-pandemic period, sigmoid sinus thrombosis was noted in only one patient (3.1%).

**Conclusion:** Despite the reduced AOM incidence rates during the early pandemic, a surge was seen in complicated AOM cases in the post-pandemic period. This increase could be linked to COVID-19's impact on the immune system, pathogen virulence changes, and disruptions in vaccination protocols. These findings highlight the need for improved surveillance of AOM cases regarding complications in the post-pandemic era.

**Keywords:** Pandemics, coronavirus disease 2019, otitis media, complications, mastoiditis, facial paralysis

### ORCID IDs of the authors:

M.K. 0009-0003-4440-2597  
F.C.E. 0000-0001-9092-7923  
M.A.E. 0000-0001-5281-969X  
H.A. 0000-0001-6146-8801

**Cite this article as:** Korkmaz M, Eravcı F, Eryılmaz MA, Arbağ H. Post-pandemic surge in complications of acute otitis media. Turk Arch Otorhinolaryngol. 2025; 63(2): 61-68

### Corresponding Author:

Mehmet Korkmaz  
mehmetkorkmaz782@gmail.com

**Received Date:** 14.01.2025

**Accepted Date:** 27.05.2025

**Publication Date:** 27.06.2025

**DOI:** 10.4274/tao.2025.2024-11-3

## Introduction

Acute otitis media (AOM) is the infection of the middle ear caused by bacterial or viral pathogens leading to inflammation and fluid buildup behind the eardrum. AOM is one of the most common diagnoses seen in childhood. It affects

nearly 750 million people globally and is the most frequent infection that is prescribed with antibiotics in pediatric patients (1). Although it is accepted as a benign condition with treatment and preventive options, it can progress to complications, particularly if left untreated



or inadequately managed. The complications of AOM have a broad range, from intratemporal to intracranial, and could result in life threatening conditions. The most common intratemporal complication is mastoiditis, while the most commonly seen intracranial complication is meningitis (2). Accessibility to antibiotics and generalized application of vaccination has dramatically decreased the frequency of these complications of AOM. Whereas a shortage of specialists in underdeveloped countries and long waiting lists in developed countries are of public health concern in preventing these complications.

The emergence of the coronavirus disease 2019 (COVID-19) pandemic led to significant disruptions in healthcare systems worldwide, profoundly affecting the epidemiology and management of infectious diseases. Non-pharmaceutical interventions such as social restrictions, universal masking, social distancing, and national lockdowns were implemented to reduce COVID-19-related morbidity and mortality. These social restrictions also contributed to a noticeable decrease in hospital admissions for AOM, acute tracheitis, and acute laryngitis which are caused by other microorganisms (3). However, during the post-pandemic period with the relaxation of the social restrictions, there was a subsequent increase in severe upper respiratory infections which led to complications that required surgical intervention (2). Infections, which decreased throughout the pandemic, began to reappear in increasing numbers, revealing more complicated consequences in the post-pandemic period.

The increase in complicated infections observed in the post-pandemic period is believed to be linked to the effects of the pandemic itself, as well as to the changes in the virulence of the causative microorganisms. One key factor is the disruption of the immune system caused by the severe acute respiratory syndrome coronavirus 2 (SARS-CoV-2) virus. A study by Hopkins et al. (4) has shown that SARS-CoV-2 could impair the development of long-term immune responses, potentially weakening the body's ability to effectively combat infections, including AOM, and increasing the risk of complications.

Another significant consequence of the pandemic has been the interruption of routine vaccination programs, even in developed countries. The reduction in well-child visits during the pandemic led to fewer opportunities for administering essential vaccinations, which may have contributed to the observed rise in infections caused by microorganisms other than SARS-CoV-2 (5). Moreover, changes in the virulence of pathogens during this period resulted in weaker immune responses and reduced the efficacy of medical treatments, including antibiotics, thereby increasing the incidence of secondary complications.

In this context, we aimed to investigate the effect of the COVID 19 pandemic on the incidence of complicated AOM cases from the pre-pandemic to the post-pandemic period.

## Methods

We retrospectively analyzed the records of AOM patients who were diagnosed based on the American Academy of Pediatrics, 2013 AOM Clinical Practice Guideline and the American Academy of Otolaryngology-Head and Neck Surgery, 2016 OME Clinical Practice Guideline (6,7). Patients who were admitted to Department of Otolaryngology, Necmettin Erbakan University, Turkey between January 2014 and February 2024 with complicated AOM were included in the study. A total of 4,207 AOM cases were analyzed. The inclusion criteria for complicated otitis media were based on the presence of complications such as mastoiditis, facial nerve paralysis (FNP), meningitis, indicating that the infection did not remain confined to the middle ear but spread to the surrounding tissues, affecting intracranial and extracranial areas.

In patients who developed complications after AOM, physical examination, laboratory findings, and imaging methods such as computed tomography (CT) and magnetic resonance imaging were used during the diagnostic process. Acute mastoiditis was diagnosed based on physical examination findings such as redness and swelling behind the ear, forward displacement of the auricle, otalgia, and high fever, along with temporal CT findings showing loss of mastoid bone aeration and increased soft tissue density. Grading of FNP in patients performed according to House-Brackmann grading scale. The diagnosis of meningitis was established by analyzing the cerebrospinal fluid obtained through lumbar puncture in patients presenting with symptoms such as high fever, neck stiffness, headache, and altered consciousness. The diagnosis of subperiosteal abscess was established in patients with clinical findings such as prominent swelling, redness, tenderness behind the ear, and anterior displacement of the auricle. The diagnosis was confirmed by contrast-enhanced temporal CT, demonstrating mastoid bone destruction and fluid accumulation in the periosteal space. The diagnosis of labyrinthitis was established based on the clinical evaluation in patients with sudden-onset vertigo, hearing loss, and tinnitus, confirmed by audiological tests revealing hearing impairment.

Patients whose information was not available, or incomplete, were excluded from the study. Patients who had genetic disorders with immune dysregulation, patients who were using immune suppression drugs were excluded from the study.

The pandemic period in Türkiye began in March 2020 with the arrival and rapid spread of the first COVID-19 case. The years 2020-2022 were considered the COVID-19 pandemic period, during which lockdowns, online education, travel restrictions, and a nationwide vaccination campaign were implemented. After 2022, with the complete removal of the mask mandate in indoor spaces and the lifting of other

restrictions, Türkiye transitioned into the post-pandemic period. Therefore, in our study, the periods were divided into three phases: the pre-pandemic (January 2014-February 2020), the pandemic (March 2020 - December 2022), and the post-pandemic (January 2023 - February 2024). Demographic data, clinical findings of the patients, their complications, treatment modalities, and clinical outcomes were noted.

This study was approved by the Non-Interventional Clinical Research Ethics Committee of Necmettin Erbakan University (approval no: 2024/4910, date: 05.04.2024). Clinical observation was conducted in accordance with the principles of good clinical practice.

### Statistical Analysis

Data was analyzed using SPSS 22.0 software. The normality of data distribution was studied using the Kolmogorov-Smirnov test. Depending on the normality assumption, the distribution of patients' demographic characteristics was presented as mean  $\pm$  standard deviation or median (minimum-maximum). Categorical variables were expressed as absolute frequencies and percentages.

No inferential statistical tests were performed, and data was presented descriptively to provide an overview of the patient population, complications, and trends across the pre-pandemic, pandemic, and post-pandemic periods.

## Results

The study results have revealed that 32 patients were diagnosed with complications secondary to AOM in the study period. These complications included mastoiditis, subperiosteal abscess, FNP, meningitis, labyrinthitis, and sigmoid sinus thrombosis. The cohort had a mean age of  $27.5 \pm 26.7$  years, ranging from two months to 75 years. Of the 32 patients, 20 (62.5%) were female and 12 (37.5%) were male. Eighteen of the patients were in the pediatric age group under 18 years, while 14 were over 18 years. The predominant presenting symptom was otalgia, reported in 85% of the cases. The distribution of diagnoses along with the years are shown in Table 1 and Figure 1.

During the pre-pandemic period (2014-2020), the number of AOM cases admitted to our hospital was 2,998, while the number of complicated AOM cases was Four. During the pandemic period (2020-2022), the number of admitted AOM cases was 856, with six cases of complicated AOM. In the post-pandemic period (2023-2024), the number of admitted AOM cases was 353, while the number of complicated AOM cases had risen to 22. A significant rise in the proportion of complicated AOM cases among total AOM cases was observed, particularly during the pandemic and post-pandemic periods. The number of total AOM and complicated AOM cases by years are shown in Figure 2.

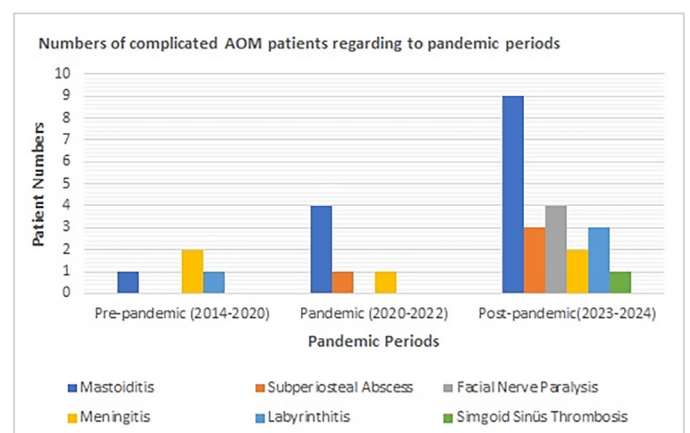
Additionally, while all complicated AOM cases presenting to our hospital during the pre-pandemic period were adult patients, the majority of complicated AOM cases during the pandemic and post-pandemic periods consisted of pediatric patients. Among the six complicated AOM patients in the pandemic period, four were in the pediatric age group, whereas among the 22 complicated AOM patients in the post-pandemic period, 14 were in the pediatric age group. Compared to the pre-pandemic period, the incidence of complicated AOM cases in the pediatric patient population had significantly increased.

Mastoiditis was the most common complication affecting 14 patients (43.75%). Analysis revealed a notable shift in the incidence across periods: one patient (7.1%) in the pre-pandemic period, four patients (28.6%) during the pandemic, and a substantial increase to nine patients (64.3%) in the post-pandemic period. Treatment protocols for mastoiditis predominantly included antibiotic therapy, with additional surgical interventions such as mastoidectomy (three patients), local drainage (three patients), and ventilation tube placement (one patient). All patients diagnosed with

**Table 1.** Number of patients with complications of AOM across pre-pandemic, pandemic, and post-pandemic periods

Acute otitis media complications	Pre-pandemic (2014-2020)	Pandemic (2020-2022)	Post-pandemic (2023-2024)
Mastoiditis	1	4	9
Subperiosteal abscess	0	1	3
Facial nerve paralysis	0	0	4
Meningitis	2	1	2
Labyrinthitis	1	0	3
Sigmoid sinus thrombosis	0	0	1
<b>Total</b>	<b>4</b>	<b>6</b>	<b>22</b>

AOM: Acute otitis media



**Figure 1.** Numbers and trends of complicated AOM cases across pre-pandemic, pandemic, and post-pandemic periods  
AOM: Acute otitis media



mastoiditis recovered without any sequelae after medical and surgical treatments.

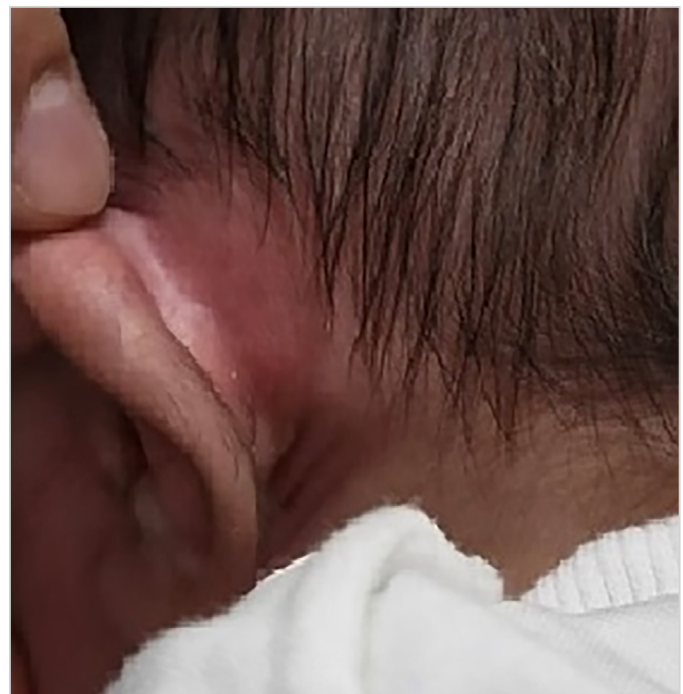Subperiosteal abscesses were identified in four patients (12.5%). These abscesses were distributed as follows: one patient (25%) in the pandemic and three patients (75%) in the post-pandemic period. Management encompassed both antibiotic therapy and surgical procedures, including local drainage (three patients) and mastoidectomy (one patient). The physical examination findings of a left-sided subperiosteal abscess in a 2-year-old girl are illustrated in Figure 3. Additionally, Figure 4 presents the CT scan of a 3-year-old patient with acute mastoiditis complicated by a subperiosteal abscess in the right ear (axial plane). All patients diagnosed with subperiosteal abscess recovered without any sequelae after treatments.

FNP was observed in four patients (12.5%), and all cases were detected in the post-pandemic period. Three patients had grade 3 FNP, and one patient had grade 4 FNP. Treatment strategies included antibiotic treatment, ventilation tube placement and steroid therapy. One patient, who also had mastoiditis, required a mastoidectomy. Of the FNP patients, three achieved complete recovery, while one experienced persistent grade 2 facial paralysis at 6-month follow-up.

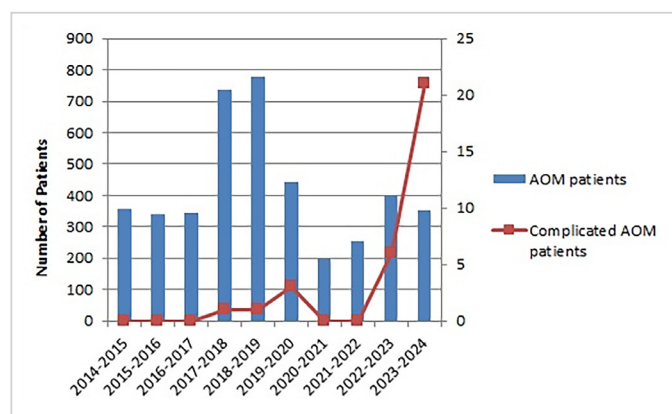
Meningitis was diagnosed in five patients (15.65%). The distribution of meningitis cases across the periods was two patients (40%) in the pre-pandemic period, one patient (20%) during the pandemic, and two patients (40%) in the post-pandemic period. All patients received antibiotic therapy, and one patient also underwent ventilation tube placement. Notably, the most recent addition was an 18-year-old male diagnosed with meningitis in the post-pandemic period, who was managed with antibiotic therapy. He was diagnosed with bilateral AOM and was started on oral antibiotic therapy. Even though early antibiotic treatment was initiated-one day after the diagnosis-the case progressed to clinical meningitis, and the disease was brought under control after

hospitalization and broad-spectrum antibiotic treatment. All patients diagnosed with meningitis recovered without any sequelae with treatments.

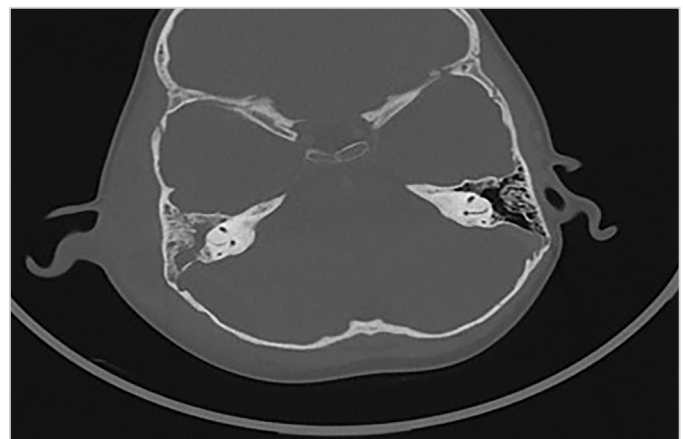
Labyrinthitis was observed in four patients (12.5%). The distribution of labyrinthitis cases was one patient (25%) in the pre-pandemic period and three patients (75%) in the post-pandemic period. All individuals who were affected developed sensorineural hearing loss. Treatment for labyrinthitis varied; two patients with concurrent mastoiditis underwent mastoidectomy in addition to medical treatment, while one patient received myringotomy and ventilation tube placement along with medical management. After



**Figure 3.** Physical examination showing left subperiosteal abscess in a 2-year-old girl



**Figure 2.** Annual distribution of total AOM and complicated AOM cases, illustrating the increase in complications post-pandemic AOM: Acute otitis media



**Figure 4.** CT scan of a 3-year-old patient with acute mastoiditis complicated by a subperiosteal abscess in the right ear (axial plane) CT: Computed tomography

completing the treatment of patients with labyrinthitis, the sensorineural hearing loss that occurred in the patients continued as moderate to severe in the control audiograms.

Sigmoid sinus thrombosis was noted in one patient (3.1%), identified during the post-pandemic period, and managed with both antibiotic therapy and ventilation tube placement. In the patient's long-term follow-up, no sequelae were observed.

## Discussion

Our study highlights a significant increase in the number of AOM-related complications during the pandemic and post-pandemic periods, although they define a shorter period of time. More severe complications such as mastoiditis, subperiosteal abscesses, FNP, and meningitis, were seen particularly in the post-pandemic period. These results reveal a potential impact of the pandemic on AOM cases and related complications. Previous studies in the literature have investigated the effects of COVID-19 on the development of otitis media and its association with an increased incidence of acute mastoiditis (8-10). However, unlike other studies, our study aimed to contribute to the literature by comprehensively evaluating the increase in other complications, alongside acute mastoiditis, associated with AOM, specifically in the post-pandemic period. Additionally, our study is the first on this topic conducted in Türkiye, and its findings serve as a valuable contribution to and support for studies conducted in the other regions worldwide.

AOM typically arises from the ascent of pathogens from the nasopharynx through the Eustachian tube, leading to inflammation and fluid accumulation in the middle ear. While most cases of AOM resolve spontaneously or with appropriate medical management, complications such as mastoiditis, subperiosteal abscess, labyrinthitis, FNP, and meningitis can occur. These cases necessitate prompt recognition and intervention to prevent serious sequelae. In general, with the introduction of antibiotics, the rate of complications after AOM had decreased significantly (11). Complications after AOM were limited to areas where access to antibiotics is difficult and in cases where antibiotics are not used properly. However, as our results have revealed this has changed with the COVID-19 pandemic.

The COVID-19 pandemic had a significant impact on respiratory infections overall. A greater incidence of complex upper respiratory tract infections may have resulted from the relaxation of COVID-19-related limitations (2). SARS-CoV-2 infection has been shown to induce prolonged changes in the immune system, including impaired T-cell response, dendritic cell depletion, and alterations in myeloid surface markers (4,12). These alterations are suggested to contribute to long-term immune dysfunction, which may increase susceptibility to infections such as AOM. Although

these alterations are not directly assessed in our study, they represent potential mechanisms that could contribute to the increased incidence of complicated AOM cases during the post-pandemic period. Apart from the immune dysregulation caused by the COVID-19 infection, several other factors may have contributed to the rise in complicated AOM cases. These include a weakened immune system due to reduced exposure to pathogens and slower immune maturation (12,15). Additionally, changes in pathogen virulence may also play a role. Furthermore, during the pandemic, access to well child visits was limited, potentially leading to disruptions in vaccination programs (15-17). These factors are believed to be the key reasons for the increase in complicated AOM cases, especially among pediatric populations, in the post-pandemic period.

Non-pharmaceutical interventions during the pandemic reduced the spread of respiratory pathogens, including AOM. However, the lifting of these restrictions led to a rebound effect, with a marked increase in AOM cases, likely due to sudden re-exposure to pathogens (13,14). According to Cohen et al. (15) extended periods of low microbial exposure raise the likelihood of subsequent epidemics because of the population's induced immunity debt and the number of vulnerable people. The idea of trained immunity refers to a long-term, pathogen-stimulated functional reprogramming of innate immune cells that would result in a reinforced response after sustained exposures. The host defense would greatly benefit from this procedure (16). Due to the pandemic's hygienic efforts, there were fewer infectious contacts, which may have weakened children's immune systems and increased their vulnerability to infections.

Before the pandemic, infant and young children vaccination coverage rates were acceptable in our country and many other countries owing to national vaccination programs. The COVID-19 pandemic affected vaccine coverage rates across the board, with some seeing a severe decline, especially during the lockdown periods, and a partial recovery after that (17). A significant decline in doctor visits, including well-baby visits, was noted during the initial lockdown that began in March 2020. Parker et al. (18) revealed that the most common causative agent of AOM changed over time and there was a significant improvement in the antibacterial sensitivity of antibiotics after the vaccination program. Global coverage of vaccines such as diphtheria-tetanus-pertussis 3, measles-containing vaccines (MCV1 and MCV2), and meningococcal groups A, C, W, and Y saw substantial decreases during the pandemic (19). These reductions left many children unprotected against severe complications from preventable diseases. Notably, pneumococcal conjugate vaccines and *Haemophilus influenzae* type b vaccinations, which are critical in preventing respiratory infections and AOM, were particularly impacted. Although our study did

not include individual patient-level vaccination data, recent studies have demonstrated that reductions in pneumococcal vaccination rates during the pandemic were associated with increased incidences of AOM and its complications (20). These findings indicate that maintaining high vaccination rates is critical for preventing otitis media and its related complications in pediatric populations. Therefore, while the observed surge in complicated AOM cases may align with disruptions in vaccination programs, further studies incorporating patient-specific vaccination records are required to confirm this association and understand its impact on disease severity.

Virulence, the degree to which a pathogen harms its host, is dynamic and context-dependent, making it challenging to predict its impact on host proliferation and population spread (21). Depending on this evolution in the virulence of the pathogen, the response of the host's immune system to the pathogen and the effectiveness of the antibiotics and other medical treatments change. Recent studies suggest that the increase in complicated AOM cases observed after the pandemic may be linked to the shifts in the subtypes of pathogens responsible for AOM, as well as the changes in host response and treatment efficacy, potentially driven by pathogen virulence dynamics (20). Shifts in the serotype distribution of *Streptococcus pneumoniae* and increased oxacillin resistance during the pandemic may have altered the microbiological profile of AOM (22). These findings indicate that the pandemic may have changed the pathogen subtypes of upper respiratory tract infections, potentially altering clinical outcomes and complication rates of AOM in the post-pandemic era. Although our study did not include microbiological evaluations to confirm these alterations, the observed rise in complicated AOM cases highlights the necessity for future research to explore these mechanisms in depth and to assess pathogen dynamics in the post-pandemic era.

Previous studies in the literature have investigated the effects of COVID-19 on the development of otitis media and its association with an increased incidence of acute mastoiditis (8,9). In this research, the results showed that there was an increase in complications during the post-pandemic period and this research gives you an idea that AOM cases, which are considered innocent, may become complicated due to changes in the immune system, disruptions in vaccination programs during the pandemic, and changes in the virulence of pathogens. Considering the increase in complications, especially in the post-pandemic period, it is important to treat AOM cases more effectively and seriously. Our study gives an idea about this increase and future research is necessary to elucidate the underlying reasons for this trend.

Our study has some limitations that should be acknowledged. First, the retrospective nature of the study and its reliance

on existing data may introduce selection bias, potentially affecting the validity of the results. Second, as the study was conducted at a single tertiary referral center, the findings may not be generalizable to other regions or healthcare settings. Third, the observed increase in complicated AOM cases may be linked to decreased vaccination rates during the pandemic, which could have altered pathogen distribution and antibiotic sensitivity. However, it is important to note that our study did not include microbiological evaluations, individual vaccination data, or detailed immunological assessments. Due to these limitations, while our proposed mechanisms are supported by existing literature, further validation through well-designed prospective studies is necessary. Additionally, to better evaluate the effect of COVID-19 on the development of complicated otitis media, it is essential to document the history of COVID-19 infection and vaccination status in future studies. Our study did not include definitive, objective data regarding the patients' retrospective vaccination status or whether they had contracted COVID-19. Including such data in future research would enhance the accuracy and generalizability of the findings.

Despite these limitations, our study provides valuable insights into the post-pandemic increase in complicated AOM cases, highlighting the importance of maintaining vigilant clinical practices and conducting more comprehensive studies to elucidate the underlying mechanisms.

## Conclusion

The significant rise in complicated AOM cases during the post-pandemic period highlights potential lasting impacts of the COVID-19 pandemic. Factors contributing to this increase may include the long-term immune dysregulation induced by SARS-CoV-2, shifts in pathogen virulence, and the interruption of routine vaccination programs. These findings suggest a need for continued research into the pathophysiology of complicated AOM and underscore the importance of comprehensive treatment strategies and vigilant public health measures to prevent severe outcomes. Addressing these challenges requires a collaborative effort from healthcare providers, public health officials, and researchers to improve patient care and outcomes in the post-pandemic era. Additionally, studies incorporating microbiological evaluations, presenting the COVID-19 infection and vaccination status of patients, and covering broader geographic and demographic samples are needed for a more comprehensive understanding of this phenomenon.

## Ethics

**Ethics Committee Approval:** This study was approved by the Non-Interventional Clinical Research Ethics Committee of Necmettin Erbakan University (approval no: 2024/4910 , date: 05.04.2024).



## Acknowledge

The authors acknowledge the assistance of a large language model (ChatGPT-4o, OpenAI) to refine the language, improve readability, and enhance the academic style of the manuscript following the completion of the initial draft. All modifications were carefully reviewed and validated by the authors to ensure scientific accuracy and adherence to ethical standards.

## Footnotes

### Authorship Contributions

Surgical and Medical Practices: M.K., F.C.E., M.A.E., H.A., Concept: M.K., H.A., Design: M.K., M.A.E., H.A., Data Collection and/or Processing: M.K., M.A.E., H.A., Analysis and/or Interpretation: F.C.E., H.A., Literature Search: M.K., F.C.E., Writing: M.A.E.

**Conflict of Interest:** The authors have no conflicts of interest to declare.

**Financial Disclosure:** The author(s) declare that no financial interests or relationships that could be perceived as influencing the research presented in this article.

### Main Points

- A significant increase in complicated acute otitis media (AOM) cases was observed in the post-pandemic period compared to pre-pandemic years, despite an overall reduction in AOM incidence during the pandemic.
- Mastoiditis, subperiosteal abscess, facial nerve paralysis, meningitis, and labyrinthitis became more prevalent in the post-pandemic era, especially among pediatric patients.
- The surge in complications may be associated with immune dysregulation caused by severe acute respiratory syndrome coronavirus 2, interrupted vaccination schedules, and increased pathogen virulence following the coronavirus disease 2019 pandemic.

## References

1. El Feghaly RE, Nedved A, Katz SE, Frost HM. New insights into the treatment of acute otitis media. *Expert Rev Anti Infect Ther*. 2023; 21: 523-34. [Crossref]
2. Galli J, Sheppard SC, Caversaccio M, Anschuetz L, Beckmann S. Impact of COVID-19 pandemic: increase in complicated upper respiratory tract infections requiring ENT surgery? *Eur Arch Otorhinolaryngol*. 2024; 281: 1581-6. [Crossref]
3. Jesus CR, Rosa AAS, Meneses ADS, Agostini AC, Merten FB, Ferrão SM, et al. Impact of social distancing in response to COVID-19 on hospitalizations for laryngitis, tracheitis, otitis media, and mastoiditis in children aged 0 to 9 years in Brazil. *J Bras Pneumol*. 2021; 47: e20210229. [Crossref]
4. Hopkins FR, Govender M, Svanberg C, Nordgren J, Waller H, Nilsson-Augustinsson Å, et al. Major alterations to monocyte and dendritic cell subsets lasting more than 6 months after hospitalization for COVID-19. *Front Immunol*. 2023; 13: 1082912. [Crossref]
5. Cunniff L, Alyanak E, Fix A, Novak M, Peterson M, Mevis K, et al. The impact of the COVID-19 pandemic on vaccination uptake in the United States and strategies to recover and improve vaccination rates: a review. *Hum Vaccin Immunother*. 2023; 19: 2246502. [Crossref]
6. Lieberthal AS, Carroll AE, Chonmaitree T, Ganiats TG, Hoberman A, Jackson MA, et al. The diagnosis and management of acute otitis media. *Pediatrics*. 2013; 131: e964-99. [Crossref]
7. Rosenfeld RM, Shin JJ, Schwartz SR, Coggins R, Gagnon L, Hackell JM, et al. Clinical practice guideline: otitis media with effusion (update). *Otolaryngol Head Neck Surg*. 2016; 154: S1-41. [Crossref]
8. Choi SY, Yon DK, Choi YS, Lee J, Park KH, Lee YJ, et al. The impact of the COVID-19 pandemic on otitis media. *Viruses*. 2022; 14: 2457. [Crossref]
9. Goldberg-Bockhorn E, Hurzlmeier C, Vahl JM, Stupp F, Janda A, von Baum H, et al. Increase in acute mastoiditis at the end of the COVID-19 pandemic. *Eur Arch Otorhinolaryngol*. 2024; 281: 4747-56. [Crossref]
10. Favoretto MH, Mitre EI, Vianna MF, Lazarini PR. The impact of COVID-19 pandemic on acute otitis media among the pediatric population. *Int J Pediatr Otorhinolaryngol*. 2022; 153: 111009. [Crossref]
11. Kucur C, Özbay İ, Topuz MF, Erdoğan O, Oghan F, Güvey A, et al. Complications of acute otitis media: a single center experience. *JCEI*. 2017; 8: 120-3. [Crossref]
12. Wei LL, Wang WJ, Chen DX, Xu B. Dysregulation of the immune response affects the outcome of critical COVID-19 patients. *J Med Virol*. 2020; 92: 2768-76. [Crossref]
13. Yu H, Gu D, Yu F, Li Q. Social distancing cut down the prevalence of acute otitis media in children. *Front Public Health*. 2023; 11: 1079263. [Crossref]
14. Belingeri M, Paladino ME, Piacenti S, Riva MA. Effects of COVID-19 lockdown on epidemic diseases of childhood. *J Med Virol*. 2021; 93: 153-4. [Crossref]
15. Cohen R, Ashman M, Taha MK, Varon E, Angoulvant F, Levy C, et al. Pediatric Infectious Disease Group (GPIP) position paper on the immune debt of the COVID-19 pandemic in childhood, how can we fill the immunity gap? *Infect Dis Now*. 2021; 51: 418-23. [Crossref]
16. Netea MG, Giamarellos-Bourboulis EJ, Domínguez-Andrés J, Curtis N, van Crevel R, van de Veerdonk FL, et al. Trained immunity: a tool for reducing susceptibility to and the severity of SARS-CoV-2 infection. *Cell*. 2020; 181: 969-77. [Crossref]
17. Santoli JM, Lindley MC, DeSilva MB, Kharbanda EO, Daley MF, Galloway L, et al. Effects of the COVID-19 pandemic on routine pediatric vaccine ordering and administration - United

- States, 2020. MMWR Morb Mortal Wkly Rep. 2020; 69: 591-3. [Crossreff]
18. Paker M, Pichkhadze E, Miron D, Shlizerman L, Mazzawi S, Shupak A. Two decades of otitis media in northern Israel: changing trends in the offending bacteria and antibiotic susceptibility. *Int J Pediatr Otorhinolaryngol.* 2022; 152: 110940. [Crossreff]
19. Hamson E, Forbes C, Wittkopf P, Pandey A, Mendes D, Kowalik J, et al. Impact of pandemics and disruptions to vaccination on infectious diseases epidemiology past and present. *Hum Vaccin Immunother.* 2023; 19: 2219577. [Crossreff]
20. Stavar-Matei L, Mihailov OM, Nechita A, Crestez AM, Tocu G. Impact of COVID-19 on pneumococcal acute otitis media, antibiotic resistance, and vaccination in children. *Infect Drug Resist.* 2024; 17: 5567-78. [Crossreff]
21. Diard M, Hardt WD. Evolution of bacterial virulence. *FEMS Microbiol Rev.* 2017; 41: 679-97.
22. Kaur R, Schulz S, Fuji N, Pichichero M. COVID-19 pandemic impact on respiratory infectious diseases in primary care practice in children. *Front Pediatr.* 2021; 9: 722483. [Crossreff]