



# Use of Flexible Bronchoscopy in Foreign Body Aspiration

## Original Investigation

● Gökçen Ünal<sup>1</sup>, ● Aslı İmran Yılmaz<sup>1</sup>, ● Tahir Tok<sup>2</sup>, ● Sevgi Pekcan<sup>1</sup>

<sup>1</sup>Department of Pediatric Pulmonology, Necmettin Erbakan University MERAM Faculty of Medicine, Konya, Turkey

<sup>2</sup>Department of Pediatrics, Necmettin Erbakan University MERAM Faculty of Medicine, Konya, Turkey

## Abstract

**Objective:** Foreign body aspiration remains a serious health problem with a potential for severe consequences, and acute and chronic problems in children. It therefore demands immediate intervention. Rigid bronchoscopy has long been the method of choice for foreign body removal but is now being replaced by flexible bronchoscopy which offers reduced trauma and the ability to access distal bronchial regions. In the presented study we assessed the patients who underwent flexible bronchoscopy for foreign body removal in our clinic.

**Methods:** We reviewed the records of 20 patients who underwent flexible bronchoscopy due to suspected foreign body aspiration and had a foreign body removed in our clinic. Patients were analyzed in terms of sociodemographic data, foreign bodies removed, method of foreign body removal, foreign body location and time to diagnosis.

**Results:** Our study group included nine females and 11 males. The removed foreign body was organic in 19 of the 20 patients and inorganic in one patient. Hard organic food, such as hazelnuts, peanuts, seeds, almonds, and raw corn kernel were identified in 12 patients, a piece of fishbone in one patient and a piece of gelatin in another. The pieces of soft organic food identified were apple in one patient, egg in one patient, and boiled corn kernel in one patient and removed by suction. The foreign body was removed using forceps in nine patients, and a basket was used successfully in seven patients.

**Conclusion:** Foreign bodies can be removed with minimal complication using flexible bronchoscopy, basket, and forceps in children.

**Keywords:** Foreign bodies, airway, child, bronchoscopy, forceps

### ORCID ID of the authors:

G.Ü. 0000-0002-4380-7643;  
A.İ.Y. 0000-0003-2689-7904;  
T.T. 0000-0003-3213-0312;  
S.P. 0000-0002-8059-902X.

**Cite this article as:** Ünal G, Yılmaz AI, Tok T, Pekcan S. Use of Flexible Bronchoscopy in Foreign Body Aspiration. Turk Arch Otorhinolaryngol 2022; 60(2): 88-94.

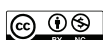### Corresponding Author:

Sevgi Pekcan;  
sevgipekcan@yahoo.com

**Received Date:** 15.06.2022

**Accepted Date:** 29.06.2022

Content of this journal is licensed under a Creative Commons Attribution 4.0 International License. Available online at [www.turkarchotolaryngol.net](http://www.turkarchotolaryngol.net)



DOI: 10.4274/tao.2022.2022-6-6

## Introduction

Flexible fiberoptic bronchoscopy (FB) was first used in pediatric patients in Germany in 1978, long after rigid bronchoscopy (RB) was used for foreign body removal in an adult patient in 1897. In general, bronchoscopy is helpful for

the visualization of the airway anatomy, the assessment of airway dynamics, the treatment of obstructions and the collection of fluid samples, and brushing/biopsy procedures for microbiology and histopathology. It is an invasive procedure that requires sedo-anesthesia in children, and can lead to such

complications as desaturation, airway trauma, laryngeal spasm, and bleeding (1).

Foreign body aspiration (FBA) remains a serious medical issue that can lead to severe consequences and cause acute and chronic problems in children and thus requires immediate intervention (2). It is the fourth leading cause of accidental death in children younger than three years of age and the third leading cause of death in children aged younger than one year (3). Impaired oxygenation and ventilation due to obstruction of the airway can lead to morbidity (4). The primary treatment approach is RB as it provides airway patency. RB has long been the method of choice for foreign body removal but is being replaced by FB which offers reduced levels of associated trauma and the ability to access distal bronchial regions. However, practice is limited in the literature, especially in children (5). In the presented study we assessed the patients who underwent FB for foreign body removal in our clinic.

## Methods

We retrospectively reviewed the records of 20 patients who presented to our clinic in 2016 to 2020 with a history, physical examination, clinical symptom or finding, or a chronic cough that raised the suspicion of FBA and underwent FB for foreign body removal.

Sociodemographic data, the type of the foreign body, method of foreign body removal, foreign body location, time to diagnosis, and chest X-ray findings were analyzed. Diagnostic and therapeutic bronchoscopy were performed using a flexible fiberoptic bronchoscope (BF-3C160, BF-H1100, Olympus, Japan) with an outer diameter of 3.8 mm and a thickness of 4.9 mm. The procedure was performed in the operating room with an anesthesiologist, a bronchoscopy nurse and two pediatric pulmonologists present. Given the possibility of failure with flexible bronchoscopy, our hospital's thoracic surgery department was informed prior to the procedure about a possible need for RB.

All patients gave their consent before bronchoscopy. The procedure was initiated by inserting a laryngeal mask airway (LMA) while the patient was under sedo-anesthesia. In patients whom a foreign body was identified, anesthesia was deepened, and the procedure was continued under general anesthesia.

Forceps and multi prong snare were used in the first attempt to remove the foreign body, and those that could not be grasped or removed using forceps and snare were removed using a blunt-end urological basket and N-Gage.

For removals using forceps, the forceps were first advanced through the suction cannula, the bronchoscope was pulled upwards slightly to make the tip of the forceps visible, and the foreign body was grasped and pulled upward together

with the bronchoscope. The same procedure was performed when using snare.

For removals using a basket, the basket was advanced through the suction cannula and the bronchoscope was withdrawn after it reached the level of the foreign body. Upon reaching at the edge of the foreign body, the basket was opened and rotated around its own axis to capture the foreign body in the basket. After capturing the foreign body, the basket was locked and pulled slowly upward to stabilize the foreign body. If the removal failed, the procedure was repeated in regard of the patient's oxygenation.

Following the removal procedure, a FB was performed again to ensure that no residue remained in the airways. After the procedure, the patients were followed up closely and observed for at least one day as inpatients.

Approval was given by the Ethics Committee of Necmettin Erbakan University (decision no: 2021/3231, date: 07.05.2021).

## Statistical Analysis

Statistical analysis was performed using SPSS (Statistical Package for Science Studies) version 22.0 for Windows. Variables with non-normal distribution were analyzed with a Mann-Whitney U test and a Kruskal-Wallis test. The results of the statistical analyses were expressed at a 95% confidence interval and  $p < 0.05$  was accepted as statistically significant.

## Results

Foreign bodies were removed using FB in 20 of our patients, of whom nine (45%) were female and 11 (55%) were male. Their mean age was 21.8 months, their median age was 20 months (minimum: 8, maximum: 44 months), and 13 patients were aged 12–18 months.

Regarding the time taken until diagnosis, the shortest duration was one day and the longest was six months. The mean duration of complaint was 32.5 days, and the median was 20.5 days.

The presenting complaint was cough in 18 (90%) patients, of whom 10 (50%) had a complaint of chronic cough (21 days–6 months). In addition, eight (40%) patients presented with wheezing, three (15%) with bruising, and one (5%) with fever in addition to cough and wheezing, while four (20%) had a history of antibiotic therapy after a diagnosis of pneumonia. Of the total, eight patients had undergone RB (twice in one patient) at another center due to FBA. In one patient, the foreign body was removed, but the complaint did not resolve. The patient who underwent RB twice could not be assessed for the presence of a foreign body due to edema of the airway. The duration of complaints of seven patients who previously had undergone RB ranged from

three weeks to three months, and the duration of admission to our department due to unresolved complaints following RB ranged from one month to two months. One of our patients had a one-day history.

Respiratory system examination of nine (45%) patients was normal. There were rales in two (10%) patients, rhonchi in three (15%) and decreased breath sounds on the side of the foreign body in six (30%) patients. Stridor was present in two (10%) patients, of whom one had hoarseness and dyspnea, and the other had a barking cough along with stridor.

Increased aeration was detected on the chest X-ray of 11 (55%) patients, pneumonic infiltrates were observed on the radiographs of three (15%) patients, and the chest X-ray was normal in nine (45%) patients.

During the procedure, sedo-anesthesia was administered to all of our patients, and LMAs sized 1.5–2.5 mm were selected based on the weight of the patient (6). The procedure was performed using a bronchoscope of 3.8 mm in 10 (50%) patients and 4.9 mm in 10 (50%) patients. The instruments used in our clinic are shown in Figure 1.

The removed foreign bodies were hard organic food such as hazelnuts, peanuts, seeds, almonds and raw corn kernel in 12 patients, pieces of fishbone in one patient and gelatin in one patient (Figure 2). The pieces of apple in one patient, egg in one patient and boiled corn kernel in one patient were removed by suction. Unidentifiable organic materials were removed from four of our patients (Table 1).

Initially, forceps and snare were used in all patients for removal. The foreign body was removed using forceps in nine patients, while a basket was used successfully in seven of the patients when foreign bodies could not be removed using forceps. One patient presented with two pieces of fish bones, of which one could be removed using forceps. The second, however, lodged under the epiglottis and could not be removed with the forceps and so it was removed using N-Gage. In one patient, two foreign bodies were removed from two different locations using forceps. Pieces of egg, apple, and boiled corn kernel were removed by suction in three of the patients. The locations of the foreign bodies are given in Table 2.

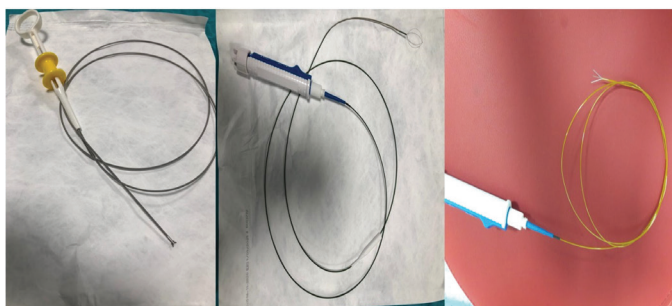


Figure 1. Tools used in our clinic (forceps, basket, snare)

None of the patients developed pneumothorax or hemorrhage. Edema of the airway developed in seven patients, while one patient who had a foreign body in the epiglottic tract developed laryngeal spasm, hypoxia, and edema during the removal procedure. In another patient, the foreign body was stuck in the vocal cords during the procedure, and hypoxia (SpO<sub>2</sub> decreased to 60% and was transient) and edema developed during removal with basket. None of the patients needed mechanical ventilation.

Of the total, five patients identified with granulation tissue and abundant secretion during the procedure were hospitalized for a week and placed on antibiotic therapy. The time of onset of complaint was ≥20 days in the patients with prolonged hospital stay. There was a statistically significant difference between the duration of complaints and the presence of granulation tissue, and between the length of hospital stay and the presence of granulation tissue ( $p < 0.004$  and  $p < 0.036$ ).

Table 1. Extracted foreign bodies and their numbers

Seed	4 (20%)
Hazelnut	2 (10%)
Almond	2 (10%)
Corn	2 (10%)
Egg mash	1 (5%)
Apple mash	1 (5%)
Peanut	1 (5%)
Chickpeas	1 (5%)
Fishbone	1 (5%)
Unidentified organic food	4 (20%)
Gelatin	1 (5%)

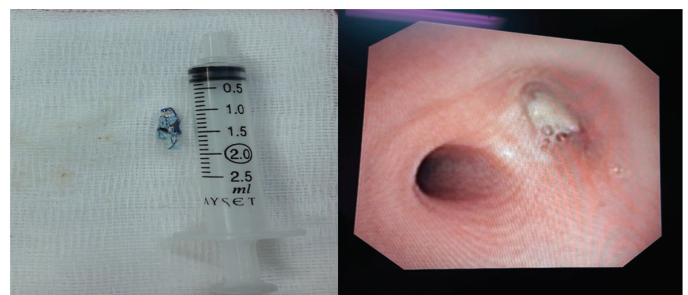

Figure 2. Foreign body specimens removed

Table 2. Anatomical localization of foreign bodies

Left main bronchus	6 (30%)
Left lower lobe	2 (10%)
Right main bronchus	5 (25%)
Right middle lobe	3 (15%)
Right upper lobe	1 (5%)
Trachea	1 (5%)
Epiglottis	2 (10%)

Growth in the cultured bronchoalveolar lavage sample collected during bronchoscopy was identified in 10 of the patients, namely *Klebsiella pneumoniae* in four patients, *Pseudomonas aeruginosa* in one patient, *Serratia marcescens* in one patient, *Moraxella catarrhalis* in one patient, *Enterobacteriaceae* spp. in two patients and coagulase-negative *Staphylococcus* in one patient. No such growth was identified in the remaining 10 patients (Table 3).

## Discussion

FBA is the leading cause for concern in the field of pulmonology and requires immediate intervention. Among the reasons for the prevalence of FBA in young children are the tendency to place various objects in the mouth, the absence of posterior teeth, frequent and strong breathing while laughing and crying, immature swallowing and chewing functions, and habits of moving while eating (4). The risk of FBA is especially important in patients with intellectual disabilities due to impaired swallowing function. FBA is more common in males, which may be due to their more irregular behavior (7). In the presented study, males accounted for 55% of the sample.

For diagnoses of FBA, a physical examination should be supported by imaging methods, the most appropriate being posteroanterior (PA) chest radiography due to its ability to reveal findings to support FBA, such as mediastinal shift, difference in aeration between the lungs, obstructive emphysema, pneumonia, and atelectasis when a PA chest X-ray is completely normal. Previous studies in literature have reported normal chest radiography at rates of 10% to 46% (4, 8, 9). In the presented study, chest X-ray was normal in 45% of the patients. Chest X-ray alone is not sensitive or specific enough for the diagnosis of foreign bodies. If the history and physical examination findings support aspiration, a diagnostic bronchoscopy is required even if the chest X-ray is normal.

If the patient has dyspnea, persistent cough, asymmetry in auscultation and a localized increase in aeration on PA chest X-ray, therapeutic bronchoscopy should be performed. As the foreign body usually progresses to the bronchioles, the patient is clinically stable, and in such cases a recommended fasting period and appropriate equipment can be expected to remove the foreign body. However, if the patient develops severe respiratory failure, mediastinal shift, massive atelectasis,

**Table 3.** Demographic and clinical data of patients

Patient	Age (month)	Sex	Body weight (kg)	Bronchoscope outer diameter (mm)	Tool	Complication	Hospitalization (day/s)	Culture results
1	13	Male	12	3.8	Forceps	None	3	<i>Klebsiella, E.coli</i>
2	22	Male	14	3.8	Forceps	Edema	3	<i>Strep. salivarius</i>
3	22	Male	12.3	3.8	Forceps	None	4	<i>Strep. salivarius</i>
4	21	Male	10	3.8	Forceps	Edema	7	<i>Pseud. aeruginosa</i>
5	21	Female	11	3.8	Forceps	Nona	7	<i>Strep. salivarius</i>
6	19	Female	8.5	3.8	Forceps	None	7	<i>Streptococcus</i>
7	35	Female	12	3.8	Forceps	Edema	5	<i>Strep. mitis/Strep. oralis</i>
8	17	Female	9	3.8	Basket	Edema	8	<i>Klebsiella pneumoniae</i>
9	8	Female	8	3.8	Aspiration	None	1	<i>Moraxella catarrhalis</i>
10	25	Male	13	4.9	Basket	None	7	CNS
11	16	Male	10	4.9	Forceps	None	3	<i>Klebsiella</i>
12	42	Female	19	4.9	Forceps	None	0	<i>Enterobacter</i>
13	18	Male	15	4.9	Aspiration	Spasm, hypoxia, edema	1	Respiratory flora bacteria
14	17	Male	12	4.9	Basket	None	1	Respiratory flora bacteria
15	18	Male	8	3.8	Basket	None	3	<i>Serratia marcescens</i>
16	16	Female	9.8	4.9	Basket	None	1	Respiratory flora bacteria
17	44	Female	14	4.9	Aspiration	None	2	Respiratory flora bacteria
18	24	Male	11	4.9	Basket	None	3	<i>Klebsiella</i> spp.
19	18	Male	12	4.9	Basket	Edema	2	<i>Enterobacter</i>
20	21	Female	10	4.9	N-Gage	Spasm, hypoxia, edema	4	Respiratory flora bacteria

CNS: Coagulase-negative *Staphylococcus*, *E.coli*: *Escherichia coli*, *Strep. salivarius*: *Streptococcus salivarius*, *Pseud. aeruginosa*: *Pseudomonas aeruginosa*



or pneumothorax, or if there is a suspected foreign body such as a battery that can cause tissue necrosis, removal should be performed immediately.

Such procedures should be performed using FB if there are fewer specific symptoms of FBA, if the PA chest X-ray is normal, or if the patient has chronic or recurrent radiological abnormalities. RB is the standard treatment approach in FBA and is still used in many centers.

RB is mandatory when the foreign body is located in areas such as the larynx, subglottic region or trachea that may cause asphyxia, and when the foreign body has an irregular surface. In such cases, RB allows for good airway management and the use of more appropriate instruments for the removal of the object.

That said, peripheral bronchioles are difficult to reach using RB, and sometimes the field of view may be limited, and so there has been an increasing number of recent studies supporting the use of FB for foreign body removal (10). It should be noted, however, that the use of FB for foreign body removal in children younger than two years of age has been associated with several challenges, including the narrowness of the tracheal and bronchial areas, and the development of asphyxia and respiratory failure due to central airway stenosis caused by the use of an inappropriate bronchoscope. Although thin bronchoscopes can be selected for such cases, the procedure may fail due to the use of forceps that are less flexible and difficult to use. Tamate et al. (11) described a procedure in which a Fogarty balloon catheter was placed on the outer wall of the bronchoscope but concluded that the procedure was difficult. In our center, RB is still performed by the thoracic surgery department in patients who present with suspected FBA. The series in the presented study consisted of children in whom either a foreign body was detected by FB upon chronic cough, or no foreign body was detected by a previously performed RB, or who had chronic cough of which the etiology was being investigated or had unresolved pneumonia and wheezing.

In our experience, foreign bodies can be removed using flexible bronchoscopy more comfortably by experienced hands and with the appropriate equipment, although the removal of FBs using flexible bronchoscopy is still performed in very few centers and especially in pediatric cases.

Furthermore, foreign bodies, especially those in a peripheral location, may not be seen with RB, as was the case in eight of our patients, and the child's complaints may not be resolved despite RB.

After assessing this case series, our routine practice plan was to use flexible bronchoscopy to remove foreign bodies in the more distal bronchioles. In cases in which flexible bronchoscopy failed, we planned for RB to be performed by the thoracic surgery department.

In their adult study, based on the lack of any procedure-related complications in patients in whom foreign bodies were removed using FB, Sancho-Chust et al. (12) concluded that FB were more reliable than RB. The same study reported that procedures were successfully resolved using traditional biopsy forceps. The devices which are reported in the literature to be used to remove foreign bodies include standard biopsy forceps, forceps designed for the removal of foreign bodies (crocodile/alligator forceps), magnetic forceps (for metal objects), and various metal hooks, baskets, balloon catheters and cryoprobes (12).

There is always a risk of object displacement and backward movement when removing a foreign body, and factors such as size, shape irregularity, hardness, and consistency of the foreign body can affect this risk. If a basket is used to prevent backward movement, it is necessary to try to completely surround the foreign body. If forceps are used, it is necessary to grasp the object effectively and apply pressure. Foreign bodies are often lodged in the glottis as it is the narrowest part of the airway. If the bronchoscope is inserted nasally, the nasal fossae should be considered for stenosis (12). In the presented study, the procedure could not be completed in single attempt in some patients. When the object fell from the forceps or basket, the procedure was repeated from the point at which the foreign body fell. When foreign bodies remain in the airway for more than seven days (especially in dried fruit aspirations), edema and inflammation are more common and so procedure-related morbidity may increase and treatment may be challenging. A foreign body located in granulation tissue may restrict the field of view during bronchoscopy, and the mucosa may bleed easily. In such cases it is recommended that systemic steroids and antibiotics be administered for a few days before a second removal procedure, as this may facilitate the removal of the foreign body (13, 14).

The study by Varshney et al. (15) involving children reported that the foreign bodies were easily removed without damage to the tracheobronchial mucosa using flexible bronchoscopy in cases with severe laryngeal edema due to repeated RB, and that a postprocedural check was performed to be sure of the absence of residual foreign body. The patients in the presented study were also subjected to a control bronchoscopy to check the patency of the entire airway after the removal of the foreign body.

In all of the studies related to this issue, general anesthesia was administered to the patients. The most important factor in anesthesia management is the prevention of hypoxemia while removing the foreign body. In children, the inner diameter of the trachea is less than one cm, even at five years of age, while at the age of one year it is less than five mm (16). Matsushima et al. (17) suggested that bronchoscopy without intubation may be more advantageous due to the further narrowing of

the airway lumen and the increased pressure on the airway during procedures requiring intratracheal intubation. The authors also commented on the use of a laryngeal mask as a more appropriate approach to airway management in an increasing number of studies. In the present study, anesthesia was administered via a laryngeal mask in all patients, and high-frequency jet ventilation (HFJV) was reported to be effective in maintaining oxygenation during the insertion of the bronchoscope. In the presented study, none of the patients needed HFJV.

FB is a method that can be preferred when the foreign body advances to the distal bronchioles, and when it becomes necessary to reach the upper lobules. The consistency, the size and the shape of the foreign body should always be evaluated to prevent fragmentation or sticking in the laryngeal region during removal. If FB fails, there should be an option to continue with RB.

## Conclusion

Foreign body removal using flexible bronchoscopy is not a commonly used approach in children, and although RB is still the general practice in many centers, FB seems to be a more comfortable and less invasive procedure for children as the airway can be assessed better by FB if oxygenation can be provided. We believe that this practice will become more common in pediatric pulmonology clinics in the years to come.

In the presented study we also observed a decline in the difficulties encountered with our first patients after hand skills were improved by appropriate training in our clinic. In our experience, foreign body removal using flexible bronchoscopy can be considered an alternative to RB in skilled hands due to its minimal complication risk and its reduced invasiveness and will be used more as the practitioners gain experience.

**Ethics Committee Approval:** Approval was given by the Ethics Committee of Necmettin Erbakan University (decision no: 2021/3231, date: 07.05.2021).

**Informed Consent:** Parents of the patients gave consent.

**Peer-review:** Internally peer-reviewed.

## Authorship Contributions

Concept: G.Ü., S.P., Design: G.Ü., S.P., Data Collection and/or Processing: A.İ.Y., T.T., Analysis and/or Interpretation: G.Ü., Literature Search: G.Ü., A.İ.Y., T.T., Writing: G.Ü., S.P.

**Conflict of Interest:** The authors have no conflicts of interest to declare.

**Financial Disclosure:** The authors declared that this study has received no financial support.

## Main Points

- Foreign body aspiration is the leading cause for concern in the field of pulmonology and requires immediate intervention.
- Flexible bronchoscopy is a method that can be preferred when the foreign body advances to the distal bronchioles, and when it becomes necessary to reach the upper lobules. If the flexible bronchoscopy fails, there should be an option to continue with rigid bronchoscopy.
- Foreign body removal using flexible bronchoscopy can be considered an alternative to rigid bronchoscopy in skilled hands due to its minimal complication risk and its reduced invasiveness and will be used more as the practitioners gain experience.

## References

1. Terkawi RS, Altirkawi KA, Terkawi AS, Mukhtar G, Al-Shamrani A. Flexible bronchoscopy in children: utility and complications. *Int J Pediatr Adolesc Med* 2016; 3: 18-27. [Crossref]
2. Brkic F, Umihanic S, Altumbabic H, Ramas A, Salkic A, Umihanic S, et al. Death as a consequence of foreign body aspiration in children. *Med Arch* 2018; 72: 220-3. [Crossref]
3. Na'ara S, Vainer I, Amit M, Gordin A. Foreign body aspiration in infants and older children: a comparative study. *Ear Nose Throat J* 2020; 99: 47-51. [Crossref]
4. Ding G, Wu B, Vinturache A, Cai C, Lu M, Gu H. Tracheobronchial foreign body aspiration in children: a retrospective single-center cross-sectional study. *Medicine (Baltimore)* 2020; 99: e20480. [Crossref]
5. Kim K, Lee HJ, Yang EA, Kim HS, Chun YH, Yoon JS, et al. Foreign body removal by flexible bronchoscopy using retrieval basket in children. *Ann Thorac Med* 2018; 13: 82-5. [Crossref]
6. Sanders JE, Spina LA. Supraglottic airway devices for pediatric airway management in the emergency department. *Pediatr Emerg Med Pract* 2020; 17: 1-20. [Crossref]
7. Righini CA, Morel N, Karkas A, Reyt E, Ferretti K, Pin I, et al. What is the diagnostic value of flexible bronchoscopy in the initial investigation of children with suspected foreign body aspiration? *Int J Pediatr Otorhinolaryngol* 2007; 71: 1383-90. [Crossref]
8. Haddadi S, Marzban S, Nemati S, Ranjbar Kiakelayeh S, Parvizi A, Heidarzadeh A. Tracheobronchial foreign-bodies in children; a 7 year retrospective study. *Iran J Otorhinolaryngol* 2015; 27: 377-85. [Crossref]
9. Mansour B, Elias N. Foreign body aspiration in children with focus on the role of flexible bronchoscopy: a 5 year experience. *Isr Med Assoc J* 2015; 17: 599-603. [Crossref]
10. Swanson KL, Prakash UB, Midthun DE, Edell Es, Utz JP, McDougall JC, et al. Flexible bronchoscopic management of

- airway foreign bodies in children. *Chest* 2002; 121: 1695-700. [Crossref]
11. Tamate S, Takeuchi S, Nakahira M, Kadowaki H, Nagata N. Removal of the tracheobronchial foreign body using the bronchofiberscope and Fogarty balloon catheter. *J Jap Sci Ped Surg* 1991; 27: 132-5. [Crossref]
  12. Sancho-Chust JN, Molina V, Vañes S, Pulido AM, Maestre L, Chiner E. Utility of flexible bronchoscopy for airway foreign bodies removal in adults. *J Clin Med* 2020; 9: 1409. [Crossref]
  13. Pagán Rivera BL, Anselmi FJ, Torres Mdel M, Segarra A, Rivera JR. Usefulness of Glucocorticoids in the management of foreign body aspiration. *Bol Asoc Med P R* 2015; 107: 24-7. [Crossref]
  14. Zhong B, Sun SL, Du JT, Deng D, Liu F, Liu YF, et al. Risk factors for lower respiratory tract infection in children with tracheobronchial foreign body aspiration. *Medicine (Baltimore)* 2019; 98: e14655. [Crossref]
  15. Varshney R, Zawawi F, Shapiro A, Lacroix Y. Use of an endoscopic urology basket to remove bronchial foreign body in the pediatric population. *Int J Pediatr Otorhinolaryngol* 2014; 78: 687-9. [Crossref]
  16. Endoh M, Oizumi H, Kanauchi N, Kato H, Ota H, Suzuki J, et al. Removal of foreign bodies from the respiratory tract of young children: treatment outcomes using newly developed foreign-body grasping forceps. *J Pediatr Surg* 2016; 51: 1375-9. [Crossref]
  17. Matsushima Y, Taira O, Amemiya R, Ono M, Miura H, Kinoshita M, et al. Pediatric flexible fiberoptic bronchoscopy without intubation. *J Jap Soc Respir Endosc* 1990; 12: 659-63. [Crossref]