



Surgical Implications of Superior Thyroid Cornu Agensis in Laryngeal Malignancy

Case Report

✉ Keshav Kumar Gupta¹, ✉ Zahir Mughal², ✉ Ijaz Ahmad¹

¹Department of Otorhinolaryngology, University Hospitals Birmingham NHS Trust, Heartlands Hospital, Birmingham, England

²Department of Otorhinolaryngology, University Hospitals Birmingham NHS Trust, Queen Elizabeth Hospital, Birmingham, England

Abstract

The most commonly reported superior thyroid cornu (STC) anatomical variation is in STC syndrome, where the cornu is enlarged or medially displaced. STC agensis is a rare laryngeal variation that can be unilateral or bilateral. Previous studies have reported STC agensis in cadaveric or forensic studies in patients with an otherwise normal larynx. We report a case of unilateral STC agensis in the context of a stage III glottic laryngeal squamous cell carcinoma. The variation was discovered intra-operatively during a total laryngectomy and was clinically unknown beforehand. There were no clinical or histological signs of bony erosion by the tumor. To our knowledge, this is the first report of unilateral STC agensis in a patient with laryngeal malignancy. This article draws attention to a rare anatomical variant of the larynx and highlights the surgical implications including potential diagnostic challenges and operative considerations.

Keywords: Thyroid cartilage, anatomical variation, agensis, larynx, laryngectomy, laryngeal malignancy

ORCID ID of the authors:

K.K.G. 0000-0001-8155-0001;
Z.M. 0000-0002-2103-4846.

Cite this article as: Gupta KK, Mughal Z, Ahmad I. Surgical Implications of Superior Thyroid Cornu Agensis in Laryngeal Malignancy. Turk Arch Otorhinolaryngol 2022; 60(3): 170-2.

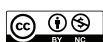Corresponding Author:

Keshav Kumar Gupta;
keshav.gupta@nhs.net

Received Date: 05.07.2022

Accepted Date: 18.08.2022

Content of this journal is licensed under a Creative Commons Attribution 4.0 International License. Available online at www.turkarchotolaryngol.net



DOI: 10.4274/tao.2022.2022-6-16

Introduction

The larynx is an important structure in the neck that has functions in airway protection, swallowing and phonation. It is suspended from the hyoid bone and comprises an intricate relationship of various cartilages, ligaments, and membranes. The largest cartilage is the thyroid cartilage which is made up of two quadrilateral laminae of hyaline cartilage. Posteriorly, the thyroid laminae

project superiorly and inferiorly to form the superior and inferior thyroid cornua, respectively. The superior thyroid cornu (STC) are joined to the hyoid via the lateral thyrohyoid ligament.

The most commonly reported STC anatomical variation is in STC syndrome, where the cornu is enlarged or medially displaced. This can be asymptomatic or present with dysphagia, odynophagia, and throat pain (1). Posterior deviation is less

commonly reported and has the potential to cause unilateral neck pain radiating to the ear, and even compression of the common carotid artery (2). Other reported variations include shortening, asymmetry, and agenesis (unilateral or bilateral) of the STC, although clinical implications of these in terms of patient symptoms are less well established (3, 4). We present a case and the discussion of superior cornu agenesis in the context of laryngeal malignancy.

Case Presentation

A 74-year-old independent and self-caring male had been known to the otolaryngology (ENT) department for dysphonia. This had previously been investigated and considered to be non-specific, but he remained under follow-up due to a strong smoking and alcohol history. His past medical history included T1bN0M0 squamous cell carcinoma (SCC) of the right lung, bladder carcinoma, type 2 diabetes mellitus, hypercholesterolaemia, ischemic heart disease, and transient ischemic attack. He had no history of neck or laryngeal trauma.

In December 2021, endoscopic examination of his larynx revealed a bulky glottic mass involving the anterior commissure. Magnetic resonance imaging of the neck with gadolinium enhancement and computed tomography of the neck and the thorax showed swollen vocal cords with no signs of lymphadenopathy. There were no signs of metastases. The vocal cord lesion was debulked and biopsied under general anesthesia. Histological analysis confirmed the diagnosis of moderately differentiated SCC. The tumor was staged as T3N0M0. The case was discussed at the head and neck multi-disciplinary team (MDT) meeting, and a decision was made to investigate further with a positron emission tomography (PET) scan given his previous lung carcinoma. PET imaging confirmed the absence of nodal involvement, metastases, or changes in the lungs.

He underwent a total laryngectomy en bloc with a right hemithyroidectomy (due to tumor extension to the subglottis with a subsequent high probability of micrometastases to the hemithyroid), and bilateral selective neck dissections (levels II-IV) in February 2022 as per MDT recommendations and discussion with the patient. The procedure was uncomplicated. Intra-operatively, the right STC was not palpable and appeared to be missing. Following completion of the total laryngectomy, the specimen was examined and demonstrated agenesis of the right STC (Figure 1). This was not identified by the reporting radiologists or at the MDT on any previous imaging. The imaging was re-reviewed following surgery and did show absence of the right STC (Figure 2). Intraoperatively, there was no evidence of tumor-related erosion of the cartilage adjacent to the absent STC, or structural variation of any other part of the laryngeal framework apart from the identified endolaryngeal tumor.

Histology confirmed an exo-endophytic, transglottic, invasive, moderate/poorly differentiated SCC, fungating through the anterior half of the right vocal cord and into right vocalis musculature (pT3 pN0 pR0). Local excision was confirmed to be complete with clear margins. There was no histological evidence of tumor invasion to other areas of the laryngeal framework including the areas near the site of STC agenesis, or the contralateral STC. There were no immediate postoperative complications. A water-soluble fluoroscopic swallow assessment on the tenth postoperative day confirmed no leak. The patient had an unremarkable postoperative recovery and continued to have laryngectomy training until he was discharged from hospital three weeks later with no planned adjuvant therapy. He remained well at six months follow-up with no signs of recurrence.

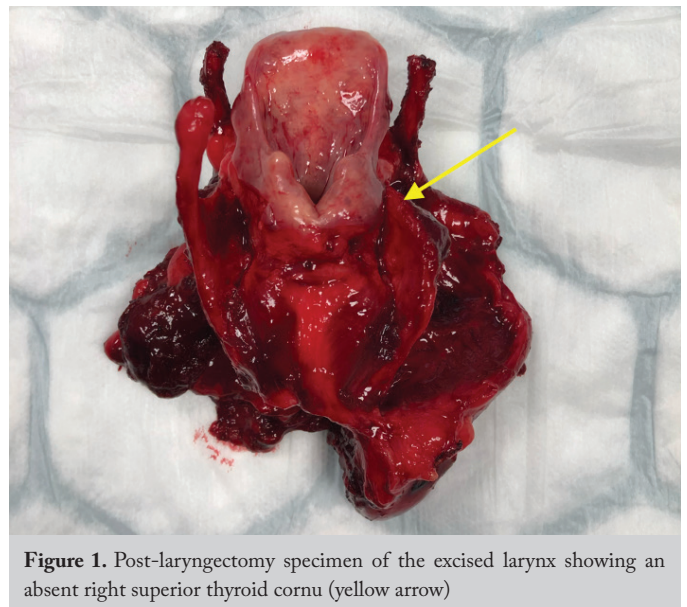


Figure 1. Post-laryngectomy specimen of the excised larynx showing an absent right superior thyroid cornu (yellow arrow)

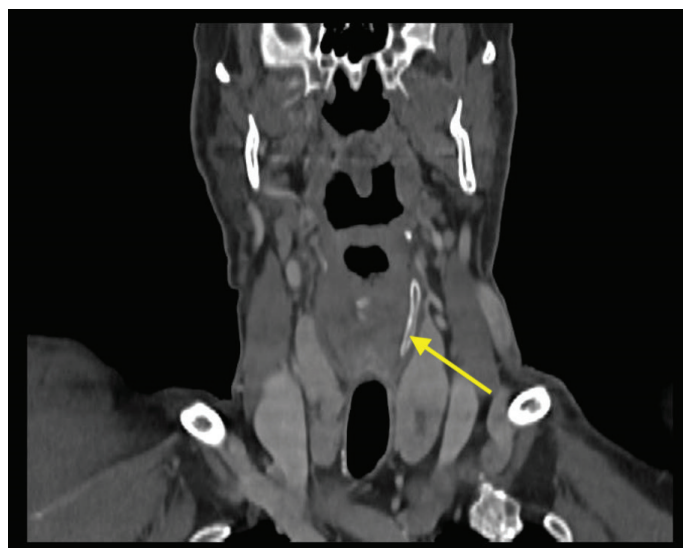

Figure 2. Computed tomography image in the coronal plane showing absence of the right superior thyroid cornu. The yellow arrow shows the left superior thyroid cornu for comparison

Discussion

STC agenesis is a rare laryngeal variation that can be unilateral or bilateral. In cases of unilateral agenesis, absence of the right STC has been reported to be rarer than of the left (3). To our knowledge, this is the first report of unilateral STC agenesis in a patient with laryngeal malignancy. Previous studies have reported STC agenesis in cadaveric or forensic studies in patients with an otherwise normal larynx, with most anatomical variations occurring in males as seen in our case (3, 4). It is unlikely that this varied anatomy causes any functional consequence of the larynx. There is otherwise usually no symptomatology that warrants further investigation in such findings. In addition, a morphometric study analyzing 49 larynxes found no structural imbalance or any difference in fracture risk between normal larynxes and those with STC unilateral agenesis (4). The relevance of abnormalities in the laryngeal framework or hyoid generally bodes significance in the forensic or medicolegal context of laryngeal trauma (accidents, violence, suicide, or iatrogenic). It is important for pathologists to be aware of STC agenesis so that it is not mistaken for laryngeal trauma during post-mortem.

In our case, there is clinical significance for several reasons. Firstly, the laterality of agenesis (right) was congruent with the tumor site. It is therefore possible that the staging of our tumor could have been falsely upgraded from T3 to T4 had this agenesis been noted on imaging prior to the laryngectomy, as it may have been interpreted that there was tumor invasion and erosion of the external surface of the thyroid cartilage. While it is unlikely that this could occur without radiological involvement of the thyroid cartilage and perichondrium, it is possible that such imaging may have caused confusion amongst MDT members in terms of imaging interpretation. This could have altered the patient's clinical course with potential adverse effects on patient care. There may also have been an increased psychological patient burden with a falsely high tumor stage. Therefore, awareness of such anatomical variance in the context of laryngeal malignancy is important for members of the head and neck MDT to recognize to help guide management options.

Secondly, variation in laryngeal anatomy is useful for surgeons to be aware of as this can alter the surgical process in already complex neck procedures such as laryngectomy, laryngopharyngectomy, and even neck explorations in trauma contexts. STC agenesis is particularly relevant to the pharyngeal reconstruction following laryngectomy. The altered anatomy of the laryngeal framework may have an impact on the amount of piriform fossae mucosa available for direct pharyngeal closure. Prior knowledge of this anatomical variant may therefore preempt the surgeon to consider and plan for a free flap reconstruction.

Conclusion

Knowledge of this case adds to the repertoire of data surrounding variable laryngeal anatomy which has its benefits in forensic and medicolegal contexts. The findings in this case may provide new insights into laryngeal anomalies in the context of surgical pathology. Our case expands on the preexisting literature on STC variations beyond the focus of trauma. Further research may be required in order to delve deeper into the potential patient impact of STC variations and agenesis.

Informed Consent: Written informed consent for publication of their clinical details and/or clinical images was obtained from the patient.

Peer-review: Externally and internally peer-reviewed.

Authorship Contributions

Surgical and Medical Practices: K.K.G., Z.M., I.A., Concept: K.K.G., Z.M., I.A., Design: K.K.G., Analysis and/ or Interpretation: K.K.G., Writing: K.K.G., Z.M., I.A.

Conflict of Interest: The authors declare that they have no conflict of interest.

Financial Disclosure: The authors declared that this study has received no financial support.

Main Points

- STC agenesis is a rare anatomical variant that usually has a focus in trauma, medicolegal and forensic cases.
- The findings in this case provide new insights into laryngeal variants in the context of surgical pathology.
- It is important to be aware of laryngeal variations in the context of malignancy to avoid falsely upgrading staging and for intra-operative considerations.
- Further research may be required in order to delve deeper into the potential patient impact of STC variations and agenesis.

References

1. Mortensen M, Ivey CM, Iida M, Woo P. Superior thyroid cornu syndrome: an unusual cause of cervical dysphagia. *Ann Otol Rhinol Laryngol* 2009; 118: 833-8. [Crossref]
2. Counter RT. A superior thyroid cornu anomaly: a report of a case. *J Laryngol Otol* 1980; 94: 1087-8. [Crossref]
3. Hejna P, Janík M, Urbanová P. Agenesis of the superior cornua of the thyroid cartilage: a rare variant of medicolegal importance. *Am J Forensic Med Pathol* 2015; 36: 10-2. [Crossref]
4. Winzek CF, Hartrampf LCM, Kampschulte M, Pons-Kühnemann J, Birngruber CG, Dettmeyer R, et al. Unilateral and bilateral agenesis of the upper thyroid horns - A morphometric analysis of the larynx. *Forensic Sci Int* 2019; 301: 225-30. [Crossref]