



Paranasal Sinus Fungus Ball, Anatomical Variations and Dental Pathologies: Is There Any Relation?

Original Investigation

Bayram Şahin, Şenol Çomoğlu, Said Sönmez, Kemal Değer, Meryem Nesil Keleş Türel

Department of Otorhinolaryngology & Head and Neck Surgery, İstanbul University İstanbul Faculty of Medicine, İstanbul, Turkey

Abstract

This study was presented at the 13th Turkish Rhinology Congress, 5th National Neurootology Congress, May 4, 2017, Antalya, Turkey.

ORCID ID of the authors:

B.Ş. 0000-0002-3886-4432;
Ş.Ç. 0000-0003-4632-9218;
S.S. 0000-0003-1982-0386;
K.D. 0000-0001-5883-871X;
M.N.K.T. 0000-0003-1829-8186.

Cite this article as: Şahin B, Çomoğlu Ş, Sönmez S, Değer K, Keleş Türel MN. Paranasal Sinus Fungus Ball, Anatomical Variations and Dental Pathologies: Is There Any Relation? Turk Arch Otorhinolaryngol 2022; 60(1): 23-8.

Corresponding Author:

Said Sönmez; dr.saidsonmez@gmail.com

Received Date: 10.11.2021

Accepted Date: 20.02.2022

Content of this journal is licensed under a Creative Commons Attribution 4.0 International License. Available online at www.turkarchotolaryngol.net



DOI: 10.4274/tao.2022.2021-11-8

Objective: The purpose of this study was to investigate the relationship between anatomical variations and the fungus ball (FB), and the association between odontogenic etiologies and the maxillary sinus FB.

Methods: We analyzed the clinical records of 66 patients who underwent endoscopic sinus surgery for FB. The anatomical variations determined were nasal septal deviation (NSD) and direction, presence of Onodi and Haller cell, concha bullosa and lateral recess of the sphenoid sinus. Further, dental X-ray records were reviewed to detect any possible odontogenic etiologies in patients with maxillary sinus FBs.

Results: There were 41 female and 25 male patients. Positive fungal culture was found in 60 patients (91%) and the causative fungus was *Aspergillus* species in all cases. The correlation between NSD and localization of the maxillary sinus FB was statistically significant ($p=0.0409$). Maxillary sinus FB was more common on the concave side of the NSD. Presence of dental pathologies was significantly associated with maxillary sinus FB compared to the healthy side ($p=0.0011$). For sphenoid sinus FB, NSD was detected in a similar number for both the affected and unaffected side and there were no significant correlations ($p>0.05$). However, the relationship between sphenoid sinus FB and presence of lateral recess was significant ($p=0.0262$).

Conclusion: Our study revealed that the maxillary sinus FB was more common on the concave side of the deviated septum. Also, dental pathologies or a presence of dental treatment history were associated with maxillary sinus FB.

Keywords: Fungus ball, endoscopic sinus surgery, dental pathology, lateral recess, paranasal sinuses, nasal septum

Introduction

Fungus balls (FBs) are chronic non-invasive accumulations of fungal elements in the sinus cavity of healthy subjects. They usually affect a single sinus and are most commonly caused by *Aspergillus* species (1, 2). FBs are frequently localized within the maxillary sinus, followed by the sphenoid sinus. Clinical presentation of FBs are not specific, and patients may complain of various rhinological symptoms. FBs can thereby lead to a diagnostic dilemma for clinicians and most cases are incidentally discovered by computerized tomography (CT) and/or magnetic resonance imaging (MRI) (3).

The pathophysiological mechanism underlying FB is not completely understood. Stammberger (4) hypothesized that nourishment of the fungus by purulent secretions from bacterial and viral superinfections initiated the pathogenesis of fungal sinusitis, followed by the growth of fungal hyphae in a low-pH environment provided by the stenosis of the ostiomeatal complex. Eloy et al. (5) proposed that sinus hypoventilation due to ostial stenosis played a significant role both in the accumulation of fungal spores and in providing anaerobic conditions for the growth of FB. On the other hand, Tsai et al. (6) argued against this hypothesis. They examined Lund-McKay scores in CT images and indicated that ostiomeatal complex dysfunction was not clearly verifiable in the appearance of FBs.

In the presented study, we aimed to investigate the possible relationships between the occurrence of FBs and the presence of different anatomical variations, and the association between odontogenic etiologies and maxillary sinus FBs.

Methods

We retrospectively reviewed the clinical records of patients affected by paranasal sinus (PNS) FB who underwent surgery at a tertiary reference center between 2008 and 2018. The definitive diagnosis was based on histopathological evaluation and/or fungal culture of the surgical specimens. Patients with chronic rhinosinusitis, invasive fungal sinusitis, or allergic fungal sinusitis or who had undergone any previous sinonasal surgery were excluded. Immunocompromised patients were also excluded. The Ethics Committee of Istanbul University İstanbul Faculty of Medicine reviewed and approved the study (project no: 1174/2019).

Preoperative endoscopic examination records, CT and MRI scans of all patients were retrieved from the medical records and reviewed retrospectively. In our clinical practice, patients with maxillary sinus FBs are evaluated with dental X-ray in term of possible odontogenic etiologies such as endodontic treatment history, periodontal disease, tooth extraction, dental implant presence, and communication between tooth apex and maxillary sinus. Therefore, dental X-rays of the patients with maxillary sinus FB were also reviewed. Accordingly,

patients with dental pathology and related complaints were consulted to the oral and maxillofacial surgery department.

The anatomical variations determined were nasal septal deviation (NSD) and direction, presence of Onodi and Haller cell, concha bullosa and lateral recess of the sphenoid sinus. NSD of 10 degrees or more was accepted as a separate risk factor. NSD angle was also examined and calculated from coronal CT scans as the angle between the most deviated portion of the septum and the midline (Figure 1).

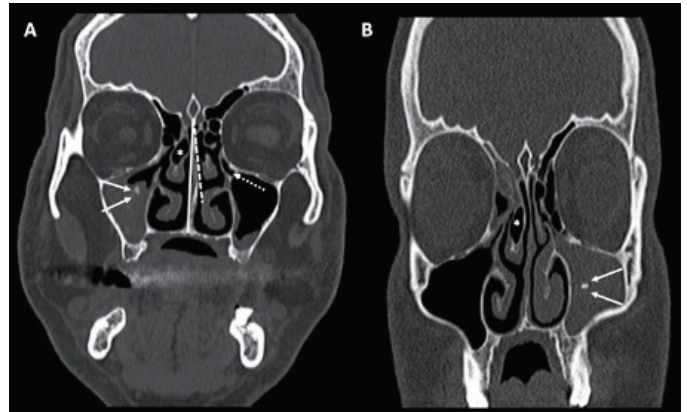


Figure 1. Anatomical variations examples with maxillary sinus fungus balls: (a) Determination of the nasal septal deviation side (straight white arrows: iron-like opacity; dashed white arrow: Haller cell; asterisk: concha bullosa); (b) (straight white arrows: iron-like opacity; asterisk: concha bullosa)

Endoscopic sinus surgery was performed under general anesthesia in all patients. Abundant sinus irrigation was done with saline solution during surgery until all fungal remains were removed. At the end of the surgery nasal packing was applied, and the packing was removed on the second postoperative day. Topical or systemic antifungal therapy were not prescribed. All patients were followed with nasal endoscopy every three months during the first postoperative year.

Statistical Analysis

Descriptive statistics were used to describe continuous variables (average, standard deviation, minimum, median and maximum). We determined significant differences by chi-square test and, if suitable, Fisher's exact test. P-values of <0.05 were assumed to be statistically significant. Statistical analyses were performed with GraphPad Prism (version 8.2.0 for Windows, GraphPad Software, La Jolla, CA, USA).

Results

There were 41 (62.1%) females and 25 (37.9%) male patients, with an age range of 10–84 years (mean: 45.63±17.14). Positive fungal culture was found in 60 patients (91%). The causative fungus was *Aspergillus* species in all cases.

The localizations of PNS FBs are summarized in Table 1. The most commonly affected sinus was the maxillary sinus (53%) followed by the sphenoid sinus (33.3%). A total of 66 patients had 70 FBs and all patients were unilateral, except for three patients (4.5%). Of these, one had bilateral maxillary sinus FB, one had bilateral sphenoid sinus FB, and one had right maxillary FB and left frontal sinus FB simultaneously.

Table 1. Localization of fungus balls

	n	(%)
Maxillary sinus (unilateral)	35	(53)
Sphenoid sinus (unilateral)	22	(33.3)
Frontal sinus	5	(7.6)
Maxillary sinus (left) and sphenoid sinus (left)	1	(1.5)
Maxillary sinus (left) and frontal sinus (right)	1	(1.5)
Maxillary sinus (bilateral)	1	(1.5)
Sphenoid sinus (bilateral)	1	(1.5)
Total	66	100

The analysis of anatomical variations is shown in Table 2. In maxillary sinus FB, both NSD and severe NSD (≥ 10 degrees) were more common on the unaffected side. In other words, the concave side of the deviated septum and the direction of maxillary sinus involvement were the same. However, the relationship between severe NSD and the localization of the maxillary sinus FB was not significant ($p > 0.05$). The maxillary sinus FB was significantly more common on the concave side of the NSD compared to the unaffected side ($p = 0.0409$). Haller cell was detected in both the affected and the unaffected sides in maxillary sinus FB, and a statistically significant difference was not found ($p > 0.05$). Concha bullosa was more common on the affected side in maxillary sinus FB, but this association was not statistically significant ($p > 0.05$).

In sphenoid sinus FB, NSD and severe NSD ($\geq 10^\circ$) were detected in similar numbers on both the affected and the

unaffected sides and there were no significant correlations ($p > 0.05$). Haller cell was more common on the affected side, although Onodi cell was more common on the unaffected side. However, there were no significant differences ($p > 0.05$). Lateral recess was found in 14 of the 24 sphenoid sinuses. Eleven of these were on the same side as FB and this association was significant (Figure 2, $p = 0.0262$).

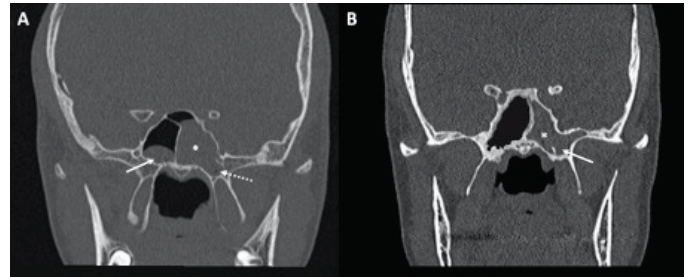


Figure 2. Fungus ball in the left sphenoid sinus (asterisk): (a) Straight white arrow shows mucous retention cyst in the right sphenoid while dashed white arrow shows lateral recess; (b) Straight white arrow shows lateral recess

In 35 of 38 patients who had maxillary sinus FB, 74 dental pathologies were identified on the affected sides. There were 51 dental pathologies on the unaffected sides. In three patients (3/38) with maxillary sinus FB on the affected side and 16 patients (16/38) on the unaffected side, CT scans revealed no dental pathology. Some examples of the dental pathologies are shown in Figure 3. The presence of dental pathologies on the affected side was significantly associated with FB compared to the unaffected side ($p = 0.0011$, Fisher's exact test) (Table 3). The most common pathologies were dental extraction (30/74, 40.5%) followed by endodontic treatment (18/74, 24.3%) and dental root in the maxillary sinus (10/74, 13.5%). The correlation between single dental pathology and FB was not significant.

Discussion

The presented study investigated the possible relationship between FBs and different anatomical variations that can

Table 2. Distribution of anatomical variations according to sinuses

	Nasal septum deviated to	Nasal septum severely deviated to	Haller cell	Onodi cell	Concha bullosa	Lateral recess
Maxillary sinus						
Affected side	11	5	5	2	10	2
Unaffected side	24*	13	4	1	6	1
Sphenoid sinus						
Affected side	4	1	1	7	2	11*
Unaffected side	6	2	5	2	1	3
Frontal sinus						
Affected side	-	-	1	1	1	-
Unaffected side	1	-	-	-	-	1

NSD: Nasal septal deviation, *: $p < 0.05$

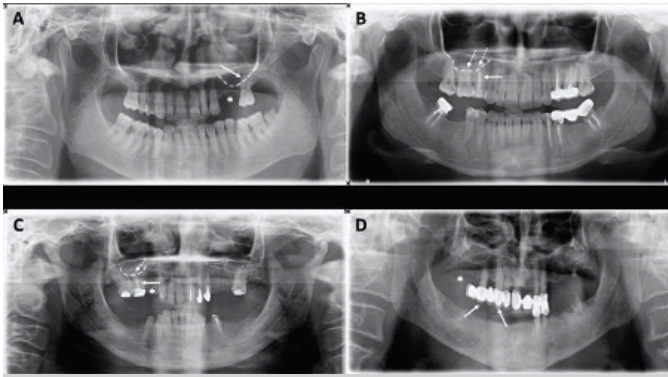


Figure 3. Dental pathologies examples: (a) Dental extractions (asterisk, numbers 24 and 25) and dental root in the maxillary sinus (white arrow: dental apex; dashed line: level of the maxillary sinus floor); (b) Endodontic treatment (straight white arrow) and dental root in the maxillary sinus (dashed white arrows: dental apex; dashed line: level of the maxillary sinus floor); (c) Dental extractions (asterisk, numbers 14 and 15), endodontic treatment (white arrow) and dental root in the maxillary sinus (dashed white arrow: dental apex; dashed line: level of the maxillary sinus floor); (d) Dental extractions (asterisk, numbers 16–18) and dental bridge (white arrows, numbers 13–15)

Table 3. Distribution of dental pathologies according to affected and unaffected side

	Affected side	Unaffected side	p-value
Dental extraction	30	22	0.8540
Endodontic treatment	18	8	0.2706
Dental root in the maxillary sinus	10	7	>0.9999
Apical periodontitis	8	3	0.5228
Implant	4	4	0.7148
Bony dehiscence at the sinus base	3	2	>0.9999
Dental bridge	1	5	0.0509
Dental pathology presence	35	22	0.0011

cause narrowing of the sinus drainage pathway or have a negative effect on mucociliary clearance. We also evaluated dental X-rays of the patients to see whether there were any associations between odontogenic etiology and maxillary sinus FB.

NSD is a well-known anatomical variation that may lead to recurrent rhinosinusitis. Deviation of the septum to one side of the nasal cavity causes chronic influences in nasal airflow. The nasal airflow increases in the contralateral side and decreases in the ipsilateral side. Comprehensive analysis of previous studies showed that an increased angle of NSD was markedly associated with increased frequency of rhinosinusitis, especially with a NSD of 10° or more (7). Oshima et al. (8) found a significant correlation between maxillary sinus FB and NSD in male patients. They discovered that maxillary sinus FB was markedly common on the concave side of the NSD in male patients. Why this association was observed only in males is not clear, but the authors speculated that the

relatively larger size of the male nasal cavity could be more sensitive to nasal airflow and its negative effects. Hwang et al. (9) described a statistically positive correlation between larger volume of the middle meatus and maxillary sinus FB. Also, they found no significant relationship between NSD and FB, or the nasal valve area and FB. In our study, a significant correlation between NSD and maxillary sinus FB was observed. Maxillary sinus FB was markedly common on the concave side of the nasal septum. However, the same correlation was not found in patients who had severe NSD. Chen et al. (10) detected increased turbulence and velocity in the middle meatal region on the concave side of the nasal septum. The traumatic effects of turbulent nasal airflow on the concave side can cause ostial stenosis and mucociliary dysfunction due to mucosal injury. Ostial stenosis and decreased mucociliary clearance can result in accumulation of fungal spores and development of FB in the sinus cavity.

Concha bullosa is known as middle turbinate pneumatization, which is associated with recurrent rhinosinusitis due to possible negative effects on both sinus ventilation and mucociliary clearance in the middle meatus (11). However, the role of concha bullosa in maxillary sinusitis development is controversial. In a review study, the presence of concha bullosa in the beginning or the sustaining of rhinosinusitis was not identified as being very important (12). In contrast, Caughey et al. (13) noted a significant association between concha bullosa and maxillary sinusitis. Oshima et al. (8) investigated a possible correlation of different anatomical variations and maxillary sinus FB. Interestingly, they discovered that concha bullosa formation was more prevalent on the healthy side, but this difference was not significant. Tsai et al. (6) reported that there was no structural relationship between concha bullosa and PNS FB. In our study, unlike Oshima et al. (8), concha bullosa was more common on the affected side with maxillary sinus FB. However, a significant correlation was not found between concha bullosa and maxillary sinus FB.

Haller cell is known as infraorbital air cell, which expands from the ethmoid cavity into the maxillary sinus. This air cell may prevent both pneumatization and drainage of the maxillary sinus, hence it can cause recurrent maxillary sinusitis (11). In a review study, Jones (12) noted that Haller cell was not associated with the pathogenesis of maxillary sinusitis. On the other hand, in another study Haller cell was found to be related to both ethmoid and maxillary mucosal disease (13). Oshima et al. (8) examined the relationship of Haller cell and maxillary sinus FB. They reported that FB was present on both the affected and the unaffected sides, but no significant correlation was detected. In the presented study, Haller cell was detected in both the affected side and the healthy side, indicating no significant correlation between Haller cell and maxillary sinus FB.

Onodi cell is the most common anatomical variant of the posterior ethmoidal air cells that pneumatize superiorly and laterally to the sphenoid sinus (14). To our knowledge, there

is no study that investigated the association of Onodi cell and sphenoid sinus FB. In our study, Onodi cell presence was more common on the unaffected sides, but this finding was not significant. However, a significant correlation was present between the lateral recess and FB localization. Sphenoid sinus FB was significantly more common on the same side as the lateral recess. Sphenoid sinus pneumatization can extend into greater wings of the sphenoid bone, resulting in lateral recess. The lateral recess drains into the sphenoidal recess via the sphenoid ostium. The drainage pathway of the lateral recess is against gravity and this situation can lead to difficulty in mucociliary clearance. If suitable environmental conditions are present, the accumulation of fungal spores, which cannot be cleared by the mucosal defense mechanism, can cause FBs.

There are many case reports in the literature that define the association of FB and odontogenic etiologies such as endodontic treatment, dental overfilling, oroantral fistula and dental implant (15-19). Tomazic et al. (20) investigated the association between dentogenic factors and maxillary sinus FB in 102 patients. They reported that the presence of dentogenic factors was significantly associated with FB compared to the healthy side. However, in the referred study, there was no significant relationship between a single dentogenic factor and FB. Mensi et al. (21) reported that patients who underwent endodontic treatment on the upper premolars, molars, and canines, had a 14-fold increased risk for maxillary sinus FB development. Legent et al. (22) investigated dental canal filling and a fungal sinusitis relationship in 85 patients, 85% of whom had dental overfilling of the maxillary sinus. In our study, maxillary sinus FB was found to be markedly frequent in patients who had dental disease or treatment history. Nevertheless, the relationship of a single dental pathology and maxillary FB localization was not statistically significant. Our results support that a combination of dental pathologies should be present in the same patient for maxillary sinus FB development.

Our study focused on both anatomical variations and odontogenic etiologies. The unaffected side was accepted as the negative control group. For this reason, other risk factors such as systemic disease, smoking, air pollution and occupational exposure, which may play a role in fungal sinusitis development, could not be examined. Fungal sinusitis is a multifactorial disease and cannot be explained via a simple cause-effect relationship. Therefore, further prospective randomized controlled trials with a large number of patients are necessary.

Conclusion

Our study revealed that the maxillary sinus FB were more common on the concave side of the nasal septal deviation. This finding may state the outcomes of the traumatic effects caused by wall shear stress of the high-velocity air flow and the

increased possibility of the inhalation of fungal spores. Also, dental pathologies or dental treatment history, regardless of type, were significantly associated with maxillary sinus FB. Patients who have dental disease or have undergone dental treatment should be closely monitored and informed about the possible risk of FB development.

Ethics Committee Approval: Ethics committee approval was given by the Clinical Research Ethics Committee of İstanbul University İstanbul Faculty of Medicine (no: 1174/2019).

Informed Consent: Retrospective study.

Peer-review: Externally peer-reviewed.

Authorship Contributions

Concept: B.Ş., Ş.C., Design: B.Ş., Ş.C., Supervision: M.N.K.T., Data Collection and/or Processing: B.Ş., S.S., Analysis and/or Interpretation: K.D., Writing: B.Ş., Ş.C., S.S., Critical Review: K.D., M.N.K.T.

Conflict of Interest: The authors declare there are no conflicts of interest.

Financial Disclosure: The authors declared that this study has received no financial support.

Main Points

- Nasal airflow turbulence and mucociliary clearance dysfunction are extremely important for the pathophysiology of fungal sinusitis.
- Our study revealed that the maxillary sinus FB were more common on the concave side of the nasal septal deviation.
- Dental pathologies or presence of dental treatment history are associated with maxillary sinus FB.

References

1. Grosjean P, Weber R. Fungus balls of the paranasal sinuses: a review. *Eur Arch Otorhinolaryngol* 2007; 264: 461-70. [Crossref]
2. Thompson GR 3rd, Patterson TF. Fungal disease of the nose and paranasal sinuses. *J Allergy Clin Immunol* 2012; 129: 321-6. [Crossref]
3. Seo MY, Lee SH, Ryu G, Hong SD, Kim HY, Dhong HJ, et al. Clinical pattern of fungal balls in the paranasal sinuses: our experience with 70 patients. *Eur Arch Otorhinolaryngol* 2019; 276: 1035-8. [Crossref]
4. Stammberger H. Endoscopic surgery for mycotic and chronic recurring sinusitis. *Ann Otol Rhinol Laryngol Suppl* 1985; 119: 1-11. [Crossref]
5. Eloy P, Bertrand B, Rombeaux P, Delos M, Trigaux JP. Mycotic sinusitis. *Acta Otorhinolaryngol Belg* 1997; 51: 339-52. [Crossref]

6. Tsai TL, Guo YC, Ho CY, Lin CZ. The role of ostiomeatal complex obstruction in maxillary fungus ball. *Otolaryngol Head Neck Surg* 2006; 134: 494-8. [Crossref]
7. Orlandi RR. A systematic analysis of septal deviation associated with rhinosinusitis. *Laryngoscope* 2010; 120: 1687-95. [Crossref]
8. Oshima H, Nomura K, Sugawara M, Arakawa K, Oshima T, Katori Y. Septal deviation is associated with maxillary sinus fungus ball in male patients. *Tohoku J Exp Med* 2014; 232: 201-6. [Crossref]
9. Hwang SH, Kang JM, Cho JH, Kim BG. What is the relationship between the localization of maxillary fungal balls and intranasal anatomic variations? *Clin Exp Otorhinolaryngol* 2012; 5: 213-7. [Crossref]
10. Chen XB, Lee HP, Chong VF, Wang de Y. Assessment of septal deviation effects on nasal air flow: a computational fluid dynamics model. *Laryngoscope* 2009; 119: 1730-6. [Crossref]
11. Bolger WE, Butzin CA, Parsons DS. Paranasal sinus bony anatomic variations and mucosal abnormalities: CT analysis for endoscopic sinus surgery. *Laryngoscope* 1991; 101: 56-64. [Crossref]
12. Jones NS. CT of the paranasal sinuses: a review of the correlation with clinical, surgical and histopathological findings. *Clin Otolaryngol Allied Sci* 2002; 27: 11-7. [Crossref]
13. Caughey RJ, Jameson MJ, Gross CW, Han JK. Anatomic risk factors for sinus disease: fact or fiction? *Am J Rhinol* 2005; 19: 334-9. [Crossref]
14. Stammberger HR, Kennedy DW, Anatomic Terminology Group. Paranasal sinuses: anatomic terminology and nomenclature. *Ann Otol Rhinol Laryngol Suppl* 1995; 167: 7-16. [Crossref]
15. Burnham R, Bridle C. Aspergillosis of the maxillary sinus secondary to a foreign body (amalgam) in the maxillary antrum. *Br J Oral Maxillofac Surg* 2009; 47: 313-5. [Crossref]
16. Sohn DS, Lee JK, Shin HI, Choi BJ, An KM. Fungal infection as a complication of sinus bone grafting and implants: a case report. *Oral Surg Oral Med Oral Pathol Oral Radiol Endod* 2009; 107: 375-80. [Crossref]
17. Fanucci E, Nezzo M, Neroni L, Montesani L Jr, Ottria L, Gargari M. Diagnosis and treatment of paranasal sinus fungus ball of odontogenic origin: case report. *Oral Implantol (Rome)* 2014; 6: 63-6. [Crossref]
18. Shams MG, Motamedi MH. Aspergilloma of the maxillary sinus complicating an oroantral fistula. *Oral Surg Oral Med Oral Pathol Oral Radiol Endod* 2003; 96: 3-5. [Crossref]
19. Khongkhunthian P, Reichart PA. Aspergillosis of the maxillary sinus as a complication of overfilling root canal material into the sinus: report of two cases. *J Endod* 2001; 27: 476-8. [Crossref]
20. Tomazic PV, Dostal E, Magyar M, Lang-Loidolt D, Wolf A, Koele W, et al. Potential correlations of dentogenic factors to the development of clinically verified fungus balls: a retrospective computed tomography-based analysis. *Laryngoscope* 2016; 126: 39-43. [Crossref]
21. Mensi M, Piccioni M, Marsili F, Nicolai P, Sapelli PL, Latronico N. Risk of maxillary fungus ball in patients with endodontic treatment on maxillary teeth: a case-control study. *Oral Surg Oral Med Oral Pathol Oral Radiol Endod* 2007; 103: 433-6. [Crossref]
22. Legent F, Billet J, Beauvillain C, Bonnet J, Miegerville M. The role of dental canal fillings in the development of *Aspergillus* sinusitis. A report of 85 cases. *Arch Otorhinolaryngol* 1989; 246: 318-20. [Crossref]