

The Role of PET-CT in Evaluation of Cervical Lymph Node Metastases in Oral Cavity Squamous Cell Carcinomas

Fatma Çaylaklı¹, Serkan Yılmaz¹, Cem Özer¹, Mehmet Reyhan²

¹Department of Otorhinolaryngology, Başkent University Faculty of Medicine, Adana, Turkey

²Department of Nuclear Medicine, Başkent University Faculty of Medicine, Adana, Turkey

Original Investigation

Abstract

Objective: The aim of this study is to determine the sensitivity and specificity of positron emission tomography-computed tomography (PET-CT) in the evaluation of cervical lymph node metastasis in oral cavity squamous cell cancers (SCCs) and to determine the SUV-max values in differentiating reactive and metastatic lymph nodes as a supportive parameter.

Methods: In this study, 23 patients were included who were diagnosed with oral cavity SCC and treated with surgery between 2006 and 2013 in our department. All the patients were scanned with PET-CT during the pretreatment evaluation. Detailed pretreatment PET-CT (retention sites and SUV-max values) and histopathological examination results were obtained. SPSS 17.0 software package was used for statistical analysis of the data. Categorical measurement was summarized as number and percentage and continuous measurements as mean and standard deviation (median and minimum-maximum where necessary). Chi-square test or Fisher's test were used in the comparison of categorical variables. Compliance of methods was assessed by Kappa coefficient analysis. In this study, the advantages of PET-CT were determined by the calculation of sensitivity and specificity values with histopathological examination results considered as the gold standard, and

SUV-max value was assessed by examining the area under the ROC curve. In all tests, the level of statistical significance was accepted as 0.05.

Results: The threshold value for SUV-max depending on the data of the histopathological examination and results of PET-CT of the 23 patients was 2.50. The reliability of this threshold was determined as AUC=0.819. In demonstrating neck metastasis in patients with cancer of the oral cavity, PET-CT has a sensitivity of 89% and specificity of 98%. Compliance between the histopathological examination and PET-CT for metastatic cervical lymph nodes was determined to be 0.416 by kappa coefficient analysis.

Conclusion: There was FDG uptake on PET-CT in the cervical lymph node regions of all patients with metastatic cervical lymph nodes. There were no metastases in any of the patients with no FDG retention. The sensitivity and specificity of PET-CT in determining cervical lymph node metastasis were 89% and 98%, respectively, with a threshold SUV-max value considered as 2.50 in patients with FDG retention.

Keywords: Oral cavity, squamous cell carcinoma, positron emission tomography, neck, metastasis

Introduction

Oral cavity cancer is the sixth most common cancer type worldwide. Presence of cervical lymph node metastasis, location of the tumor and its size are the most important prognostic factors in the patients with head and neck squamous cell carcinoma (SCC)(1, 2). Routine staging method for preoperative detection of cervical lymph node metastasis in the patients with oral cavity SCC comprised of physical examination and computed tomography (CT)/ magnetic resonance imaging (MRI) (3, 4). Positron emission tomography (PET) imaging also took its place in this evaluation by the recent technological developments. Histopathologic examination with neck dissection is the most reliable staging method giving significant prognostic information.

Fluorine-18 fluorodeoxyglucose (18F-FDG) PET is a functional imaging technique providing data about tissue metabolism and having been applied successfully in the evaluation of head and neck cancer. Standardized uptake value (SUV) is a numerical criterion used in the separation of the lesions as malign/benign, by indicating whether a lesion has increased 18F-FDG activity (5). The aim of the study is to determine PET-CT's sensitivity and specificity for evaluating cervical lymph node metastasis in oral cavity SCC's and to detect maximum standardized uptake value (SUV-max) as a supportive parameter in reactive and metastatic lymph node separation.

Methods

Twenty three patients who were diagnosed with oral cavity SCC, administered surgical treatment



This study was presented at 35th National Otorhinolaryngology and Head and Neck Surgery Congress, 2-6 November 2013, Antalya, Turkey.

Address for Correspondence:

Serkan Yılmaz, Başkent Üniversitesi Tıp Fakültesi, Kulak Burun Boğaz Hastalıkları Anabilim Dalı, Adana, Turkey

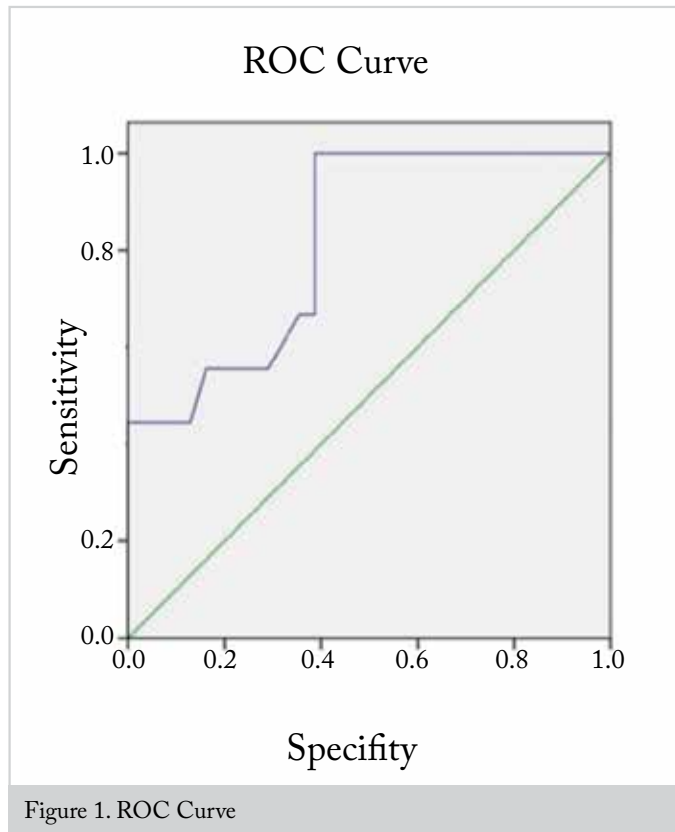
Phone: +90 322 458 68 68

E-mail: dr.syilmaz@yahoo.com

Received Date: 06.07.2014

Accepted Date: 15.06.2015

© Copyright 2015 by Official Journal of the Turkish Society of Otorhinolaryngology and Head and Neck Surgery Available online at www.turkarchotorhinolaryngol.org DOI:10.5152/tao.2015.608



and scanned with PET-CT in our clinic between 2006-2013 were included in the study. The PET-CT results (involvement locations and SUV-max values) and histopathologic examination results were obtained. The approval for this retrospective study was received from Başkent University Medicine Faculty Clinical Studies Committee (KA13/156). Whole body images of the patients were taken after the 60 minutes resting phase following intravenous injection of 370-555 MBq (10-15 mCi) ^{18}F -FDG by using PET-CT (Discovery-STE 8; General Electric Medical System, Milwaukee, WI). The patients were required to be fasting for 6 hours prior to the examination it was paid attention that blood glucose levels were under 200mg/dl. The patients spent the resting period without moving and speaking in a quiet room. Firstly their non-contrast-enhanced (section thickness of 3,3 mm) images at the dose of attenuation (140 kV, 80 mA) in vertex-thigh level and just after that their 3D mode 3 min/bed position PET images were taken. Combined (fusion) images for attenuation corrections were obtained by using CT images. In our study, neck dissection and cervical lymph node regions were defined taking into consideration American Academy of Otolaryngology Head and Neck guidelines (AAO-HNS) (6).

Statistical Analysis

SPSS 17.0 (SPSS Inc. 233 South Wacker Drive, 11th Floor Chicago, IL 60606-6412) packaged software was used in statistical analysis of the data. Categorical measurements were summarized as numerical and percentage and continuous measurements were summarized as mean

Table 1. Tumor localizations of the cases and phases

Features	Number of cases	%
Localization		
Tongue	12	52.1
Lip	4	17.4
Buccal	3	13
Mouth floor	2	8.7
Alveolar process	2	8.7
T		
T1	8	34.8
T2	9	39.1
T3	2	8.7
T4	4	17.4
N		
N0	16	69.6
N1	2	8.7
N2b	2	8.7
N2c	3	13
Phase		
1	8	34.8
2	4	17.4
3	4	17.4
4	7	30.4

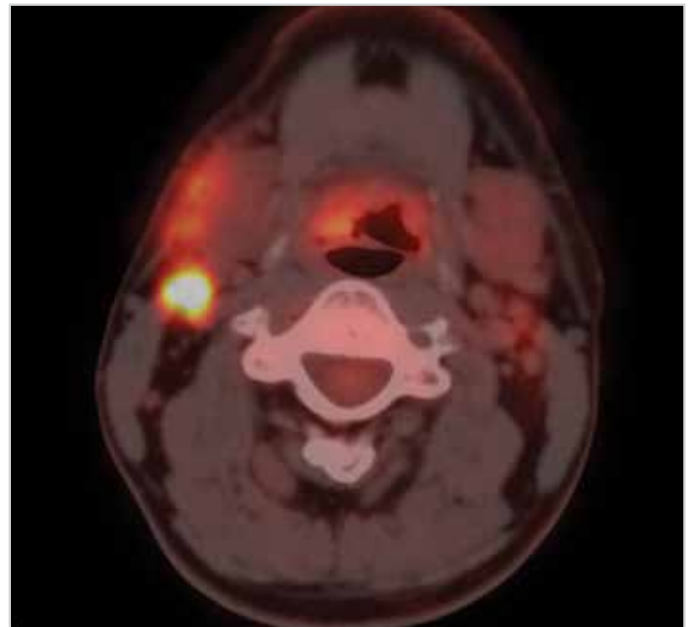


Figure 2. PET-CT axial image of the patient having SUV-max value of 15.4 at the right first region

and standard deviation (median and minimum-maximum where necessary). Chi Square Test or Fisher's Test were used in comparison of categorical variables. The concordance among the methods was evaluated with Kappa Concordance Analysis.

Table 2. Comparison of 23 patient's histopathological examination and PET-CT results with regard to metastatic lymph node

Patient	Neck Dissection						PET-CT				PET-BT-Operation	Clinical stage
	Right			Left			Right		Left			
	Dissected levels	MLN localization	Number of MLN	Dissected levels	MLN localization	Number of MLN	FDG localization	SUV-max	FDG localization	SUV-max		
1.M.Ö	level 2-5	-	-	-	-	-	-	-	-	-	3 DAY	T2N0M0
2.TI	level 1-4	-	-	level 1-4	-	-	level 2	3.9	level 2	3.9	9 DAY	T1N0M0
3.A.U	level 1-3	-	-	level 1-3	-	-	level 2	4.5	level 1 and 2	4.7 and 3.6	15 DAY	T1N0M0
4.D.G	-	-	-	level 1-3	-	-	-	-	-	-	9 DAY	T1N0M0
5.M.K	level 1-3	-	-	level 1-5	-	-	level 2	3.1	level 1	4.6	24 DAY	T2N0M0
6.R.Y	-	-	-	level 1-5	-	-	-	-	-	-	6 DAY	T2N0M0
7.Y.E	level 1-5	level 1	6	-	-	-	level 1	15.4	level 2	2.7	2 DAY	T1N1M0
8.M.A.Ş	level 1-3	-	-	level 1-3	-	-	-	-	level 1 and 2	4 and 2.9	2 DAY	T1N1M0
9.M.G	-	-	-	level 1-5	level 1,2 and 3	1,4, and 3	-	-	level 1 and 2	10.3	11 DAY	T4N2cM0
10.M.A	-	-	-	level 1-3	-	-	-	-	-	-	8 DAY	T2N0M0
11.A.Ş	level 1-4	-	-	-	-	-	-	-	-	-	20 DAY	T1N0M0
12.F.A	level 1-5	level 1 and 2	2 and 2	level 1-3	level 1	1	level 1 and 2	5.6	level 1	5.6	2 DAY	T4N1M0
13.M.Z	level 2-4	level 2	1	level 2-4	-	-	level 2	1.8	-	-	7 DAY	T2N0M0
14.M.Y	level 1-4	-	-	-	-	-	level 2	3.5	-	-	6 DAY	T1N0M0
15.N.S	level 1-4	-	-	level 2-4	-	-	-	-	level 1	2.7	18 DAY	T1N0M0
16.O.D	level 1-5	-	-	level 1-5	level 1 and 3	2 and 1	-	-	level 1	3.6	6 DAY	T2N1M0
17.S.A	-	-	-	level 1-5	-	-	-	-	level 4	2.3	9 DAY	T3N0M0
18.T.D	level 1-5	level 2 and 5	1 and 1	level 1-5	level 3 and 4	1 and 1	level 2 and 5	3.6 and 1.1	level 2, 3, and 4	3.6, 8.1 and 1.4	15 DAY	T4N2bM0
19.Ü.K	level 1-4	-	-	level 2-5	-	-	-	-	-	-	12 DAY	T2N0M0
20.H.Ü	level 1-5	-	-	level 1-5	-	-	level 1 and 2	4 and 2.7	level 2	3.2	5 DAY	T3N1M0
21.S.K	level 1-5	-	-	level 2-4	-	-	-	-	-	-	9 DAY	T3N0M0
22.E.D	level 1-5	level 2	1	level 1-3	-	-	level 2	2.7	-	-	6 DAY	T2N0M0
23.N.G	level 1-2	-	-	level 1-3	-	-	-	-	-	-	13 DAY	T2N0M0

MLN: metastatic lymph node

Histopathologic examination results were accepted as golden standard; superiorities, sensitivity and specificity values were calculated and the area below ROC curve for SUV-max value is examined and evaluated. Statistical significance level in all tests was taken as 0.05.

Results

Eight female (34.8%), 15 male (65.2%) patients and totally 23 patients were included in the study. The mean age of the patients was 57.4 (35-77) years. The diagnoses for which patients were treated were tongue SCC in 12 patients (52.1%), lip SCC in 4

patients (17.4%), buccal SCC in 3 patients (13%), floor of the mouth SCC in 2 patients (8.7%), and alveolar process SCC in 2 patients (8.7%) (Table 1).

PET-CT was applied to all patients 9.04 days on average before the operation (2-24). Primary tumor surgery with neck dissection was administered to all of the patients. Twenty eight metastatic lymph nodes at 15 levels in 7 patients were detected. Preoperative PET-CT and histopathological examination results were compared with respect to metastatic involvement in the neck (Table 2).

SUV-max threshold value for metastasis was detected as 2.50 with ROC curve according to histopathological examination and PET-CT data. The reliability of this threshold value was calculated as (AUC)=0.819 (Figure 1). Of 28 metastatic lymph nodes histopathologically detected with PET-CT in the patients with oral cavity cancer according to this threshold value, 25 of them were detected true positive and 3 of them were detected false negative results. Eleven of the 15 metastasis levels with PET-CT were detected true positive and 4 of them were detected false negative (Figure 2). False positive results in totally 16 levels and 16 lymph nodes were detected (Table 3). According to these data, when SUV-max threshold value is taken as 2.50, sensitivity, specificity, positive predictive value (PPV), negative predictive value (NPV), and accuracy were detected as 73%, 87%, 40.7%, 96.6% and 86% respectively for the region in determining cervical lymph node metastasis of PET-CT. When it was considered with respect to lymph node metastasis, sensitivity, specificity, positive predictive value (PPV), negative predictive value (NPV), and accuracy were detected as 89%, 98%, 60.9%, 99.7% and 98.5% respectively (Table 4)

With regard to metastatic lymph node, histopathological examination and PET-CT concordance were determined as 0.416 with Kappa concordance analysis.

Discussion

In oral cavity cancers, neck metastasis possibility is high due to rich lymphatic drainage. The rate of occult metastasis is fairly high in oral cavity cancers. Various rates changing between 34% and 42% have been reported in the literature. Due to these occult metastasis rates elective neck dissection indication to the patients arises. In the literature, there are also some defending

the “wait and see” approach for clinical N0 necks (7). We apply the primary treatment approach to the neck in our clinic as applied to the patients having N0 neck. If our primary treatment approach is radiotherapy we also apply radiotherapy to the neck, if our approach is surgical then we conduct elective neck dissection and in the presence of suspicious involvement we add neck dissection to the location involved.

Early phase oral cavity SCC can be brought under control locally by surgery and/or radiotherapy successfully. However aside from primary tumor, doing the treatment planning of the neck regardfully is very important in the course of the disease (8, 9). The most important prognostic factor in head and neck cancers is the involvement of cervical lymph nodes. This is also valid for oral cavity cancers (10,11). The presence of metastasis in only one lymph node lowers the survival rate of the patient at a rate of almost 50% (10). Therefore, correct treatment of the cervical lymph nodes has critical importance for the patient.

Imaging methods are required in determining nodal metastasis. PET-CT has taken its place after MRI and CT. PET is a nuclear medicine imaging technique effectiveness of which has been proved, showing the changes in function and metabolism of organ and tissues with anatomical details. It is the most advanced medical imaging method used in detection of tumor especially in oncology, conducting staging, evaluation of the response to the treatment, restaging in case of relapse/metastasis suspicion and rising of the tumor markers, radiotherapy planning and in detecting whether the tumor is benign or malignant (13). Since PET studies indicate the metabolic changes, it provides information about the lesion earlier than the other imaging methods and PET-CT studies contribute to the early diagnosis and correct staging of the disease due to the fact that anatomical localization and details are indicated with CT (14). In many studies conducted to determine lymph node metastasis, PET-CT has been found to have higher sensitivity (64%-100%) and specificity (67%- 100%) and a more frequently preferred method when compared to MRI and CT (15, 16).

In Piao et al.'s study (17) sensitivity, specificity, PPD and NPD and accuracy in detection of metastasis region in the neck were found as 84%, 87%, 75% and 94% respectively. The threshold value was determined as SUV-max>2.5. In the study of Mochuziki et al. when threshold value is taken as 2.5 for SUV-max sensitivity, specificity, PPD and NPD and accuracy were found 75%, 63.8%, 19.1%, 95.7% and 65% respectively. In Chun Ta

Table 3. Comparison of PET-CT and histopathological examination with regard to determination of the level and lymph node metastasis in the neck

PET-CT	HISTOPATHOLOGICAL EXAMINATION	
	Positive	Negative
Level		
Positive	11 (TP)	16 (FP)
Negative	4 (FN)	114 (TN)
Lymph Node		
Positive	25 (TP)	16 (FP)
Negative	3 (FN)	1253 (TN)

TP: true positive; FP: false positive; TN: true negative; FN: false negative

Table 4. Sensitivity, specificity, positive predictive value (PPV), negative predictive value (NPV) and accuracy of cervical lymph node metastasis and its region detected by PET-CT

	Sensitivity	Specificity	PPV	NPV	Accuracy
Region	11/15 (73%)	114/130 (87%)	40.7%	96.6%	125/145(86%)
Lymph node	25/28 (89%)	1253/ 1269 (98%)	60.9%	99.7%	1278/1297(98.5%)

Liao et al.'s (19) study including 473 patients, when SUV-max threshold value is taken as 3.1, sensitivity and specificity were found 79.9% and 59.4% respectively. In our study when the threshold value is taken as 2.5 in detection of the metastatic region in the neck, sensitivity, specificity, PPD and NPD and accuracy were found 73%, 91%, 40.7%, 96.6% and 86% respectively. These data obtained in our study were in line with the other studies. These results indicate that PET-CT nowadays has an important place to evaluate cervical lymph node metastasis in oral cavity cancers.

In our study it was observed that there was FDG involvement with PET-CT in all metastatic lymph nodes of the neck. However complex anatomy of head and neck and accumulation of nonspecific physiological FDG may decrease 18F-FDG PET-CT effectiveness in head and neck region (20). In order to detect metastatic lymph node with PET-CT and distinguish it from the physiological involvement, it is necessary to determine a threshold value. In this study when threshold SUV-max value is taken as 2.50 in the patients with oral cavity having FDG involvement the sensitivity, specificity and accuracy of PET-CT in determining lymph node metastasis were found 89%, 98% and 98.5% respectively. Consequently, it was seen that PET-CT can be used as a reliable method in determining metastatic lymph node of the neck in the patients with oral cavity SCC and treatment planning.

Ethics Committee Approval: Ethics committee approval was received for this study.

Informed Consent: Written informed consent was not obtained due to the retrospective nature of this study.

Peer-review: Externally peer-reviewed.

Author Contributions: Concept - F.Ç., S.Y.; Design - F.Ç., S.Y.; Supervision - F.Ç., C.Ö.; Funding - M.R.; C.Ö.; Materials - M.R.; Data Collection and/or Processing - S.Y., M.R.; Analysis and/or Interpretation - F.Ç., C.Ö.; Literature Review - S.Y., C.Ö.; Writing - S.Y., F.Ç.; Critical Review - F.Ç., C.Ö.

Conflict of Interest: No conflict of interest was declared by the authors.

Financial Disclosure: The authors declared that this study has received no financial support.

References

- Brown AE, Langdon JD. Management of oral cancer. *Ann R Coll Surg Engl* 1995; 77: 404-8.
- Snow GB, Patel P, Leemans CR, Tiwari R. Management of cervical lymph nodes in patients with head and neck cancer. *Eur Arch Otorhinolaryngol* 1992; 249: 187-94. [CrossRef]
- Woolgar JA. Histopathological prognosticators in oral and oropharyngeal squamous cell carcinoma. *Oral Oncol* 2006; 42: 229-39. [CrossRef]
- Liao CT, Chang JT, Wang HM, Ng SH, Hsueh C, Lee LY, et al. Analysis of risk factors predictive of local tumor control in oral cavity cancer. *Ann Surg Oncol* 2008; 15: 915-22. [CrossRef]
- Arslan N, Onkolojik PET çalışmaları. Ozguven MA, Oztruk E, Gunalp B, Ilgan S, Arslan N, Karaçalıoğlu AO, editörler. *Pozitron Emisyon Tomografisi El Kitabı*, 1. Baskı. Ankara: GATA Basımevi; 2005. p. 13-9.
- Robbins KT, Shaha AR, Medina JE, Califano JA, Wolf GT, Ferlito A, et al. Committee for Neck Dissection Classification, American Head and Neck Society. Consensus statement on the classification and terminology of neck dissection. *Arch Otolaryngol Head Neck Surg* 2008; 134: 536-8. [CrossRef]
- Özmen ÖA, Saraydaroğlu G, Erişen L, Kasapoğlu F. Dil gövdesi ve ağız tabanı yassı hücreli kanserlerinde boynun tedavisinde Uludağ deneyimi. *Turk Arch Otolaryngol* 2009; 47: 69-76.
- Yii NW, Patel PH, Rhys-Evans PH, Breach NM. Management of the N0 neck in early cancer of the oral tongue. *Clin Otolaryngol* 1999; 24: 75-9. [CrossRef]
- Tankere F, Camproux A, Barry B, Guedon C, Depondt J, Gehanno P. Prognostic value of lymph node involvement in oral cancers: a study of 137 cases. *Laryngoscope* 2000; 110: 2061-5. [CrossRef]
- Lim YC, Lee JS, Choi EC. Perifacial lymph node metastasis in the submandibular triangle of patients with oral and oropharyngeal squamous cell carcinoma with clinically node-positive neck. *Laryngoscope* 2006; 116: 2187-90. [CrossRef]
- Shingaki S, Takada M, Sasai K. Impact of lymph node metastasis on the pattern of failure and survival in oral carcinomas. *Am J Surg* 2003; 185: 278-84. [CrossRef]
- Mudun A. Türkiye'de PET görüntülemenin durumu. *Turk J Nucl Med* 2008; 17: 1-9.
- Hallaç M. Baş Boyun Kanserlerinde Moleküler Görüntülemenin (PET/BT) Önemi. *Türkiye Klinikleri J Med Oncol-Special Topics* 2010; 3: 23-31.
- Şanlı Y, Tekin BO, Tokmak H, Bozkurt F, Töre G, Bekiş R, et al. F18-FDG PET/BT ile onkolojik görüntüleme uygulama kılavuzu. <http://www.tsnm.org/2012/index.php> (accessed Nov 2012).
- Hao SP, Ng SH. Magnetic resonance imaging versus clinical palpation in evaluating cervical metastasis from head and neck cancer. *Otolaryngol Head Neck Surg* 2000; 123: 324-7. [CrossRef]
- McGuirt WF, Williams DW, Keyes JW Jr, Greven KM, Watson NE Jr, Geisinger KR, et al. A comparative diagnostic study of head and neck nodal metastases using positron emission tomography. *Laryngoscope* 1995; 105 (4 Pt1): 373-5. [CrossRef]
- Piao Y, Bold B, Tayier A, Ishida R, Omura K, Okada N, et al. Evaluation of 18F-FDG PET/CT for diagnosing cervical nodal metastases in patients with oral cavity or oropharynx carcinoma. *Oral Surg Oral Med Oral Pathol Oral Radiol Endod* 2009; 108: 933-8. [CrossRef]
- Mochizuki Y, Omura K, Nakamura S, Harada H, Shibuya H, Kurabayashi T. Preoperative predictive model of cervical lymph node metastasis combining fluorine-18 fluorodeoxyglucose positron-emission tomography/computerized tomography findings and clinical factors in patients with oral or oropharyngeal squamous cell carcinoma. *Oral Surg Oral Med Oral Pathol Oral Radiol* 2012; 113: 274-82. [CrossRef]

19. Liao CT, Wang HM, Huang SF, Chen IH, Kang CJ, Lin CY, et al. PET and PET/CT of the neck lymph nodes improves risk prediction in patients with squamous cell carcinoma of the oral cavity. *J Nucl Med* 2011; 52: 180-7. [\[CrossRef\]](#)
20. Nakamura S, Okochi K, Kurabayashi T. Dual-time-point fluoro-deoxyglucose positron emission tomography for diagnosis of cervical lymph node metastases in patients with head and neck squamous cell carcinoma. *J Comput Assist Tomogr* 2011; 35: 303-7. [\[CrossRef\]](#)