

## Lemierre's Syndrome Case Secondary to Otitis Media

### Case Report

Göksel Turhal, Sercan Göde, Kerem Öztürk, Cem Bilgen, Tayfun Kirazlı  
Department of Otorhinolaryngology, Ege University Faculty of Medicine, İzmir, Turkey

### Abstract

Lemierre's syndrome is a rare but fatal thrombophlebitis of the internal jugular vein (IJV). It usually follows acute oropharyngeal infections in healthy, young adults. *Fusobacterium necrophorum* is the most common bacteria that causes Lemierre's syndrome, whereas various microorganisms are reported. We are reporting a case with

Lemierre's syndrome secondary to otitis media, which is a rare occurrence of a rare disease.

**Keywords:** Lemierre's syndrome, otitis media, jugular vein, thrombophlebitis

### Introduction

Lemierre's syndrome is a rarely seen fatal infection that progresses with septic thrombophlebitis of the internal jugular vein (IJV). It is generally caused by *Fusobacterium necrophorum*, although various bacteria have been reported. Bacteremia and metastatic septic emboli is a consequence of the hematogenous spread. While the clinical diagnosis suggested fulminant sepsis and death in the pre-antibiotic era, the rate of disease-associated morbidity and mortality has seriously decreased with the initiation of antibiotic usage. In most of the cases, the primary source of infection is palatine tonsils and peritonsillar tissue (87.1%), but it can rarely develop secondary to mastoiditis (2.7%), odontogenic infections (1.8%), parotitis, sinusitis, and primary infections of cutaneous and subcutaneous tissues of the head and neck region (1). In this study, the case of a patient who presented to the emergency department with the complaints of ear discharge and decreased hearing and whose examination results revealed IJV thrombophlebitis secondary to otitis media is described.

### Case Report

A 30-year-old male patient without any known comorbid disease presented to the emergency department with the complaints of upper respiratory tract infection and bloody discharge from the right ear lasting for 3 days. On conducting a physical examination of the patient, no pathology was detected except a temperature of 37°C, severe edema in the right middle ear, and hemorrhagic and purulent ear discharge (Figure 1). It was learned from his medical history that he

had not previously experienced any otological problem. No tenderness or mass was observed during neck palpation. In the hemogram, the levels of leucocyte, neutrophil, and thrombocytopenia were found to be 7100/ $\mu$ L, 86.7%, and 40,000/ $\mu$ L, respectively. In blood biochemistry, increased creatinine (3.2 mg/dL) and CRP (19.1 mg/dL) levels were remarkable. His blood pressure level at the time of admission was detected to be low (75/49 mmHg). Because the patient was observed to be confused, cranial computed tomography (CT) was firstly performed in the emergency department considering perisinusoidal abscess. In cranial CT, thrombophlebitis was found in the right sigmoid and transverse sinuses, but no intracranial pathology was detected. For laboratory and imaging examinations of the patients performed for evaluating his general health condition, the patient underwent abdominal ultrasonography (USG), temporal CT, contrast-enhanced CT angiography of the neck and thorax, and cranial magnetic resonance (MR) imaging because of the suspicion of septic thrombophlebitis and multi-organ involvement. Imaging techniques revealed otomastoiditis in the right middle ear cavity, thrombophlebitis continuing along jugular vein and extending upto the sigmoid and transverse sinuses in the right ear, and minimal pleural effusion and consolidation areas consistent with septic emboli in the lung (Figure 2-4). The patient was transferred to the Internal Diseases Clinic with the diagnoses of complicated otitis media, acute renal tubular necrosis, sepsis and pancytopenia secondary to sepsis, and septic pulmonary emboli. Because he did not have intracranial abscess, intravenous (IV) hy-



**Address for Correspondence:**  
Göksel Turhal, Ege Üniversitesi Tıp Fakültesi,  
Kulak Burun ve Boğaz Hastalıkları Anabilim Dalı,  
İzmir, Turkey  
**Phone:** +90 533 723 16 26  
**E-mail:** gokselturhal@gmail.com  
**Received Date:** 21.05.2014  
**Accepted Date:** 18.08.2014  
**Available Online Date/Çevrimiçi Yayın Tarihi:**  
14.11.2014

© Copyright 2015 by Official Journal of the Turkish Society of Otorhinolaryngology and Head and Neck Surgery Available online at [www.turkarchotorhinolaryngol.org](http://www.turkarchotorhinolaryngol.org)  
© Telif Hakkı 2015 Türk Kulak Burun Boğaz ve Baş Boyun Cerrahisi Derneği Makale metnine [www.turkarchotorhinolaryngol.org](http://www.turkarchotorhinolaryngol.org) web sayfasından ulaşılabilir.  
DOI:10.5152/tao.2014.629

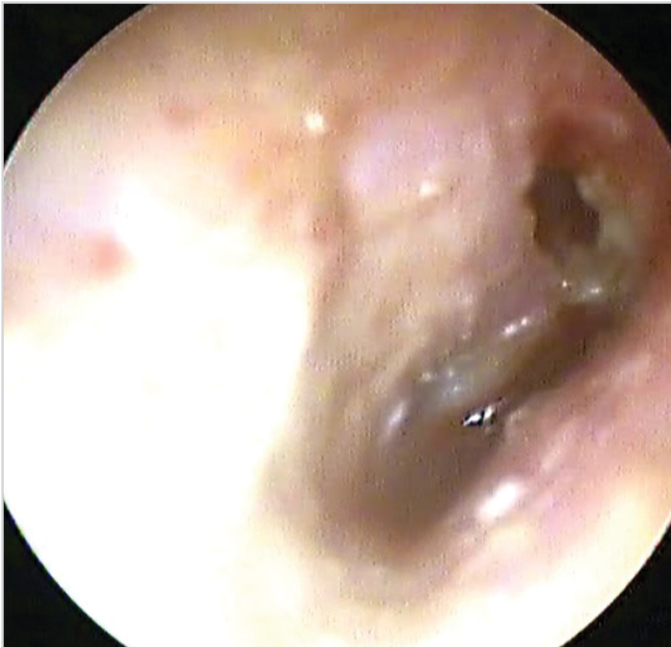

Figure 1. Acute exacerbation of chronic otitis. In the endoscopic view of the patient's ear, the middle ear is seriously edematous and draining

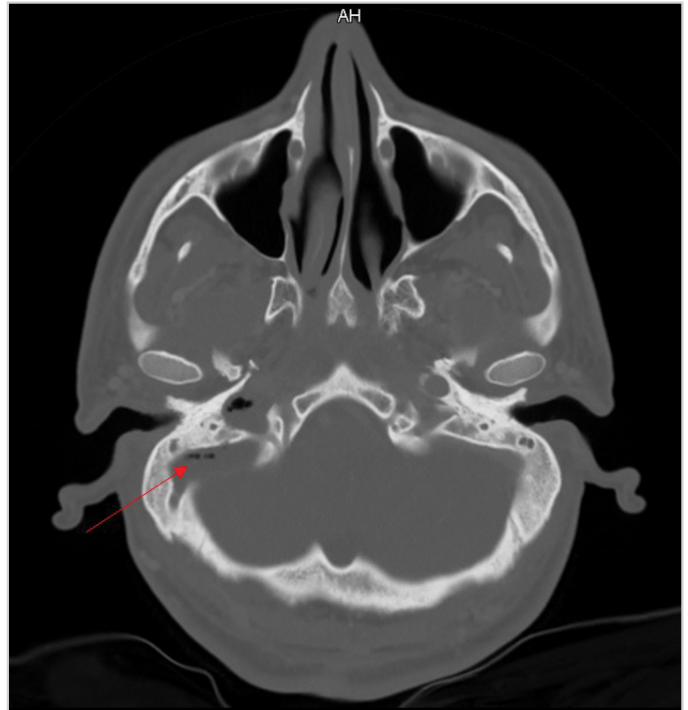


Figure 3. The red arrow shows air densities in the right sigmoid sinus

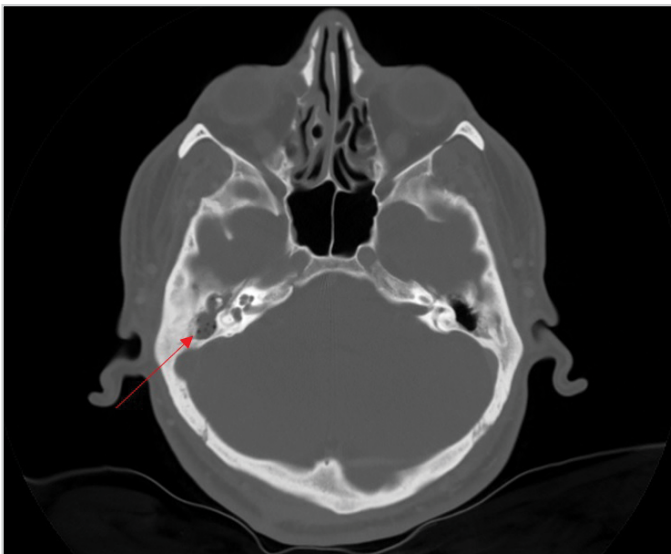


Figure 2. The red arrow shows otomastoiditis in the cavity of the right middle ear

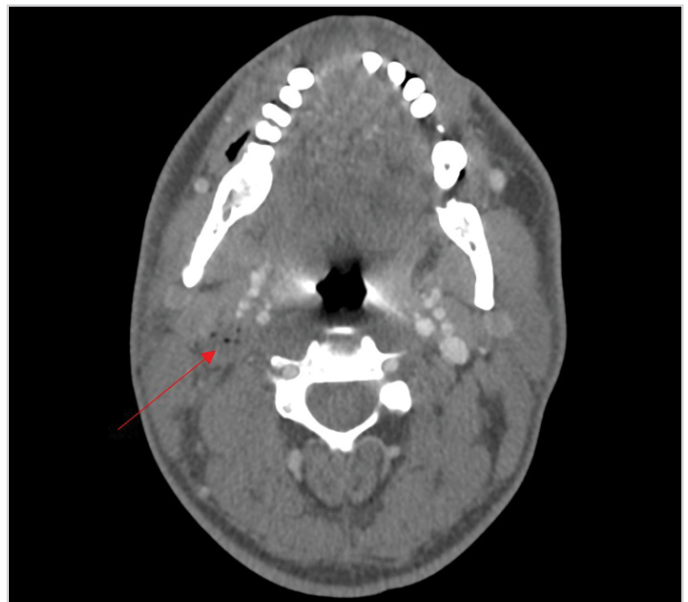

Figure 4. The red arrow shows air densities with thrombosed appearance in the right internal jugular vein in the contrast-enhanced CT angiography of the neck.

dration was initiated in addition to medical treatment and antibiotherapy during intensive care conditions. Blood culture was taken and 4x2.25-g piperacillin/tazobactam and 400-mg teicoplanin therapy was initiated in accordance with the advice of the Department of Infectious Diseases. Furthermore, topical ciprofloxacin therapy was initiated for the right draining ear of the patient. Methicillin-resistant coagulase-negative *Staphylococcus* and *Parvimonas micra* grew in the blood cultures of the patient. Because increased body temperature was observed during the follow-up of the patient, teicoplanin therapy

was switched to daptomycin therapy. No significant pathology was found in the bone marrow biopsy performed for pancytopenia. During the follow-up period, his fever regressed, and arterial tensions and creatinine levels returned to normal. In his control chest radiograph, it was observed that his parenchymal infiltrations regressed. Because the patient responded to the medical treatment and had no intracranial abscess, the elective surgery was planned. After the general health status of

the patient improved, he was transferred to the Department of Otorhinolaryngology. The operation was planned with the consideration of mastoiditis due to acute otitis media, but cholesteatoma was detected during the surgery. Thereafter, the patient underwent an open cavity tympanomastoidectomy. Piperacillin/tazobactam therapy was continued to be administered for 7 days after the operation. During his follow-up, his infection was observed to be recovered completely. The patient was discharged with a prescription of oral amoxicillin/clavulanic acid therapy for 2 weeks. During his treatment, he was not administered anticoagulant therapy. Moreover, all necessary written informed consents for both treatment and study were obtained from the patient.

## Discussion

While most of the patients are aged between 16 and 25 years, Lemierre's syndrome can be seen in both younger and older patients. Most patients affected by this disease are the individuals without a history of a previous health problem. While, in the etiology of Lemierre's syndrome, *F. necrophorum* (81.7%) is the most common causative bacteria, many organisms, such as *Bacteroides*, *Eikenella*, *Porphyromonas*, *Prevotella*, *Proteus*, *Streptococcus*, *Peptostreptococcus* and *Staphylococcus aureus*, have also been isolated. In 12.8% of the cases, the cultures were found to be negative (2).

The clinical findings of patients develop depending on the primary site of infection. Because pharyngitis patients constitute most of the cases, sore throat is the first sign in many patients. In addition, fever, neck swelling, dyspnea, and hemoptysis associated with pulmonary involvement as well as muscle and joint pain can be included in the classical clinical diagnosis (3). Infection spreads frequently from the primary site of palatine tonsils and the pharynx and then from the middle ear, paranasal sinuses, or the parotid gland to the lateral pharyngeal area, including IJV, and it causes septic thrombophlebitis. Septic thrombophlebitis leads to septic embolization in distal regions. As a result of this, multi-organ involvement occurs that mostly affects the lungs (97%) (4). Therefore, patients should be evaluated as a whole, and they should be evaluated and treated rapidly in the presence of warning features reminding multi-organ involvement, such as lung and sepsis, as in this case.

The diagnosis of Lemierre's syndrome is established through the demonstration of IJV thrombosis and positive blood culture. The contrast-enhanced CT of the neck region is the imaging technique that should be preferred for demonstrating thrombus. In our case, IJV and sigmoid sinus thrombus was shown by CT. Bedside Doppler USG is an alternative to CT. However, al-

though this technique is less invasive, it is less sensitive in deeper areas under the clavicle and mandibula (5).

Treatment requires long-term use of antibiotics (3–6 weeks) including  $\beta$ -lactamase inhibitors covering *F. necrophorum* and oral streptococci as well as surgical drainage may be necessary for some cases. Although the effect of anticoagulation is unclear, it is generally not indicated unless there is expansion of the thrombus. The ligation of IJV is indicated only in uncontrolled sepsis cases and continual septic emboli despite the use of antibiotics (5). When infection reaches IJV, hematogenous spread can occur and various complications can develop. These complications include central nervous system complications such as cavernous sinus thrombosis, meningitis, brain abscess, liver abscess, osteomyelitis, septic arthritis, pleural effusion, empyema, lung abscess, septic pulmonary emboli, soft tissue abscesses, cutaneous pustules, and septic shock. Unless the diagnosis is rapidly established and antibiotherapy is initiated, these complications may inevitably result in death (6).

## Conclusion

Lemierre's syndrome is described as a rare disease accompanied by fever, neck swelling, sore throat, pulmonary involvement, and arthralgia symptoms, which often affects healthy and young adults. In this study, a patient with Lemierre's syndrome secondary to chronic otitis complication was presented. Although the initial clinical diagnosis can be mild and atypical, Lemierre's syndrome should be kept in mind for its early and accurate diagnosis.

**Informed Consent:** Written informed consent was obtained from the patient.

**Peer-review:** Externally peer-reviewed.

**Author Contributions:** Concept - S.G., G.T.; Design - G.T., S.G.; Supervision - C.B., T.K.; Funding - C.B., T.K.; Materials - S.G., K.Ö.; Data Collection and/or Processing - G.T., K.Ö.; Analysis and/or Interpretation - K.Ö., C.B.; Literature Review - G.T., S.G.; Writing - G.T., S.G.; Critical Review - K.Ö., T.K.; Other - G.T., S.G.

**Conflict of Interest:** No conflict of interest was declared by the authors.

**Financial Disclosure:** The authors declared that this study has received no financial support.

## References

1. M Baig, J Rasheed, D Subkowitz, J Vieira. A Review Of Lemierre Syndrome. Int J Infect Dis 2005; 5: 2.
2. Chirinos JA, Lichtstein DM, Garcia J, Tamariz LJ. The evolution of Lemierre syndrome: report of 2 cases and review of the literature. Medicine (Baltimore) 2002; 81: 458-65. [CrossRef]

3. Kuppalli K, Livorsi D, Talati NJ, Osborn M. Lemierre's syndrome due to *Fusobacterium necrophorum*. Lancet Infect Dis 2012; 12: 808-15. [\[CrossRef\]](#)
4. Lustig LR, Cusick BC, Cheung SW, Lee KC. Lemierre's syndrome: Two cases of postanginal sepsis. Otolaryngol Head Neck Surg 1995; 112: 767-72. [\[CrossRef\]](#)
5. Golpe R, Marín B, Alonso M. Lemierre's syndrome (necrobacillosis) Postgrad Med J 1999; 75: 141-4. [\[CrossRef\]](#)
6. Riordan T. Human infection with *Fusobacterium necrophorum* (Necrobacillosis), with a focus on Lemierre's syndrome Clin Microbiol Rev 2007; 20: 622-65. [\[CrossRef\]](#)