

Radiation Induced Sarcoma of Hypopharynx: A Case Report

Case Report

Alper Dilci¹, Barış Karakullukçu², Bing Tan²

¹Department of Otorhinolaryngology and Head and Neck Surgery, Faculty of Medicine, Gazi University, Ankara, Turkey

²Clinic of Head and Neck Surgical Oncology, The Netherlands Cancer Institute-Antoni van Leeuwenhoek Hospital, Amsterdam, Netherlands

Abstract

Radiation-induced sarcoma in the head and neck is a long term rare complication of radiation therapy. The incidence of these sarcomas is, however, likely to increase due to progressive aging of the population combined with improved survival in head and neck cancer patients resulting from better treatment regimes. Diagnosis and management of this problem can be extremely challenging and the overall prognosis of radiation-induced sarcoma is worse than other types of sarcomas at a similar stage. Because of the proximity to vital structures and

multifocality, management can be extremely difficult in many cases. This is the case of post radiation sarcoma of the hypopharynx radiated for supraglottic laryngeal carcinoma previously. Here, we wish to share the diagnosis and management strategy in these types of late complications after radiation.

Key Words: Radiotherapy, radiation induced, sarcoma, hypopharynx

Introduction

Radiotherapy is the standard treatment modality for malignant tumors, and 60% of patients need radiotherapy for radical treatment and palliation (1). Radiation induced sarcomas are rare, arising in 0.035-0.2% of all irradiated patients, and represent less than 5% of all sarcomas (2). By definition, these tumors arise in previously irradiated area, histologically different from the originally treated tumor, no evidence of the sarcoma at the time of diagnosis of primary tumor and there is at least a 4 year interval between radiation therapy and sarcoma (3).

Radiation-induced sarcoma in the head and neck is a long term complication of radiotherapy. Diagnosis and management of these sarcomas also pose special problems because of the low incidence. The overall prognosis of radiation-induced sarcoma is worse than other types of sarcomas at a similar stage. The incidence of radiation induced sarcoma of the head and neck is likely to increase because of the ageing population combined with the improved survival rates of head and neck cancer (4). Surgery is the standard treatment for radiation induced sarcoma of the head and neck (5). However, complete resection of the lesion is very difficult because of the proximity of vital organs and multifocality of tumors. The tumor is insensitive to radiation and chemotherapy so incomplete resection of tumor results in a much worse prognosis (6).

Here, we report a case of post-radiation sarcoma of the hypopharynx; he was treated for T2N0M0 supraglottic laryngeal carcinoma with curative radiotherapy 8 years previously. Because of the rarity and difficulties of management of these tumors, we describe the diagnosis and treatment strategy of this patient.

Case Report

This report is concerned with the post radiation sarcoma of the hypopharynx after the definitive treatment of supraglottic carcinoma with radiotherapy. Written informed consent was also obtained from the patient who participated in this case report.

The patient is an 55 year old-man who was seen with hoarseness, left otalgia and sore throat in March 2004. He had Behcet's disease, obstructive sleep apnea with continuous positive airway pressure (CPAP)



Address for Correspondence:

Alper Dilci, Department of Otorhinolaryngology and Head and Neck Surgery, Faculty of Medicine, Gazi University, Ankara, Turkey
Phone: +90 312 202 64 26
E-mail: alperdilci@yahoo.com

Received Date: 23.04.2013

Accepted Date: 26.07.2013

© Copyright 2013 by Official Journal of the Turkish Society of Otorhinolaryngology and Head and Neck Surgery Available online at
www.turkarchotolaryngol.net
doi:10.5152/tao.2013.1326

and hypertension also. He had smoked for 40 pack years. Under examination of fiberoptic flexible endoscopy, an ulcerative lesion at the laryngeal side of epiglottis was diagnosed. The remainder of the larynx and pharynx was normal and there was no adenopathy in the neck. Ultrasound guided biopsy was taken from level 2 nodes on both sides and it was clear of tumor cells. He was examined under general anesthesia and the biopsy showed squamous cell carcinoma and the tumor stage was T2N0M0 (American Joint Committee on Cancer, AJCC, stage II).

The patient was treated with radiation therapy on the larynx and the lymph node level 2 and 3 in the neck on both sides to a dose of 46Gy in 23 fractions during 6 weeks. The surdosage on the tumor process in the larynx was up to 70Gy. The radiation treatment protocol was applied according to the Danish Head and Neck Cancer Study (DAHANCA) scheme with Computed Tomography (CT) planned Intensity-Modulated Radiation Therapy (IMRT). After curative radiotherapy there was complete remission and no evidence of tumor activity.

Routine follow up examinations showed that the patient remained disease-free for 8 years (Figure 1). In May 2012, the patient was admitted with difficulty in swallowing and total passage disorder. He also had had a sore throat for two months. A complete work up was performed and a tumor was diagnosed in the post cricoid region. On the neck CT there was a large exophytic hypopharyngeal mass occluding the proximal esophagus. There was a large homogenously intense stained mass from the tip of the epiglottis to the top of the cricoid, probably attached by a stalk to the lower hypopharynx or proximal esophagus on the neck Magnetic Resonance Imaging (MRI) (Figure 2). Pathological Positron Emission tomography (PET) activity (SUV max: 9.3) was noted on the hypopharyngeal region on PET scan, which relates to tumor recurrence with no evidence of distant metastases (Figure 3). The patient was examined under general anesthesia and a biopsy was taken from the tumor arising from the postcricoid area. The biopsy showed tumor positive, dated postradiation sarcoma or sarcomatoid carcinoma.

In June 2012, total laryngectomy, partial pharyngectomy and pectoralis major flap was performed. The tumor was approximately 5 cm in size and pedunculated from the posterior wall of hypopharynx. The larynx had no contact with tumor, it was attached by a stalk from the posterior wall of hypopharynx and obstructed the whole passage (Figure 4a, b). The tumor was resected with clear margin together with a segment of pharynx. The specimen was examined pathologically and measured 6.2 cm in size; grade 2 postradiation sarcoma (according to FN-CLCC grading system) was reported (Figure 5). There were no abnormalities during the recovery period and the patient was discharged from the clinic on the 7th day. There was no need for adjuvant therapy and in the first 6 months of follow up there was no evidence of tumor.

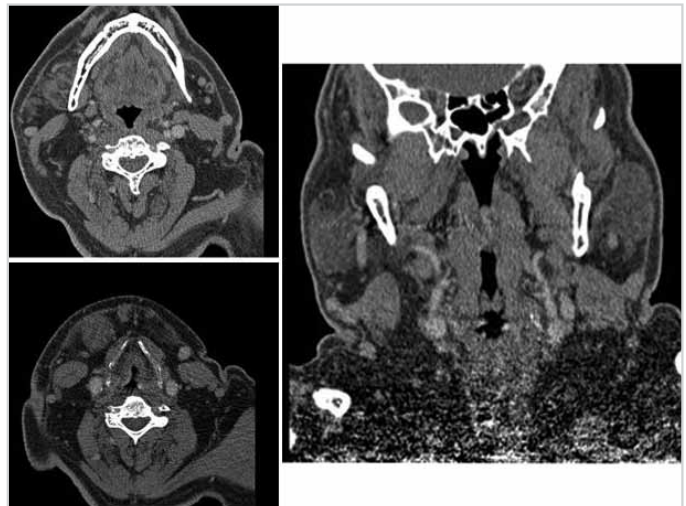


Figure 1. CT images of patient in fifth year after primary radiotherapy during routine follow up
CT: computed tomography

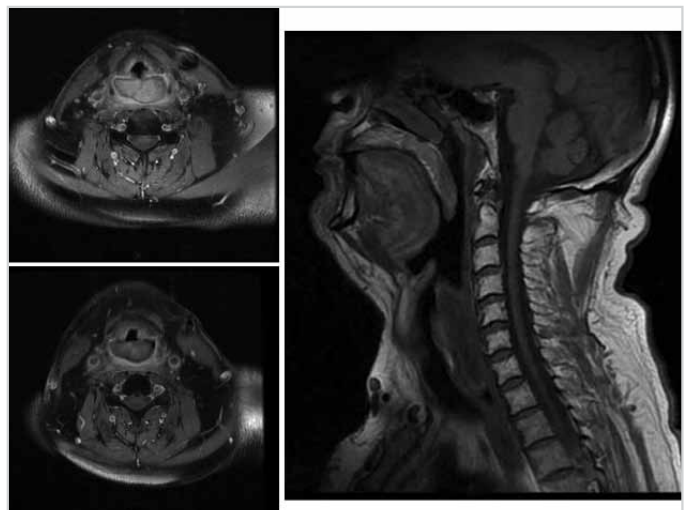


Figure 2. MRI images of patient in eighth year with the vegetative tumor on the hypopharynx
MRI: magnetic resonance imaging

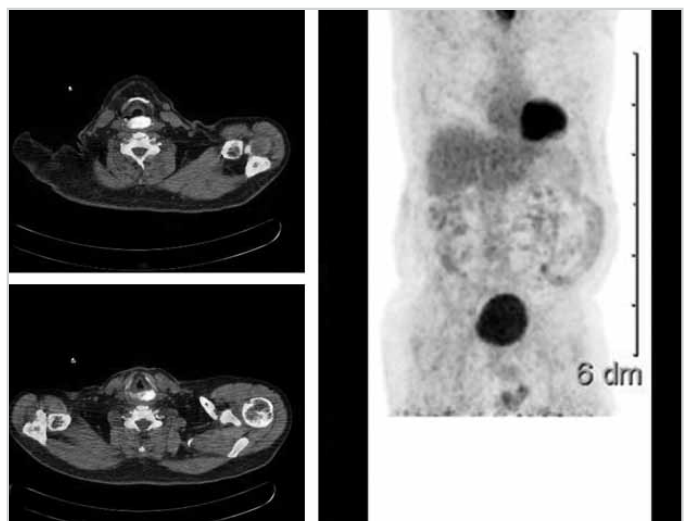


Figure 3. PET -CT images of patient with the vegetative tumor on the hypopharynx, distant metastases could not be seen
PET-CT: position emission tomography

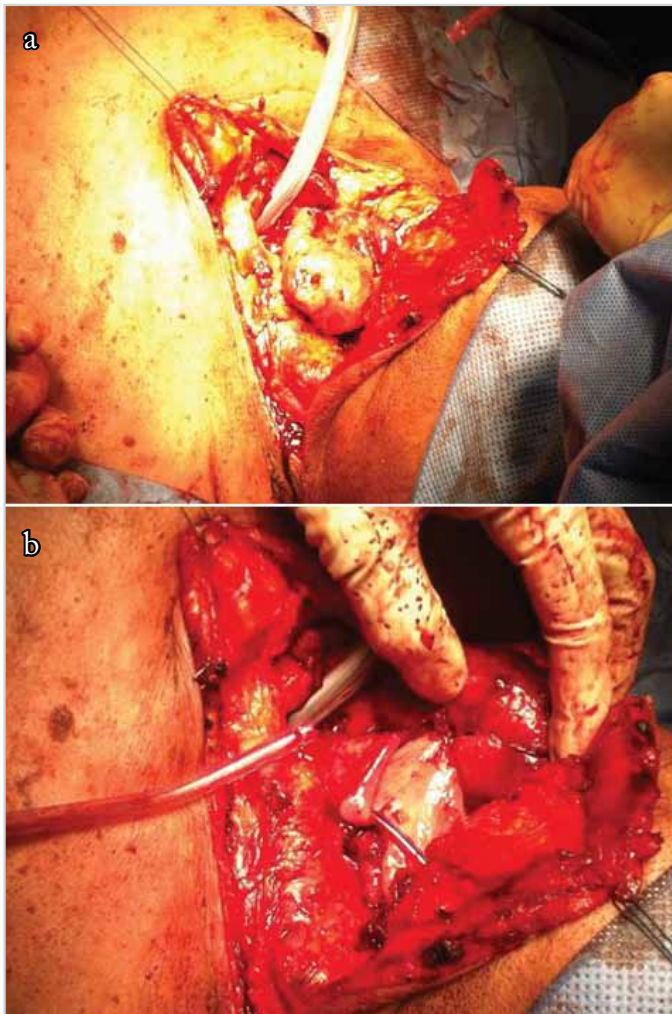


Figure 4. Large mass of tumor with a stalk from hypopharynx can be seen intraoperatively (a), tumor is connected by a stalk from the hypopharynx and the whole lumen is occluded by the tumor (b).

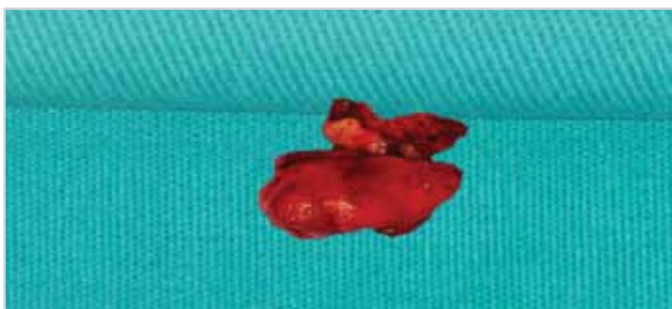


Figure 5. Pathological specimen resected from hypopharynx with clear margin

Discussion

Practically all types of cancer can be induced by irradiation, but the skin and thyroid are the most commonly involved tissues within the head and neck. Although radiation induced sarcoma is a well-recognized long term complication of radiation therapy for other sites, the head and neck are less commonly affected (7, 8).

Radiation induced sarcomas of the head and neck can occur after treatment for a variety of lesions of the head and neck, and intracranial compartment. These tumors may occur a long time after radiotherapy and are clinically aggressive lesions. Radiation induced sarcoma is a unique and rare malignant tumor; incidence is about 0.03 to 0.8% (9). It was considered that part of the reason for the low incidence in the head and neck is the higher mortality rate of head and neck cancers. However, this low incidence is probably increasing and radiation induced sarcomas are likely to be more frequent. Wei et al. (10) report that the incidence of radiation induced sarcomas of head and neck after radiotherapy between 1960 and 1989 is 0.06%. Between 1990 and 2010 this incidence is 0.17% compared to former times, indicating a possible increase in radiation induced sarcomas of head and neck.

One report showed that radiation induced sarcoma is the most frequent histologic type of second primary malignancy after radiotherapy (11). There were also other reports which showed that squamous cell carcinoma is the most frequent malignancy after radiation (9).

Post radiation sarcomas of the head and neck indicate a poor outcome. Mark et al. (12) reported a 5 year disease-free survival of only 8%. Patel reported that 5 year survival rate of post radiation sarcomas of head and neck was worse than other sarcomas of the head and neck (2). Reasons for this poor prognosis are related to: a delay in diagnosis because of local post-radiational changes, proximity of major structures of neck limiting the surgical resection, the dangers of reirradiation of the primary area, insensitivity of tumors to chemotherapy and host immunosuppression caused by the first tumor and treatment.

The clinical diagnosis of post radiation sarcomas can be difficult because of post-radiational changes of tissues. Detailed investigation based on the patient's symptoms during the intervals of follow up is very important for early detection. The tumor is insensitive to chemotherapy and radiotherapy, so surgery is believed to be the only effective method, but it is difficult to excise the lesion completely because the safe margin is not easily achieved and the tumor is also multifocal (6). Most of the post radiation sarcomas are diagnosed have extended beyond the local margins of their origin and are difficult to resect completely without causing unacceptable deformities. Because of the previous radiation, poor healing and wound complications are probable after surgery. In our case, total laryngectomy and partial pharyngectomy operation is adequate and because of early radiation pectoralis major flap was carried out for wound complications like fistula during rehabilitation.

Early diagnosis provides a chance for cure with wide-margin resection. To achieve this result, a complete work up must be done

during the follow up and give more detailed examinations according to patients' symptoms. Because of the previous radiation diagnosis is not very easy, so it must be strengthened with a radiologic work up. There is at present no prospect of effective prevention of post radiation sarcoma. An early diagnosis for these patients is the means for complete recovery with complete resection.

Conclusion

Radiation induced sarcomas of the head and neck may occur a long time after radiotherapy. Diagnosis and management of these tumors are difficult and they are clinically very aggressive. Although surgical management of these sarcomas is challenging because of the close proximity of the tumor to important regional structures and the technical difficulties of operating in an irradiated area, complete surgical excision appears to offer the best means for palliation and the only realistic chance for long-term survival. During the follow up of radiated patients, physicians need to be careful about long term complications of radiation such as these.

Conflict of Interest

No conflict of interest was declared by the authors.

Peer-review: Externally peer-reviewed.

Informed Consent: Written informed consent was obtained from patient who participated in this case.

Author Contributions

Concept - A.D., B.K.; Design - A.D.; Supervision - B.K., B.T.; Funding - A.D., B.K., B.T.; Materials - A.D.; Data Collection and/or Processing - A.D., B.A., B.T.; Analysis and/or Interpretation - A.D., B.K.; Literature Review - A.D., B.A., B.T.; Writer - A.D.; Critical Review - B.A., B.T.

References

1. Ravichandran R. Has the time come for doing away with cobalt-60 teletherapy for cancer treatments. *J Med Phys* 2009; 34: 63-5. [\[CrossRef\]](#)
2. Patel SG, See AC, Williamson PA, Archer DJ, Evans PH. Radiation induced sarcoma of the head and neck. *Head Neck* 1999; 21: 346-54. [\[CrossRef\]](#)
3. Debnam JM, Guha-Thakurta N, Mahfouz YM, Garden AS, Benjamin RS, Sturgis EM, et al. Radiation-associated head and neck sarcomas: spectrum of imaging findings. *Oral Oncol* 2012; 48: 155-61. [\[CrossRef\]](#)
4. Makimoto Y, Yamamoto S, Takano H, Motoori K, Ueda T, Kazama T, et al. Imaging findings of radiation-induced sarcoma of the head and neck. *Br J Radiol* 2007; 80: 790-7. [\[CrossRef\]](#)
5. Xi M, Liu MZ, Wang HX, Cai L, Zhang L, Xie CF, et al. Radiation-induced sarcoma in patients with nasopharyngeal carcinoma: a single-institution study. *Cancer* 2010; 116: 5479-86. [\[CrossRef\]](#)
6. Holt GE, Thomson AB, Griffin AM, Bell R, Wunder J, Rougraff B, et al. Multifocality and multifocal postradiation sarcomas. *Clin Orthop Relat Res* 2006; 450: 67-75. [\[CrossRef\]](#)
7. Ron E, Modan B, Preston D, Alfandry E, Stovall M, Boice JD Jr. Radiation induced skin carcinomas of the head and neck. *Radiat Res* 1991; 125: 318-25. [\[CrossRef\]](#)
8. Fleming ID, Black TL, Thompson EI, Pratt C, Rao B, Hustu O. Thyroid dysfunction and neoplasia in children receiving neck irradiation for cancer. *Cancer* 1985; 55: 1190-4. [\[CrossRef\]](#)
9. Mark RJ, Poen J, Tran LM, Fu YS, Selchs MT, Parker RG. Postirradiation sarcomas. A single - institution study and review of the literature. *Cancer* 1994; 73: 2653-62. [\[CrossRef\]](#)
10. Wei Z, Xie Y, Xu J, Luo Y, Chen F, Yang Y, et al. Radiation induced sarcoma of head and neck: 50 years of experience at a single institution in an endemic area of nasopharyngeal carcinoma in China. *Med Oncol* 2012; 29: 670-6. [\[CrossRef\]](#)
11. Sale KA, Wallace DI, Girod DA, Tsue TT. Radiation-induced malignancy of the head and neck. *Otolaryngol Head Neck Surg* 2004; 131: 643-5. [\[CrossRef\]](#)
12. Mark RJ, Bailet JW, Poen J, Tran LM, Calcaterra TC, Abemayor E, et al. Postirradiation sarcoma of the head and neck. *Cancer* 1993; 72: 887-93. [\[CrossRef\]](#)