

# Giant Mucocele of the Maxillary Antrum: Report of a Case

M. Özcan, Ö. Akdoğan, T. Gün

## Dev Maksiller Antral Mukosel: Olgu Sunumu

Mukoseller paranasal sinüslerin benign ve lokal olarak genişleyen kitleleridir. En sık frontal ve etmoid sinüsleri tutarlar. Agresif mukoseller sinüs duvarlarını erode edebilirler ve bunlar kar-sinomalardan ayrılmalıdır. Kemik destrüksiyonuna yol açan dev maksiller antral mukoseller daha önce nazal veya sinüs cerrahisi geçirmemiş hastalarda çok nadirdir. Tanıda kompüterize tomografi en önemli araçtır. Maksiller antral mukosellerin tedavisi cerrahidir. Geleneksel yaklaşım kist duvarını tamamen eksi-ze ederek yapılan eksternal yaklaşımdır. Endoskopik tedavi de bildirilmiştir, ancak bu yaklaşım genellikle maksiler sinüs sınırları dışına çıkmayan mukoseller için saklanır. Burada daha önce nazal veya sinüs cerrahisi öyküsü olmayan bir hastada fasiyal asimetriye yol açan dev bir maksiller antral mukosel olgusu sunulmuştur. Hastalığın görüntüleme metodları ve cerrahi tedavi seçenekleri sunulmuş ve literatür gözden geçirilmiştir.

**Anahtar Sözcükler:** Mukosel, maksiller antrum.

## Abstract

Mucoceles are benign locally expansive masses of the paranasal sinuses. They most commonly affect the frontal and ethmoid sinuses. Aggressive mucoceles may erode the surrounding walls of the sinus and they must be differentiated from the carcinomas. Giant maxillary antral mucoceles causing bone destruction are extremely rare in patients who have no previous history of nasal or sinus surgery. Computed tomography is the most important tool for the diagnosis of the disease. The treatment of maxillary antral mucoceles is surgical. The traditional method is external approach, with complete excision of the cyst wall. Endoscopic treatment is usually reserved for mucoceles that do not extend beyond the limits of the maxillary sinus. We report a case with a giant maxillary antral mucocele that caused facial asymmetry in a patient with no history of previous nasal or sinus surgery. The imaging methods and surgical treatment options of the disease is presented and the literature is reviewed.

**Key Words:** Mucocele, maxillary antrum.

Türk Otolarengoloji Arşivi, 2002; 40(2): 150-152

Turk Arch Otolaryngol, 2002; 40(2): 150-152

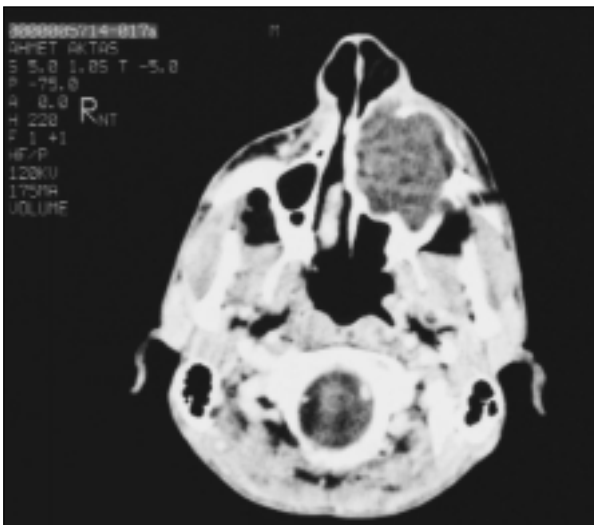
## Introduction

Mucoceles most commonly affect the frontal and ethmoid sinuses. Giant maxillary antral mucoceles causing bone destruction are extremely rare in patients who do not have the history of previous nasal surgery.<sup>1</sup> In this report, a case with a large maxillary antral mucocele causing facial asymmetry and bone erosion is presented, and the literature is reviewed.

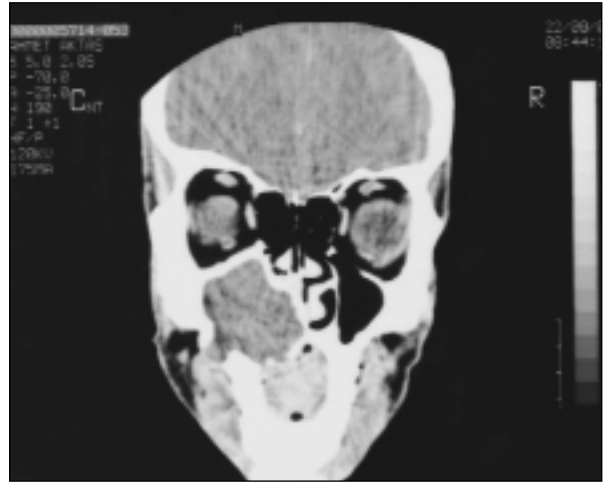
### Case Report

A 28 year-old male presented with painless swelling on his left cheek, headache and nasal obstruction. The patient did not have history of nasal or sinus surgery. Otolaryngological examination revealed a firm swelling over the left maxilla causing facial asymmetry. Medial bulging of left lateral nasal wall was evident on anterior rhinoscopy. Bulging of the left gingivobuccal sulcus and left side of the hard palate was seen on examination. There were no masses or lymphadenopathies on palpation of the neck. Waters' and Caldwell views showed complete opacity of left maxillary antrum. A cystic lesion that caused erosion of anterior, lateral and inferior walls of maxillary sinus as well as inferior turbinate was seen on computed tomography (CT) (Figure 1,2). No enhancement was noted following intravenous contrast administration.

A Caldwell-Luc procedure with the antrostomy on the inferior meatal wall was performed and yellowish fluid of the mucocele was aspirated. The capsule of the mucocele was carefully removed. The symptoms of headache and nasal obstruction improved. The facial asymmetry remained almost unchanged. The antrostomy was patent and no recurrence was evident 3 months after the surgery.



**Figure 1.** The axial CT view of the maxillary mucocele demonstrating facial asymmetry and bony defect of anterior antral wall.



**Figure 2.** The coronal view of the computed tomography. Note inferior and lateral bony erosions of the maxillary sinus wall.

### Discussion

Mucoceles are benign locally expansive masses with mucoperiosteal lining and are filled with mucus. It is suggested that the most common cause was infection, followed by trauma and previous surgical intervention.<sup>1</sup> Tumors and cystic degeneration of the mucosa were the other factors that were accused in the etiopathogenesis. Aggressive mucoceles causing erosion of the surrounding bone, nasal obstruction and facial asymmetry can be misdiagnosed as carcinomas.

Histologically, mucoceles are divided as primary or secondary. Primary ones are inaccurately referred to as mucoceles and in fact they are mucus retention cysts. Secondary ones are "true" mucoceles and are lined by pseudostratified columnar epithelium and occur when the communication between nose and the sinus is obstructed. Accumulated mucus and desquamated epithelium in the sinus under pressure may cause expansion of the sinus wall leading to bone erosion.<sup>2</sup>

Two thirds of mucoceles occur in the frontal sinuses and one third in the ethmoid sinuses. Maxillary and sphenoid mucoceles are rare.<sup>3</sup> Prevalence of maxillary mucoceles differ from region to region. Natwig and Larsen reported 3 maxillary mucoceles in their series of 112 patients (2.7%).<sup>4</sup> Lund reported only one percent involvement of maxillary sinus among 118 patients with mucoceles.<sup>5</sup> Som and

Shugar reported a prevalence of 10% for maxillary mucoceles.<sup>6</sup> Despite these low prevalence in Europe, large series of maxillary mucoceles have been reported in Japan in patients with previous Caldwell-Luc surgery.<sup>7,8</sup>

Symptoms of maxillary mucoceles may be facial pain, swelling and numbness of the cheek, diplopia, and dental problems. Patients usually have a history of previous sinus surgery. Radiological examination and surgical exploration may aid in the diagnosis. CT is the most important tool for the diagnosis. Maxillary mucoceles appear as homogenous masses with smooth margins, and are isodense with the brain. No enhancement were seen after intravenous contrast injection. Smooth and clear-cut margins are important for differentiation from the malignancies. Our patient had the typical appearance of a mucocele in the CT. Irregular shape of the mass and the destruction of the sinus walls rather than erosion might alert the surgeon for the presence of malignancy.<sup>9</sup> Neurofibromas, dermoid and epidermoid cysts, cementifying osseous fibromas, cylindrinomas, inverting papillomas, and angiofibromas may expand the sinus wall as mucoceles do and they must be included in the radiological differential diagnosis.<sup>9</sup>

Caldwell-Luc approach and inferior meatal antrostomy are the traditional methods for the treatment of maxillary mucoceles. The cyst is completely removed through the anterior antral window or via the lateral rhinotomy approach. Endoscopic management of ethmoidal and frontal mucoceles has been advocated by a number of authors in recent years.<sup>10</sup> However, endoscopic approach is usually reserved for mucoceles that do not extend beyond the limits of maxillary sinus.<sup>1</sup> It is suggested that mucoceles causing bone erosion and extending into the soft tissues of the cheek or the orbit may collapse after the drainage, trapping extrasinus extension, and this may result in subsequent recurrence. In these cases, an open approach may be prefer-

red.<sup>1</sup> The maxillary mucocele has extended into the cheek in our patient and we preferred the open approach and complete removal of the wall of the mucocele. The entire sinus was visible endoscopically through the inferior antrostomy in the postoperative period. The endoscopic control and irrigation of the maxillary sinus were performed through the inferior antrostomy. The patient did not have any recurrence after 3 months following the surgery.

In conclusion, maxillary antral mucoceles that caused bone erosion is extremely rare in patients with no previous history of surgery. The surgical treatment of maxillary mucoceles may be the complete removal of the wall of the mucocele through the Caldwell-Luc procedure. The endoscopic follow up of the patient may be performed through inferior meatal antrostomy. Long term follow up of the patient for the recurrence is advocated.

#### References

1. Marks SC, Latoni JD, Mathog RH. Mucoceles of the maxillary sinus. *Otolaryngol Head Neck Surg* 1997; 117(1): 18-21.
2. Gardner DG, Gullane PJ. Mucoceles of the maxillary sinus. *Oral Surg Oral Med Oral Pathol* 1986; 62(5): 538-43.
3. Zizmor J, Noyek AM. Cysts, benign tumors, and malignant tumors of the paranasal sinuses. *Otolaryngol Clin North Am* 1973; 6(2): 487-508.
4. Natvig K, Larsen TE. Mucocele of the paranasal sinuses. A retrospective clinical, and histological study. *J Laryngol Otol* 1978; 92(12): 1075-82.
5. Lund VJ. Endoscopic management of paranasal mucoceles. *J Laryngol Otol* 1998; 112(1): 36-40.
6. Som PM, Shugar JM. Antral mucoceles: a new look. *J Comput Assist Tomogr* 1980; 4(4): 484-8.
7. Hasegawa M, Saito Y, Watanabe I, Kern EB. Postoperative mucoceles of the maxillary sinus. *Rhinology* 1979; 17(4): 253-6.
8. Kaneshiro S, Nakajima T, Yoshikawa Y, Iwasari H, Tokiwa N. The postoperative maxillary cyst: report of 71 cases. *J Oral Surg* 1981; 39(3): 191-8.
9. Jayaraj SM, Patel SK, Ghufloor K, Frosh AC. Mucoceles of the maxillary sinus. *Int J Clin Pract* 1999; 53(5): 391-3.
10. Kennedy TL. Endoscopic surgery for frontal and ethmoid sinus mucoceles. *Am J Rhinol* 1994; 8(2): 107-12.

Correspondence: Müge Özcan, MD  
Yücecepe Sitesi A Blok 59/6  
Anıttepe 06580 ANKARA  
Tel: (0312) 479 43 90  
e-mail: mugeozcan@yahoo.com