

# The Fatal Complication of Emergency Tracheotomy

L. Sennaroğlu, İ. Haberal, K. Ayas, V. Çeliker

## Acil trakeotomide fatal komplikasyon

Bu makalede acil şartlarda açılan trakeotomi sonrası gelişen bilateral pnömotoraks olgusu sunulmuştur. Genel anestezi altında direkt laringoskopi planlanan hastaya, anestezinin indüksiyon fazında entübe edilememesi nedeniyle acil şartlarda trakeotomi açıldı. Takiben bilateral pnömotoraks gelişen hastada bilateral göğüs tüpü uygulanmasına rağmen akut respiratuvar distres sendromuna (ARDS) benzer bir tablo ve sepsis gelişti. Başlangıçta tedaviye cevap vermesine rağmen hasta 15. gün kardiopulmoner arrest ile kaybedildi. Bu olgu dolayısıyla acil trakeotominin komplikasyonları gözden geçirilmiştir.

**Anahtar Sözcükler:** Acil trakeotomi, bilateral pnömotoraks, reekspansiyon pulmoner ödem.

## Abstract

A case of bilateral pneumothorax following emergency tracheotomy is presented. Tracheotomy was performed in an emergency condition to a patient during induction phase of anaesthesia for direct laryngoscopy because of difficulty in intubation. After that bilateral pneumothorax were developed. In spite of bilateral chest tubes, acute respiratory distress syndrome (ARDS) like condition and sepsis developed. After the initial response to the therapy the patient was lost on the fifteenth day because of cardiopulmonary arrest. Because of this case the complications of emergency tracheotomy were reviewed.

**Key Words:** Emergency tracheotomy, bilateral pneumothorax, reexpansion pulmonary edema.

Türk Otolarengoloji Arşivi, 2004; 42(3): 176-180

Turk Arch Otolaryngol, 2004; 42(3): 176-180

## Introduction

Complications of tracheotomy frequently result from improper execution of the procedure or inadequate postoperative care of the tracheotomized patient. Most retrospective studies have addressed the incidence of overall complications, ranging from 5% to 40%.<sup>1-5</sup> Representative studies suggest an overall complication rate approaching to 15 %, with the most common of them being haemorrhage (3.7%), tube obstruction (2.7%) or tube displacement (1.5%). Pneumothorax, atelectasis, aspiration, tracheal stenosis and tracheoesophageal fistula occur with less than one per cent frequency each. Death occurs in 0.5-1.6% of cases and is most often

Levent Sennaroğlu, MD; İlknur Haberal, MD; Kıvanç Ayas, MD  
Hacettepe University, Medical Faculty, Department of Otolaryngology Head and Neck Surgery, Ankara

Varol Çeliker, MD  
Hacettepe University, Medical Faculty, Department of Anaesthesiology and Reanimation, Ankara

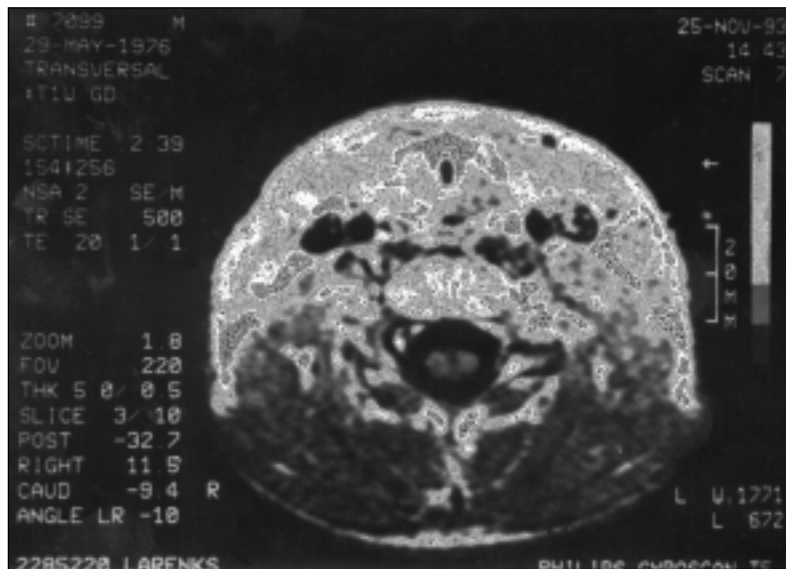
caused by haemorrhage or inadvertent tube displacement. Moreover, emergency tracheotomy carries a two to five fold increase in the incidence of complications over an elective procedure.<sup>3,6</sup> In this article, a bilateral pneumothorax case that had developed after emergency tracheotomy was presented.

### Case Report

A 17-year-old patient was referred to our clinic from the paediatric allergy unit for dyspnea during exertion, hoarseness and dry cough that had persisted for about two years, especially increasing during night and winters. During ENT examination larynx could not be seen indirectly, because he could not tolerate this procedure. Although he was asymptomatic at rest, he was cyanotic and dyspneic with supraclavicular, subcostal retractions. He had stridor on exertion. MRI examination showed that the tracheal air column was markedly narrowed in the subglottic region between C6 and C7 vertebra levels and the thickness of the soft tissues surrounding subglottic airway was increased diffusely (Figure 1).

Direct laryngoscopy and bronchoscopy were planned for evaluation and dilation of the stenotic tracheal segment. After the induction of general anaesthesia the patient could not be intubated. Even the endotracheal tube of 3.5 mm diameter could not be passed through the subglottic region. The procedure was stopped at this stage, and he was tried to be oxygenated by mask. But peripheral oxygen saturation (SaO<sub>2</sub>) began to decrease and marked suprasternal, substernal, subcostal retractions started. At this stage, 250 mg prednisolon was given. In spite of this, the patient condition did not improve and SaO<sub>2</sub> decreased to 20 per cent. Emergency tracheotomy was performed. In spite of tracheotomy SaO<sub>2</sub> did not increase to satisfactory level. The chest radiograph taken in the operating room showed bilateral pneumothorax localized in the apical regions. On the right side it was equal to 15% and on the left lower than 10%. Bilateral chest tubes for intercostal suction drainage were inserted under general anaesthesia. When direct laryngoscopy was completed, subglottic annular stenosis was detected.

The postoperative radiograph showed bilateral lungs fully reexpanded but diffusely opaque. The



**Figure 1.** MRI scan showed the tracheal air column was markedly narrowed in the subglottic region and the thickness of the soft tissue surrounding subglottic airway was increased diffusely.

dyspnea failed to improve in spite of 100% oxygen. The oxygen saturation remained at 30-40%. He was connected to a ventilator and PEEP (positive end expiratory pressure) was performed. During the time he was connected to ventilator, he was given muscle relaxant and sedatives. With PEEP ventilation SaO<sub>2</sub> raised to normal level. When he was disconnected from the ventilator to breath spontaneously air enriched with oxygen, the SaO<sub>2</sub> fell immediately. Tracheal lavage showed active bleeding coming from the lower respiratory system. This bleeding continued for 2 days even though cuff was inflated. On the fourth day his temperature raised to 40°C, progressive hypotension and tachycardia developed. Because of aspiration pneumonia, ciprofloxacin was added to the previous therapy containing sulbactam-ampicillin, dexametason and ulcuran. After a week, his mental situation improved. His lungs fully reexpanded and chest tubes were removed. Because of pulmonary edema, fluid administration was restricted. His temperature was between 36-38°C. Subcutaneous emphysema all over the body developed. On the tenth day because of hypoxia and hypercapnia PEEP ventilation was started again. After one-day right pneumothorax was developed with almost total collapse of the lung, a chest tube for intercostal suction drainage was reinserted. During the following days his general condition was markedly improved. He was disconnected from the ventilator and he started to breath spontaneously with 4-6 lt/min. of oxygen day-out. During night he was connected to respirator again.

On the thirteenth day, he got unconscious again and 45 cc of purulent material was drained from the right chest tube. On the fifteenth day, he had cardiopulmonary arrest with no response to resuscitation. Because the permission of the family could not be obtained, no autopsy was performed on the patient.

## Discussion

Pneumothorax occurs in 0 to 5% of tracheotomies.<sup>6</sup> It may be caused by aggressive dissection off the midline, especially in children and patients with chronic lung diseases where pleural

apices can extend into the neck. Forceful and rapid ventilation of the patient, which often occurs in situations of respiratory decompensation, prevents the passive exhalation of air, leading to breath stacking and the eventual rupture of alveoli, producing the entrance of air into the pleural space. A misplaced tracheotomy tube also can cause air to enter the soft tissues of the mediastinum and pleural space. Pneumothorax causes decreased breath sounds and a hyperresonant chest wall, and can be confirmed by anteroposterior chest radiography. A pneumothorax smaller than 15% may require only observation by serial chest films. A large pneumothorax usually requires a thoracostomy tube. If a tension pneumothorax occurs, immediate pleural decompression is necessary to avoid potentially fatal depression of cardiac output.<sup>6</sup>

In this case, bilateral pneumothorax occurred after emergency tracheotomy. The possible explanation is that both cupulas were injured during the procedure. In spite of bilateral chest tubes the pre-existent dyspnea failed to improve. Although the control chest radiograph showed bilateral reexpansion of the lungs, they were diffusely opaque. The most possible causes of this type of opacity are pulmonary edema, bleeding or pneumonia.<sup>7</sup> Minor bleedings or oozing occurs in about 5% of cases according to Reilly and Sasaki.<sup>6</sup> The source is usually venous and involves anterior jugular system or thyroid isthmus and occurs near the stoma. But there may be severe haemorrhage from a branch of the superior thyroid artery and innominate artery very rarely.<sup>3</sup> However there was continuous active bleeding from the lower airway in our patient. In spite of inflated cuff, bleeding was coming through the tracheotomy canula. All these findings point to a parenchymal injury that is quite common during tube insertion if the pneumothorax is minute.

As he gave good response to 100% oxygen given by respirator, ARDS (acute respiratory distress syndrome) was not thought here as a differential diagnosis. ARDS is a descriptive term that has been applied to many acute, diffuse infiltrative lung lesions of diverse aetiologies when they are accompanied by severe arterial hypoxemia.

Reexpansion pulmonary edema (RPE) was another possible diagnosis. It seems to occur seldom, following intercostal suction drainage in the treatment of pneumo- or sero-thorax.<sup>8</sup> The actual incidence is probably unknown because many cases do not become clinically manifest in spite of radiographic signs of edema.<sup>9</sup> A relative lack of surfactant has been suggested as causative factor. This was supported by the fact that most RPE occurred after long standing total collapse of the lung, which might have impinged the surfactant production.<sup>10</sup> On the other hand, however, RPE also does develop after very short intervals of pulmonary collapse. A high speed of reexpansion following insertion of the intercostal tubes has also been accused to be causative for formation of RPE. Minimal capillary leakage together with lack of surfactant and negative pressure forming suddenly in the alveoli might enhance the inflow of fluid from the capillaries. Though the above-mentioned factors may play a certain role, RPE is probably a reoxygenation injury with the lung tissue producing excess superoxide and other toxic metabolites.<sup>11,12</sup> From the clinical point of view, severe RPE is a serious complication, as 20% have a lethal outcome. This is mainly due to pitfalls in the diagnosis: aspiration, residual intrapleural fluid and pneumonic infiltrate are the most common radiological misinterpretations of the homogeneous opacity forming in the reexpanded lung. Clinically and unexplained hypovolemic shock is the first striking feature. Subsequently, all signs of an ARDS develop in spite of the unilaterality of the process.<sup>11</sup> If RPE is not diagnosed early enough, the resulting hypoxemia increases the damage to the oedematous lung and may even result in the irreversible bilateral ARDS and multi-organ failure.

In certain situations, relieving airway obstruction itself can cause fatal respiratory depression. In the patient suffering from chronic upper respiratory obstruction as in this case, tracheotomy can cause a sudden loss of the hypoxic stimulation to which chemoreceptors have acclimated, leading to a loss of ventilatory drive. Ventilatory assistance may be required temporarily until chemoreceptors are reset to a lower level of PCO<sub>2</sub>. Also the sudden

relief of upper airway obstruction may cause the sudden onset of pulmonary edema. The mechanism is incompletely understood but is thought to involve a rapid change in capillary- alveolar transmural pressure gradients and a catechol- mediated shift in pulmonary blood volume leading to a rapid egress of fluid out of the pulmonary capillary bed. Initially PEEP was not used because he had still pneumothorax and after which pneumothorax could be developed again.

One of the complications, which were seen in this patient, was subcutaneous emphysema.<sup>3</sup> It results when air that normally escapes around cannula is forced into loose facial planes. It most often results from closing the wound too tightly. In this patient, because artificial respiration was needed, the wound was not closed and cannula's cuff was deflated regularly. During deflation, he was disconnected from respirator to prevent the air forced into subcutaneous tissue. The air in the subcutaneous tissue was emptied by massage and sometimes by needle aspiration. The subcutaneous emphysema, which was in the neck, face anterior chest wall, scrotum and abdominal wall, was almost totally treated by this way.

Another complication was aspiration pneumonia and sepsis. The haemorrhage provided blood in the lungs, which is an excellent medium for the microorganisms. All kinds of infection sources such as tracheotomy cannula, bilateral chest tubes, cut-down catheters, arterial line and urinary catheter were present, and amphyema also developed. At the end left pneumothorax developed again and probably acute tamponade occurred. Respiration and cardiac arrest were developed and he did not give response to resuscitation.

#### References

1. **Eiseman B, Spencer FC.** Tracheotomy. An underrated surgical procedure. *JAMA* 1963; 184: 683.
2. **Goldstein SI, Breda SD, Schneider KL.** Surgical complications of bedside tracheotomy in an otolaryngology residency program. *Laryngoscope* 1987; 97: 1407-9.
3. **Rogers LA.** Complications of tracheostomy. *South Med J* 1969; 62: 1496-500.
4. **Sarioğlu T, Sennaroğlu I, Sözeri B.** Trakeotomi endikasyonları ve bakımı. *Katkı Pediatri Dergisi* 1993; 6: 613-8.

5. **Hořal IN, Kaya S, Güney E, Tanyeri Y.** Trakeotomi komplikasyonları. Türk Otorino-larengoloji Cemiyeti XII. Milli Kongresi Tutanakları. İstanbul: Bilmen Basımevi; 1973. p. 435-39.
6. **Reilly H, Sasaki CT.** Tracheotomy complications. In: Krespi YP, Ossoff RH, editors. Complications in head and neck surgery. Philadelphia: WB Saunders; 1993. p. 257-74.
7. **Meade JW.** Tracheotomy- its complications and their management. A study of 212 cases. *N Engl J Med* 1961; 265: 519-23.
8. **Fanning J, Lettieri L, Piver MS.** Fatal recurrent reexpansion pulmonary edema. *Obstet Gynecol* 1989; 74: 495-49.
9. **Matfood S, Hix WR, Aaron BL, Blaes P, Watson DC.** Reexpansion pulmonary edema. *Ann Thorac Surg* 1988; 45: 340-5.
10. **Parisi A, Marianeschi PM, Grustozzi GM, Bellavigna G, Alberti D, Sciannameo F.** Unilateral pulmonary edema due to rapid re-expansion in pneumothorax. *Minerva Med* 1986; 77: 2327-9.
11. **Koller W, Mutz N, Putensen C, Putz G.** Treatment of re-expansion edema ("unilateral ARDS") after rapid pneumothorax drainage. *Anaesthesist* 1987; 36: 655-8.
12. **Petty TL, Silvers GW, Paul GW, Stanford RE.** Abnormalities in lung elastic properties and surfactant function in adult respiratory distress syndrome. *Chest* 1979; 75: 571-4.

---

**Correspondence: İlknur Haberal, MD**  
Çamlıca Bulvarı Sitesi F Blok No: 19  
Ümitköy 06530 ANKARA