

OLGU BİLDİRİSİ / CASE REPORT

A retroauricular situated primary hydatid cyst: a case report

M.K. Gürbüz, E. Özudođru, H. aklı, S. Kabukuođlu, N. Dođan

Retroauriküler yerleşimli primer kist hidatik: olgu sunumu

Kist hidatik ekinokok larvaları ile meydana gelen paraziter bir hastalıktır. Bu hastalıkta insanlar ara konak olup asıl konak hayvanlardır. İnsanlar köpek dışkılarındaki yumurtaları yutarak enfekte olurlar. Primer olarak kist hidatiđin boyuna yerleşimi çok ender olarak görülür. Bu alıřmada, 10 yařındaki bir kız ocuđunda tanıı konarak tedavisi yapılan, primer olarak retroauriküler bölgede yerleşim gösteren bir kist hidatik olgusu sunulmaktadır.

Anahtar Sözcükler: Ekinokok, retroaurikuler kitle, kist hidatik.

Abstract

Hydatid cyst results from parasitism by the larval stage of echinococcus species. Echinococcosis is a zoonosis in which humans are an intermediate host of the larval stage of the parasite. Human infection occurs when eggs in dog feces are swallowed. Hydatid cyst, which is situated primary in the neck, is extremely rare. We present a 10-year-old girl with a hydatid cyst located in the retroauricular region that was diagnosed and treated.

Key Words: Echinococcus, retroauricular mass, hydatid cyst.

Türk Otolarengoloji Arşivi, 2006; 44(4): 230-233

Turk Arch Otolaryngol, 2006; 44(4): 230-233

Introduction

Echinococcosis is a zoonosis in which humans are an intermediate host of the parasite. This infection is caused by the larval stage of echinococcus species, four species are recognized within the genus: *Echinococcus granulosus* (which causes cystic hydatid disease), and *Echinococcus multilocularis* (which causes alveolar disease), *Echinococcus vogeli* (which causes polycystic disease) and *Echinococcus oligarthbus* (which causes polycystic disease). The definitive host is a carnivore that feed the adult tapeworm in the small intestine; the carnivore becomes infected by ingesting the larval form in the tissue of the intermediate host. The intermediate hosts become infected by ingesting tapeworm eggs passed in carnivore feces. The dog and other canine species are primary while sheep, cattle, horses, other domestic livestock and occasionally humans are intermediate hosts for this parasite.^{1,2}

Melek Kezban Gürbüz, MD; Erkan Özudođru, MD; Hamdi aklı, MD
Department of Otolaryngology, Faculty of Medicine, Osmangazi University, Eskişehir
Sare Kabukuođlu, MD
Department of Pathology, Faculty of Medicine, Osmangazi University, Eskişehir
Nihal Dođan, MD
Department of Microbiology, Faculty of Medicine, Osmangazi University, Eskişehir

This disease is common in South America, the Mediterranean basin, the Middle East, East Africa, Australia, New Zealand and central Asia. As for some regions such as United Kingdom, North America, Eastern and Central Europe, endemic foci have been reported. The species of *Echinococcus granulosus* is the most common form that gives rise to cysts primarily in the liver and lungs. The hydatid cysts located in the neck are rare in the literature.³⁻⁵ Here we present a case of a hydatid cyst located in the retroauricular region.

Case Report

A 10-year-old girl, living in the orphanage, was referred with 1 year history of a slowly enlarging painless retroauricular mass. She had been treated by giving a nonspecific antibiotic for the neck mass. The mass size had not been decreased with this medication. On our physical examination, a non-tender, fluctuant, non-inflammatory 4 cm in diameter, painless and immobile subcutaneous mass was detected in the right retroauricular region. No cervical lymphadenopathy was palpated. Laboratory data were found within normal limits. The plain chest X-ray was normal. The cervical ultrasonography (US) showed a well-circumscribed cyst with septation located in the right retroauricular region and reported as consistent with a hydatid cyst or lymphocel. Computed tomography (CT) showed a well-circumscribed, lobulated 4 cm cystic mass in the right retroauricular region which showed septations and reached to the level of the C2 spine and right occipital bone (Figure 1). There was no evidence of invasion to the adjacent structures. It was reported as the view consistent with a hydatid cyst. The anti-echinococcus antibodies were reported as negative (IBL Hamburg *Echinococcus granulosus* IgG ELISA Quantitative test cat. No 2E56). Further investigations including abdominal ultrasonography, bone scan and cranial, thoracic, abdominal CT did not determine another mass or cyst. The fine-needle aspiration biopsy wasn't performed preoperatively because of the risks. Mebendazole chemotherapy (50 mg/kg) was given for hydatid cyst prophylaxis.

Under general anesthesia, cystic fluid was aspirated by needle before the cyst was removed and this crystal

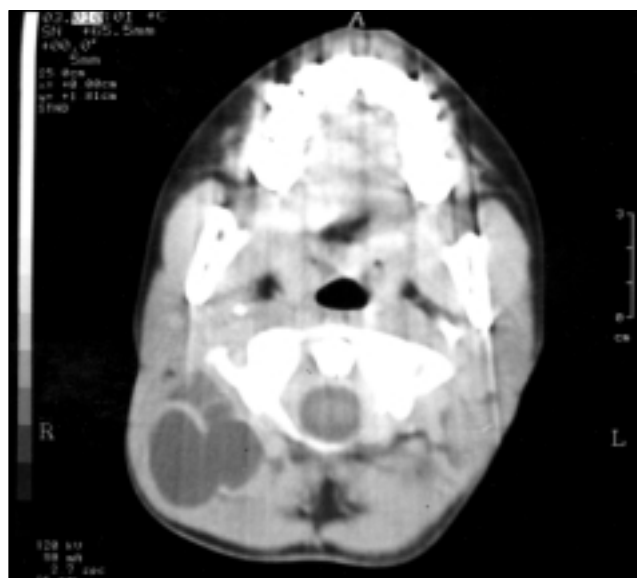


Figure 1. The computed tomography scanning with contrast infusion showed a well-circumscribed, lobulated, showing septations cystic mass.

clear fluid was sent for cytologic examination after that the mass was removed without any damage to its wall. The operation field was irrigated with hypertonic saline solution. The histopathologic results were reported as the scoleces present in the aspirated cyst fluid (Figure 2). The patient was given 50 mg/kg mebendazole chemotherapy postoperatively two months. The case is followed without any problem and disease-free after one year.

Discussion

Hydatid cyst may cause illness in intermediate hosts, generally herbivorous animals, and humans who are infected accidentally and it is rarely fatal. In some endemic countries, children have higher infection rates because they are most likely to play with dogs. The parasite lives in the small intestine of the primary hosts, the terminal segment of the adult tapeworm contains so many eggs and human infection occurs when eggs passed in dog feces are accidentally swallowed. Some larvae reach the lung (about 25% of all cysts) and develop into pulmonary hydatids. Infrequently, a few larvae may pass through the liver, pulmonary capillaries, heart and reach the general circulation thus cysts

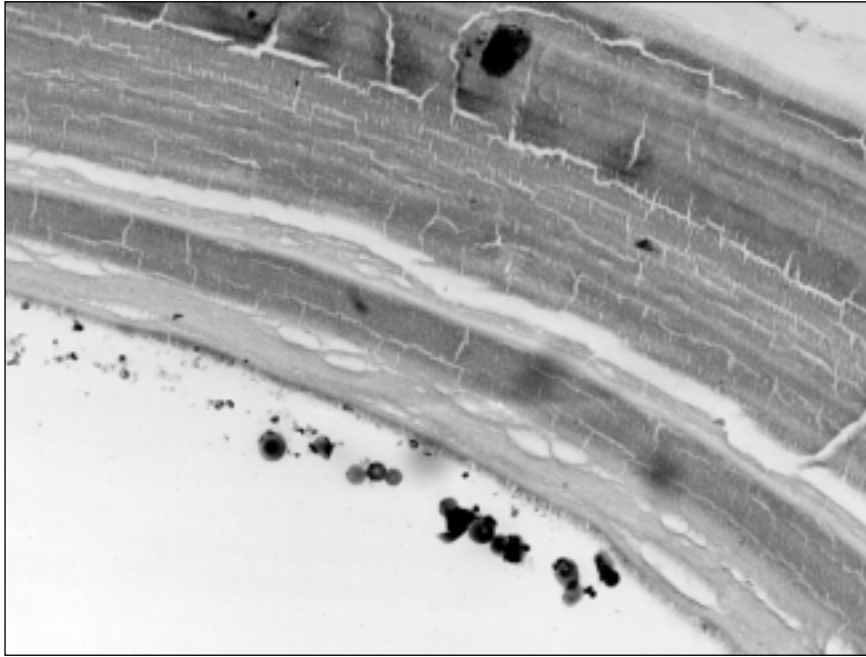


Figure 2. The scoleces in the aspirated cyst fluid (Giemsa x800).

may form in organs such as the brain, bones, skeletal muscles, kidneys, spleen, brain, thyroid gland and others.^{2,3,6-12} A hydatid cyst in the neck with no extra-cervical involvement is very rare.

The most of hydatid cysts cause no symptoms. The cyst may also be discovered accidentally during radiographic examination, body scanning, surgery, or for other clinical reasons. The usual signs and symptoms are not pathognomic for a hydatid cyst in the neck and the main symptom is a slow-growing mass.^{1,4,10,13} A slow-growing, painless mass in the retroauricular region was the only symptom of our case. There was no other symptom.

Generally, routine laboratory tests do not show specific results and in most cases, eosinophilia is limited for a hydatid cyst. Serologic tests are available but, no standard, highly sensitive, and specific serologic test exists for CE antibody detection. Children aged 3-15 years may produce minimal serologic reactions.^{2,6,9} Indirect hemagglutination test and enzyme-linked immunosorbent assay are the most widely used methods for the detection of anti-echinococcus antibodies

but they were negative in our case. We thought that negative results of the serologic tests were due to minimal serologic reactions in children.

There are some typical views for the US image in a hydatid cyst. Some cysts show well-defined borders and uniform anechoic contents and this image is not pathognomic for echinococcal cysts. Another view of the hydatid cyst is a visible split wall inside (floating membrane or water lily sign). The third type of view is septated cysts, or cysts with a honeycomb pattern, are likely to be echinococcal. The last type is a solid heterogeneous mass and difficult to differentiate from granulomas or tumors.^{4,6,11,12} The US image of the mass was consistent with the septated cyst in our case.

CT scanning has the advantage of inspecting any organ (lungs cannot be explored by US), detecting smaller cysts when located outside the liver, locating cysts precisely. Measurement of cyst density appears to be an additional tool to differentiate parasitic from non-parasitic cysts. US and CT examinations are useful in visualizing cystic masses by demonstrating internal septae and daughter cysts.^{1,4,5,7,9-12} There was no daughter cyst image of our case in the US and CT imaging and

the internal septae imaging was found likely to be echinococcal.

The fine needle aspiration biopsy of the cyst hydatid is controversial because of some risks such as spillage of the cyst fluid, anaphylactic reaction.^{1,6,12,13} We didn't use this method because of the risks.

It is very important to remove the cyst without any damage to its wall.^{1,5,7,8} The cyst was aspirated during the surgery for preventing the cyst rupture thus dissection of the cyst wall from adjacent structures was performed easily in our case. It has been suggested to start chemotherapy before the surgery for prophylaxis and to reduce of the cyst tenderness.^{4,6,10}

CT and US are very useful guides for the diagnosis of a hydatid cyst. Hydatid cyst should be kept in mind for the differential diagnosis of the neck masses specially in the children. The use of chemotherapy pre- and post-operatively for hydatid cyst not only provide the prevention of contamination but also facilitate the surgery.

References

1. **Eckert J, Thomson RC.** Intraspecific variation of *Echinococcus granulosus* and related species with emphasis on their infectivity to humans. *Acta Trop* 1997; 64: 19-34.
2. **Garcia LS.** Diagnostic medical parasitology. 4th ed. Washington DC: ASM Press; 2001. p. 386-412.
3. **Akal M, Kara M.** Primary hydatid cyst of the posterior cervical triangle. *J Laryngol Otol* 2002; 116: 153-5.
4. **Fradis M, Podoshin L, Goldstein Y, Miselevich I, Boss JH.** Cervical echinococcal hydatid cyst. *J Laryngol Otol* 1989; 103: 435-7.
5. **de Moura LS, da Silva CP.** Thyroid hydatid disease in an 8-year-old girl. *J Pediatr Surg* 1991; 26: 216.
6. **Delince P, Bremen J, Ectors P.** A rare tumor of the neck; a hydatid cyst. Pathophysiology and diagnosis of echinococcal disease. *Acta Chir Belg* 1979; 78: 273-9.
7. **Goldsher M, Eliachar I, Joachims Z, Golz A.** Primary hydatid cyst of the maxillary sinus. *J Laryngol Otol* 1983; 97: 869-70.
8. **El Kohen AE, Benjelloun A, El Quessar A, et al.** Multiple hydatid cysts of the neck, the nasopharynx and the skull base revealing cervical vertebral hydatid disease. *Int J Pediatr Otorhinolaryngol* 2003; 67: 655-62.
9. **Önerci M, Turan E, Ruacan Ş.** Submandibular hydatid cyst. A case report. *J Craniomaxillofac Surg* 1991; 19: 359-61.
10. **Prousalidis J, Tzardinoglou K, Sgouradis L, Katsohis C, Aletras H.** Uncommon sites of hydatid disease. *World J Surg* 1998; 22: 17-22.
11. **Eroğlu A, Atabekoğlu S, Kocaoğlu H.** Primary hydatid cyst of the neck. *Eur Arch Otorhinolaryngol* 1999; 256: 202-4.
12. **Soylu L, Aydoğan LB, Kiroğlu M, et al.** Hydatid cyst in the head and neck area. *Am J Otolaryngol* 1995; 16: 123-5.
13. **Paşaoğlu E, Damgacı I, Tokoğlu F, Yıldırım N, Alp AO, Yüksel E.** CT findings of hydatid cyst with unusual location: infratemporal fossa. *Eur J Radiol* 1998; 8: 1570-2.

Correspondence: Melek Kezban Gürbüz, MD
Department of Otolaryngology
School of Medicine, Osmangazi University
Eskişehir-TURKEY
e-mail: melekkezban@hotmail.com