

# A Rare Tumor of Palatine Tonsils: Chondrolipoma

## *Palatin Tonsillerin Nadir Bir Tümörü: Kondrolipom*

### Case Report Olgu Sunumu

Gamze Öztürk<sup>1</sup>, Umman Tunç<sup>1</sup>, Kadir Balaban<sup>2</sup>, Hülya Eyigör<sup>1</sup>

<sup>1</sup>Department of Otorhinolaryngology, Antalya Training and Research Hospital, Antalya, Turkey

<sup>2</sup>Department of Pathology, Health Sciences University, Antalya Training and Research Hospital, Antalya, Turkey

### Abstract

Chondrolipomas are benign mesenchymal tumors that have two mature tissues simultaneously and emerge as a result of cartilaginous metaplasia in lipomas. They rarely occur in the head and neck area (1%-4%), and occur more frequently in the 60-70 years age group. Although there are cases of the nasopharynx, tongue, lip, and neck reported in the literature, we have been able to find only two cases on tonsils. The case of a

17-year-old male patient, who presented to our clinic complaining of dysphagia and was diagnosed with tonsillar chondrolipoma, is described here, along with the radiological, clinical, and immunohistochemical findings, as well as the review of the literature

**Keywords:** Chondrolipoma, palatine tonsil, tonsillar neoplasm, dysphagia

### Öz

Kondrolipomlar lipomların içinde kıvrımda metaplaziye meydana gelmesi sonucu görülen, iki matür dokuyu aynı anda barındıran benign mezankimal tümörlerdir. Baş boyun bölgesinde oldukça nadir olup (%1-4), sıklıkla 60-70 yaş arasında görülmektedir. Literatürde nazofarenks, dil, dudakta ve boyunda bildirilen olgular olmakla birlikte, tonsillerde bildirilmiş şu ana kadar

bizim saptayabildiğimiz yalnızca iki olgu mevcuttur. Kliniğimize disfaji yakınması ile başvuran ve tonsilde kondrolipom tanısı alan 17 yaşında erkek hasta, radyolojik, klinik ve immünohistokimyasal bulguları ile birlikte literatür eşliğinde sunulmuştur.

**Anahtar kelimeler:** Kondrolipom, palatin tonsil, tonsiller neoplasm, disfaji



#### ORCID IDs of the authors:

Ö.G. 0000-0002-9478-7603;  
U.T. 0000-0003-1040-2110;  
K.B. 0000-0002-7073-8786;  
H.E. 0000-0001-5317-431X.

**Cite this article as:** Öztürk G, Tunç U, Balaban K, Eyigör H. A Rare Tumor of Palatine Tonsils: Chondrolipoma. Turk Arch Otorhinolaryngol 2018; 56(3): 180-2.

### Introduction

Defined by Stout in 1948, chondrolipomas are mesenchymal tumors resulting from cartilaginous metaplasia in lipomas and having two mature tissues simultaneously (1). They may occur anywhere in the body and generally present as slowly growing, solitary, and asymptomatic subcutaneous or superficial lesions. About 20% of chondrolipomas develop in the head and neck region, with only 1%-5% of these neoplasms involving the oral cavity (2).

In this case report, a 17-year-old male patient who presented to our clinic complaining of dysphagia and was diagnosed with tonsillar chondrolipoma is described, along with radiological, clinical, and immunohistochemical findings, as well as the review of the literature.

### Case Presentation

A 17-year-old male patient presented to our clinic complaining of dysphagia and a mass growing in the

oral cavity for the past one year. An oropharyngeal examination revealed a pedunculated mass with a smooth surface, approximately 3×1 cm in size, arising from the upper pole of the right tonsil and extending toward the midline (Figure 1).

No additional pathology was observed in the otorhinolaryngological examination of the patient. The magnetic resonance imaging (MRI) of the neck revealed a well-circumscribed nodular lesion, approximately 1 cm in diameter with a moderate enhancement on the anteromedial wall, and fat intensity in all sequences in post contrast series in the right palatine tonsil (Figure 2).

An incision of one cm was made on the upper pole of the right tonsil, and the mass was excised by dissection under sedoanalgesia (Figure 3). Intraoperative frozen examination was reported as a benign pathology. Histopathologic examination revealed

This study was presented at the 13th Turkish Rhinology Congress, May 4-7, 2017, Antalya, Turkey.

Bu çalışma, 13. Türk Rinoloji kongresinde sunulmuştur, 4-7 Mayıs 2017, Antalya, Türkiye.

#### Corresponding Author/Sorumlu Yazar:

Hülya Eyigör; hulinar@yahoo.com

Received Date/Geliş Tarihi: 23.02.2018

Accepted Date/Kabul Tarihi: 03.05.2018

© Copyright 2018 by Official Journal of the Turkish Society of Otorhinolaryngology and Head and Neck Surgery Available online at www.turkarchotolaryngol.net

© Telif Hakkı 2018 Türk Kulak Burun Boğaz ve Baş Boyun Cerrahisi Derneği Makale metnine www.turkarchotolaryngol.net web sayfasından ulaşılabilir.

DOI: 10.5152/tao.2018.3317

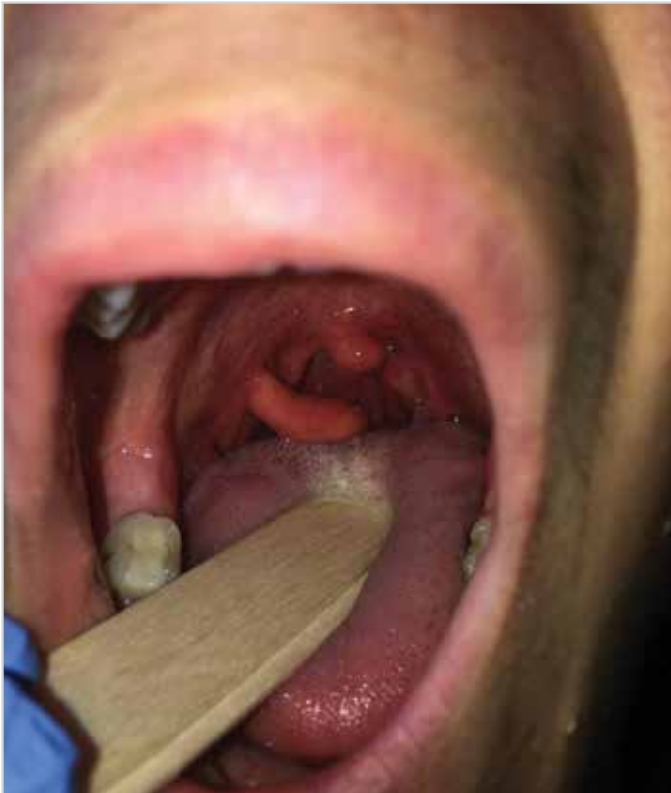

Figure 1. Chondrolipoma arising from the upper pole of the right tonsil

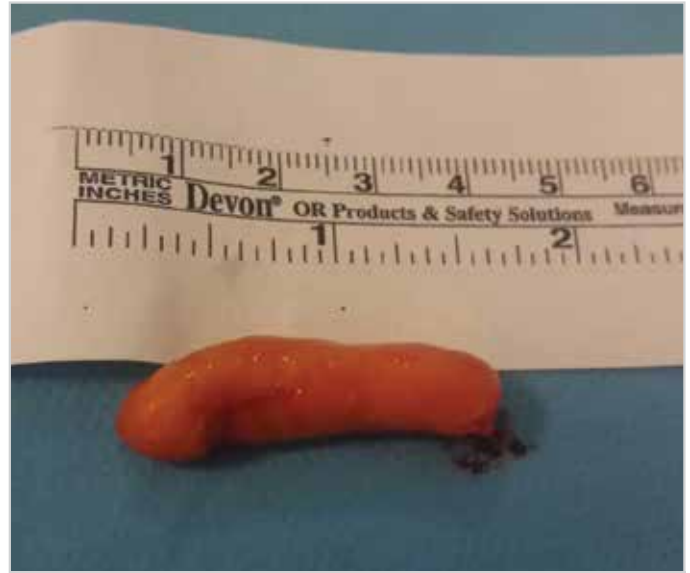

Figure 3. Excised chondrolipoma of the right tonsil

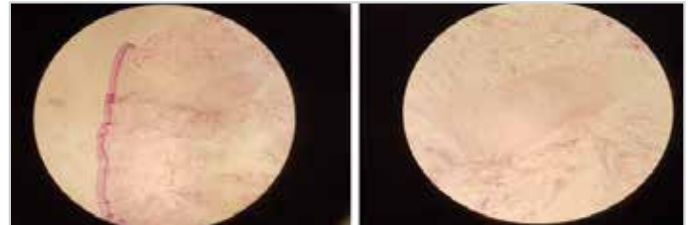


Figure 4. a, b. Lipoma with chondroid differentiation. The area of the mature cartilage nodule is surrounded by normal fat tissue (hematoxylin and eosin staining X40)

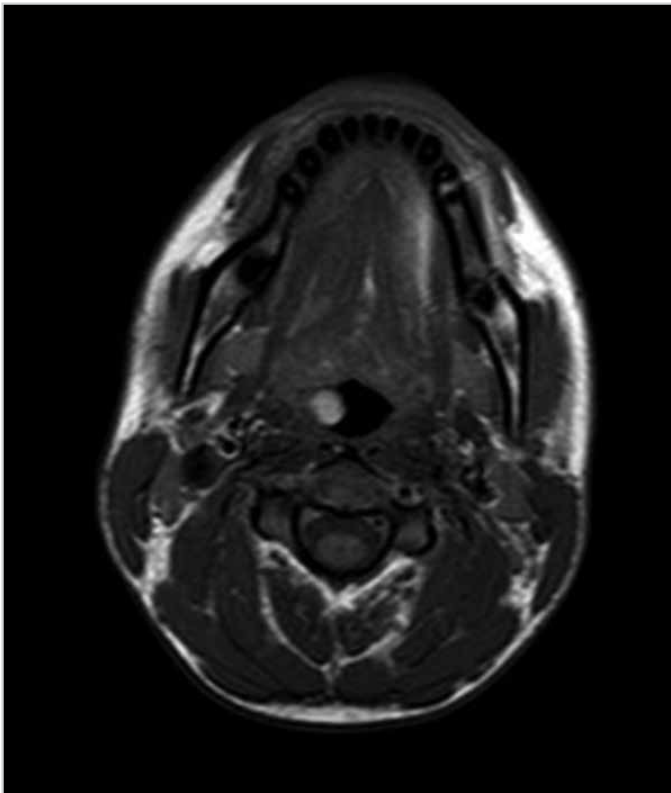


Figure 2. Axial T1 weighted magnetic resonance imaging of the mass

a lobular encapsulated tumor with an appearance of mature fat tissue, separated by a fibrous septa under the stratified squamous epithelium. A metaplastic hyaline cartilaginous tissue with no mitosis and necrosis in foci was observed (Figure 4). Histopathologic

diagnosis was reported as chondrolipoma. Surgical margins were negative. One year follow-up of the patient revealed no evidence of any recurrence.

### Discussion

Lipomas are common mesenchymal tumors that constitute approximately 13% of head and neck tumors. Chondrolipoma is a rare form of lipoma, which can be found at any anatomical site. Chondrolipomas can occur almost in any part of the body, particularly in the breast, head and neck connective tissue, and skeletal muscles. They are quite uncommon in the oral cavity (3). Because there are a limited number of cases reported in the literature, we still do not have sufficient evidence regarding many clinical and histopathological characteristics of chondrolipomas, which should be considered in differential diagnosis.

To the best of our knowledge, there are only two articles where chondrolipoma in tonsils has been reported in the literature so far (3, 4). Halaas et al. (4) reported the first case who underwent a surgical excision because of a mass that was arising from posterior tonsillar pillar. The other case reported in the literature was a 13-year-old male patient who complained of sore throat, aphonia, and respiratory difficulties that lasted for four days. Physical examination revealed a pedunculated mass of 4x2x2-cm, on the left tonsil, narrowing the airway (3). Tonsillectomy was chosen as the treatment option in this case, whereas in our case, the mass

was dissected from the tonsillar tissue and removed completely. As the patient was without any history of tonsillar hypertrophy and chronic tonsillitis, we did not perform tonsillectomy, because the intraoperative frozen examination was reported to be benign. In the postoperative period, the patient did not have any complaints or recurrence during one year of follow-up. For tonsillar lipoma cases, it was reported that excision of the mass would be sufficient, with no need for a tonsillectomy (5). Although there are a limited number of publications in the literature, no malignant transformation has been reported so far (3).

Benign tumors occur in the palatine tonsil more frequently than malign tumors do. In the differential diagnosis of benign masses in tonsils, the following should be considered: juvenile angiofibroma, fibroepithelial polyp, arteriovenous malformation, lymphangiectasia, squamous papilloma, hamartoma, inclusion cyst, lipoma, and fibroma (6, 7). In the differential diagnosis, radiological scanning might be beneficial; however, the disease does not have a specific radiological appearance. Chondrolipomas can only be differentiated histopathologically from other pathologies because the radiological and physical characteristics are similar with other masses (8).

Variants of lipoma are histologically different from ordinary lipoma by characteristic microscopic features and specific clinical appearance. Primary variants of lipoma can be listed as angiolipoma, myolipoma, fibrolipoma, angiomyolipoma, myelolipoma, chondroid lipoma, chondrolipoma, fusiform cell, and pleomorphic lipoma. Chondrolipomas are characterized by presence of mature cartilage and proliferation of mature adipocytes. These variants are described as unencapsulated soft tissue neoplasms composed of two or more unrelated mature mesenchymal tissues (2). In chondrolipoma, there are mature adipocytes between the mature cartilage regions and in chondroid lipoma, which is often mistaken for chondrolipoma, there are cells like lipoblasts containing multiple vacuoles in the myxohyaline and chondroid matrix. Chondroid lipoma shows features of both lipoma and hibernoma; it is also known as lipoma of immature fat, lipoma of the embryonic fat, or fetal lipoma (4). Also, chondrolipoma should be differentiated from skeletal chondroma. The chondroid component of chondrolipoma is focal and lacks any lobular arrangement. Skeletal chondroma occurs in deep submucosal areas and is characterized by a higher rate of cartilaginous tissue arranged in distinct lobular pattern (2). The role of factors such as Sox-9, RUNX-2, TGF- $\beta$ , and the bone morphogenic protein in chondrogenic potential of lipomas has been discussed. The pluripotentiality of stem cells of adipose origin and preferential expression and interplay of pro-chondrogenic molecules, either through some genetic alteration or environmental factors, are responsible for chondrogenesis in these lesions (2).

## Conclusion

To the best of our knowledge, there are only two cases of chondrolipoma in palatine tonsils reported in the literature. Because we

still do not have sufficient information about the histopathology and clinical aspects of palatine tonsil chondrolipoma, we consider it a rare tumor that should be considered in the differential diagnosis of benign tumors of the palatine tonsils.

**Informed Consent:** Written informed consent was obtained from the from the parents of the patient who participated in this study.

**Peer-review:** Externally peer-reviewed.

**Author Contributions:** Concept - G.Ö., U.T., K.B., H.E.; Design - G.Ö., U.T., K.B., H.E.; Supervision - G.Ö., U.T., K.B., H.E.; Resource - H.E., G.O., U.T., K.B.; Materials - G.O., U.T.; Data Collection and/or Processing - G.O., U.T., K.B.; Analysis and/or Interpretation - H.E., K.B.; Literature Search - G.O., U.T., K.B.; Writing - G.O., U.T., K.B.; Critical Reviews - G.O., U.T., K.B., H.E.

**Conflict of Interest:** The authors have no conflicts of interest to declare.

**Financial Disclosure:** The authors declared that this study has received no financial support.

**Hasta Onamı:** Yazılı hasta onamı bu çalışmaya katılan hastanın ebeveyninden alınmıştır.

**Hakem Değerlendirmesi:** Dış bağımsız.

**Yazar Katkıları:** Fikir - G.Ö., U.T., K.B., H.E.; Tasarım - G.Ö., U.T., K.B., H.E.; Denetleme - G.Ö., U.T., K.B., H.E.; Kaynaklar - H.E., G.O., U.T., K.B.; Gereçler - G.O., U.T.; Veri Toplanması ve/veya İşlemesi - G.O., U.T., K.B.; Analiz ve/veya Yorum - H.E., K.B.; Literatür Taraması - G.O., U.T., K.B.; Yazıyı Yazan - G.O., U.T., K.B.; Eleştirel İnceleme - G.O., U.T., K.B., H.E.

**Çıkar Çatışması:** Yazarlar çıkar çatışması bildirmemişlerdir.

**Finansal Destek:** Yazarlar bu çalışma için finansal destek almadıklarını beyan etmişlerdir.

## References

1. Stout AP. Mesenchymoma, the mixed tumor of mesenchymal derivatives. *Ann Surg* 1948; 127: 278-90. [CrossRef]
2. Raj V, Dwivedi N, Sah K, Chandra S. Chondrolipoma: Report of a rare intra oral variant with review of histogenetic concepts. *J Oral Maxillofac Pathol* 2014; 18: 276-80. [CrossRef]
3. Al-Kindi H, Fletcher CD, Khan Y. Chondrolipoma of the tonsil. *Pathology* 2016; 48: 386-8. [CrossRef]
4. Halaas YP, Mra Z, Edelman M. Chondrolipoma of the oropharynx. *Ear Nose Throat J* 2001; 80: 146-7.
5. Kanotra SP, Davies J. Management of tonsillar lipoma: is tonsillectomy essential? *Case Rep Otolaryngol* 2014; 2014: 451570.
6. Gangopadhyay, M. Chakrabarty R, Mitra P, Nag SS. Hamartoma of palatine tonsil: a rare case. *Oman Med* 2016 3: 450-2.
7. Park E, Pransky SM, Malicki DM, Hong P. Unilateral lymphangiomatic polyp of the palatine tonsil in a very young child: a clinicopathologic case report. *Pediatr* 2011; 2011: 451542.
8. Pitman KT, Bell D. Chondrolipoma of head and neck: case report and review of literature. *Head Neck* 2013; 35: 18-20. [CrossRef]