




A Rare Orbital Complication of Sinusitis in a Pregnant Patient: Orbital Inflammatory Granulation

Gebe Bir Hastada Nadir Görülen Sinüzit Komplikasyonu: İnflamatuvar Orbital Granülasyon

Case Report
 Olgu Sunumu

Murat Samet Ateş , Mustafa Uslu , Sercan Göde , İsa Kaya , Raşit Midilli 
 Department of Otorhinolaryngology-Head and Neck Surgery, Ege University School of Medicine, İzmir, Turkey

Abstract

Development of orbital inflammatory granulation in pregnant patients as an orbital complication of acute sinusitis is extremely rare. Herein, we describe the case of a patient with a complication of acute sinusitis that mimicked orbital tumors. The patient presented with left orbital protrusion. Magnetic resonance imaging revealed pansinusitis with a well-defined mass lesion in the extraconal space of the left orbit. Endoscopic

endonasal sphenoethmoidectomy and orbital decompression were performed. Histopathological examination revealed acute inflammatory granulation tissue. To the best of our knowledge, this is the first report to describe orbital inflammatory granulation in a pregnant patient as an orbital complication of sinusitis.

Keywords: Sinusitis, complication, orbital granulation, pregnant woman

Öz

Gebe bir hastada orbital inflamatuvar granülasyon dokusu gelişimi, akut sinüzitin orbital komplikasyonu olarak son derece nadirdir. Burada, orbita tümörlerini taklit eden bir akut sinüzit komplikasyonu olgusunu sunduk. Hasta sol orbital protrüzyon ile başvurdu. Manyetik rezonans görüntülemesinde pansinüzit ile sol orbita ekstra-konikal mesafesinde iyi tanımlanmış bir kitle lezyonu saptandı. Endoskopik endonazal sfenoetmoidektomi ve

orbita dekompresyonu uygulandı. Histopatolojik incelemede akut inflamatuvar granülasyon dokusu görüldü. Bildiğimiz kadarıyla bu, gebe bir hastada akut sinüzitin orbital komplikasyonu olarak görülen orbital inflamatuvar granülasyonu tanımlayan ilk olgu sunumudur.

Anahtar kelimeler: Sinüzit, komplikasyon, orbital granülasyon, gebe kadın



ORCID IDs of the authors:

M.S.A. 0000-0003-4419-0662;
 M.U. 0000-0003-4419-0662;
 S.G. 0000-0001-9703-8467;
 İ.K. 0000-0001-7096-4858;
 R.M. 0000-0002-2862-9164.

Cite this article as: Ateş MS, Uslu M, Göde S, Kaya İ, Midilli R. A rare orbital complication of sinusitis in a pregnant patient: Orbital inflammatory granulation. Turk Arch Otorhinolaryngol 2018; 56(2): 126-8.

Introduction

Unilateral proptosis generally occurs due to rhinosinusitis-related orbital infections in children. In adults, it is commonly related to Graves' ophthalmopathy, orbital pseudotumor, and rhinosinusitis-related orbital infections. Orbital infections without appropriate treatment may lead to serious complications; however, nowadays, with antibiotic usage, the incidence of serious complications has dramatically decreased (1). In this manuscript, the case of a pregnant woman with an orbital complication of acute rhinosinusitis is presented, along with the patient's clinical and radiological features. The diagnosis, treatment, and follow-up of this pathology are discussed with review of the literature.

plaints of headache and a left eye swelling that has been increased in day by day since three weeks. Her physical examination revealed purulent nasal discharge and inferolateral protrusion of the left orbit (Figure 1). Extraocular movements were clearly restricted in the left eye. The patient's neck examination was normal. Patient's complete blood count was as follows: leucocyte levels, 11530/ μ L; neutrophil levels, 9200/ μ L; and hemoglobin levels, 11.2 g/dL. In addition, increased ALT (Alanin aminotransferaz) (34 IU/L), AST (Aspartat aminotransferaz) (34 U/L), ALP (Alkaline phosphatase) (157 U/L), GGT (41 U/L), and CRP (C-reactive protein) (9.04 mg/dL) levels were detected.

Magnetic resonance imaging (MRI) findings revealed pansinusitis and a well-defined mass lesion in the extraconal space of the left orbit, which measured 34×16 mm, and an inferolaterally protruding

Case Presentation

A 27-year-old, 32-week-pregnant woman presented to the Emergency Department with com-

Corresponding Author/Sorumlu Yazar:
 Murat Samet Ateş; muratsametates@gmail.com

Received Date/Geliş Tarihi: 06.12.2017
Accepted Date/Kabul Tarihi: 03.02.2018

© Copyright 2018 by Official Journal of the Turkish Society of Otorhinolaryngology and Head and Neck Surgery Available online at www.turkarchotolaryngol.net

© Telif Hakkı 2018 Türk Kulak Burun Boğaz ve Baş Boyun Cerrahisi Derneği Makale metnine www.turkarchotolaryngol.net web sayfasından ulaşılabilir.

DOI: 10.5152/tao.2018.3082

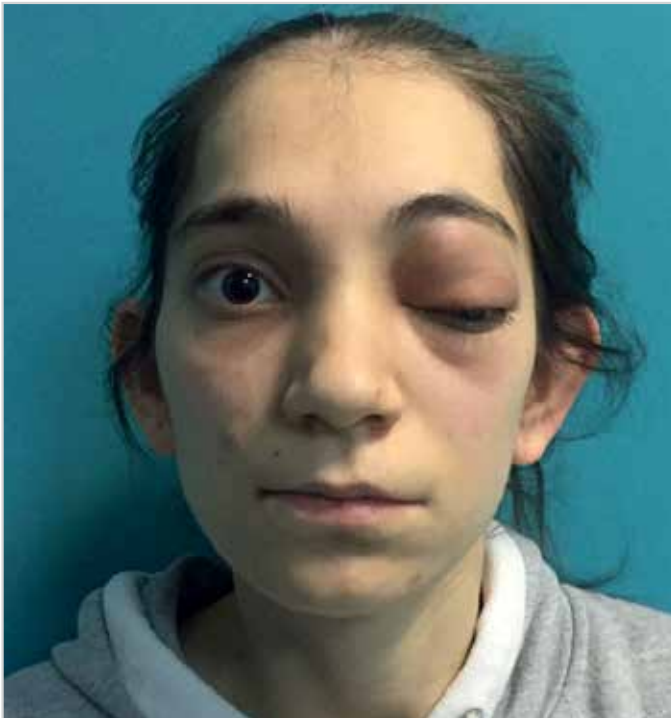

Figure 1. Preoperative photograph indicating edema, hyperemia, and proptosis

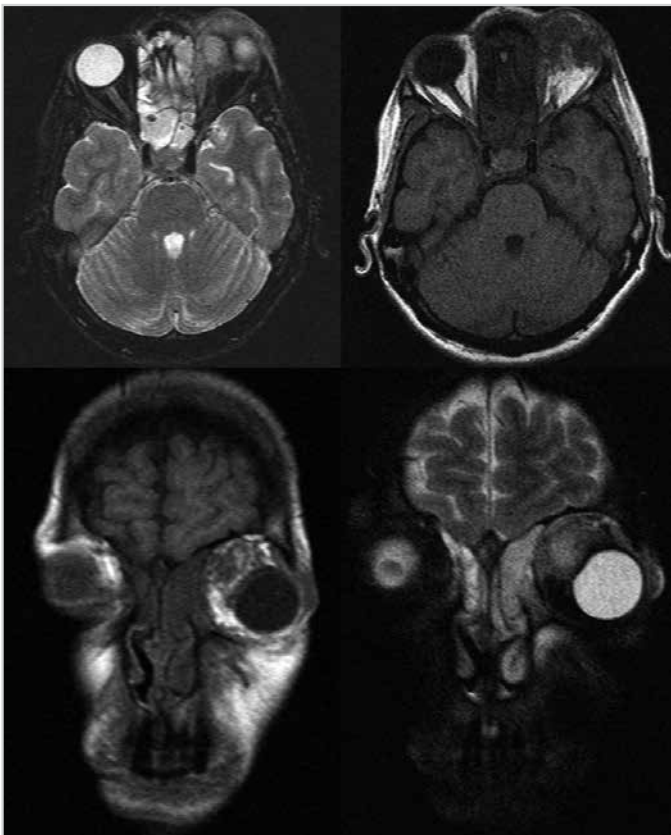


Figure 2. Magnetic resonance image demonstrating anterosuperior localization of the lesion and pansinusitis

left globe (Figure 2). The patient was evaluated by Radiology and Ophthalmology consultations about the mass lesion. It was considered that the lesion could be an atypical abscess or a lymphoma. Also, an obstetrician had examined the patient. The

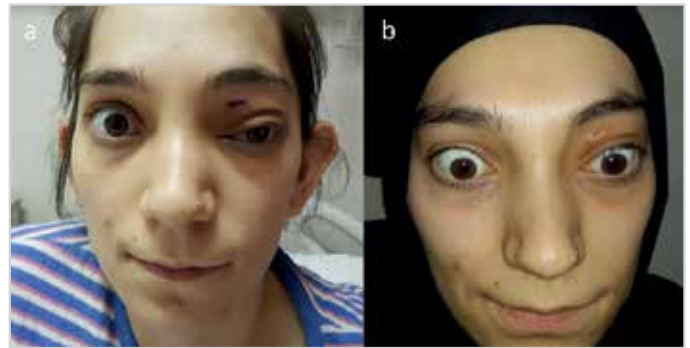

Figure 3. Follow-up of the patient on postoperative days 1 (a) and 7 (b)

patient's visual acuity was normal. Intravenous treatment with 4000 mg of ampicillin/sulbactam had begun.

After obtaining informed consent from the patient for undergoing surgery and receiving all treatment modalities, she immediately underwent endoscopic endonasal sphenoidectomy and orbital decompression. The patient was in the supine position, and the operating table was tilted to 30° in the anti-Trendelenburg position. An anesthesiologist adjusted the patient's systolic blood pressure around 120 mm Hg. During endoscopic surgery, the mass was solid and resembled granulation tissue without any purulent discharge. Due to the solid pattern and anterosuperior localization of the mass, external orbitotomy was planned to completely remove the mass. The mass was completely removed with combined endoscopic endonasal orbital decompression and external orbitotomy. The patient had an uneventful postoperative recovery.

Treatment with ampicillin/sulbactam was continued for approximately seven days after surgery. The postoperative histopathology of the mass revealed acute inflammatory granulation tissue. There was no specific microbial agent determined in the culture. During the follow-up, eye movements were back to normal in two days, inflammatory marker levels decreased to normal, and protrusion regressed. Postoperative photographs of the patient are shown in Figure 3. The patient was discharged from the hospital with a prescription including oral amoxicillin/clavulanic acid. The patient has been followed for three months without any recurrent symptoms or signs and she also delivered a healthy baby.

Discussion

Rhinosinusitis may spread to the orbital space and cause several orbital complications. The relationship between the orbital veins and the paranasal veins facilitates this complication (2, 3). Orbital cellulitis and abscesses are common in children and adolescents, with a peak incidence during the first 15 years of life. Disease can be more serious in older ages. (4, 5). Polymicrobial infections are commonly seen in elderly patients (4-8).

Empirical antibiotic treatment can be used for pathogens associated with acute rhinosinusitis. If treatment fails within the first 24-48 h, surgery is inevitable for achieving a cure (9). It should be noted that the definitive treatment for orbital abscesses is drainage (5).

The presence of clinical features such as acute onset swelling, orbital protrusion, ophthalmoplegia, and nasal purulent discharge is suggestive of the diagnosis of orbital abscess. Radiological findings of patient revealed a diagnostic dilemma for atypical abscess or soft tissue mass in the orbit. In general; due to the lack of contrast enhancement magnetic resonance images, radiologists cannot differentiate a tumor from an atypical abscess. Considering the presence of rhinosinusitis both radiologically and clinically, the patient underwent surgery with the diagnosis of an orbital abscess as a rhinosinusitis complication.

Endoscopic endonasal surgery of pregnant patients warrants some special perioperative considerations. The anti Trendelenburg position should be modified by turning patients to their left side by approximately 20°. With this, blood supply to the sinusal mucosa decreases. The systolic blood pressure should be adjusted higher in pregnant patients and should be around 120 mmHg. The use of topical adrenaline should be avoided in pregnant patients (10, 11).

Our patient had an uneventful postoperative recovery. The patient's symptoms resolved during follow-up. Eye movements were completely normal at the end of the first week and the protrusion completely resolved.

Postoperative histopathology of the mass revealed acute inflammatory granulation tissue. Inflammatory solid granulation secondary to rhinosinusitis is a rare clinical condition. It is considered as an acute complication of rhinosinusitis and should be immediately treated with surgery (12). To the best of our knowledge, this is the first case to describe orbital inflammatory granulation in a pregnant patient due to rhinosinusitis.

Conclusion

Pregnant patients' management of complicated rhinosinusitis have common basic concepts. Preoperatively, as a differential diagnosis orbital mass should be considered. Perioperative position of the patient and maintenance of appropriate blood pressure should be controlled. We propose that in the presence of inflammatory granulation tissue formation, we should prefer surgical treatment in terms of failure in antibiotics treatment regimen in the duration of 24-48 hours.

Informed Consent: Written informed consent was obtained from the patient who participated in this study.

Peer-review: Externally peer-reviewed.

Author Contributions: Concept - M.S.A., M.U.; Design - M.S.A., S.G., R.M.; Supervision - S.G., İ.K., R.M.; Resource - M.S.A., M.U.; Materials - M.S.A., İ.K.; Data Collection and/or Processing - M.S.A., M.U.; Analysis and/or Interpretation - İ.K., R.M.; Literature Search - M.S.A., M.U.; Writing - M.S.A., M.U., S.G.; Critical Reviews - R.M., İ.K.

Conflict of Interest: The authors have no conflicts of interest to declare

Financial Disclosure: The authors declared that this study has received no financial support.

Hasta Onamı: Yazılı hasta onamı bu çalışmaya katılan hastadan alınmıştır.

Hakem Değerlendirmesi: Dış bağımsız.

Yazar Katkıları: Fikir - M.S.A., M.U.; Tasarım - M.S.A., S.G., R.M.; Denetleme - S.G., İ.K., R.M.; Kaynaklar - M.S.A., M.U.; Gereçler - M.S.A., İ.K.; Veri Toplanması ve/veya İşlemesi - M.S.A., M.U.; Analiz ve/veya Yorum - İ.K., R.M.; Literatür Taraması - M.S.A., M.U.; Yazıyı Yazan - M.S.A., M.U., S.G.; Eleştirel İnceleme - R.M., İ.K.

Çıkar Çatışması: Yazarlar çıkar çatışması bildirmemişlerdir.

Finansal Destek: Yazarlar bu çalışma için finansal destek almadıklarını beyan etmişlerdir.

References

- Hoxworth JM, Glastonbury CM. Orbital and intracranial complications of acute sinusitis. *Neuroimaging Clin N Am* 2010; 20: 511-26. [CrossRef]
- Chandler JR, Langenbrunner DJ, Stevens ER. The pathogenesis of orbital complications in acute sinusitis. *Laryngoscope* 1970; 80: 1414-28. [CrossRef]
- Rahbar R, Robson CD, Petersen RA, DiCanzio J, Rosbe KW, McGill TJ, et al. Management of orbital subperiosteal abscess in children. *Arch Otolaryngol Head Neck Surg* 2001; 127: 281-6. [CrossRef]
- Ferguson MP, McNab AA. Current treatment and outcome in orbital cellulitis. *Aust N Z J Ophthalmol* 1999; 27: 375-9. [CrossRef]
- Harris GJ. Subperiosteal abscess of the orbit. *Arch Ophthalmol* 1983; 101: 751-7. [CrossRef]
- Ikeda K1, Oshima T, Suzuki H, Kikuchi T, Suzuki M, Kobayashi T. Surgical treatment of subperiosteal abscess of the orbit: Sendai's ten-year experience. *Auris Nasus Larynx* 2003; 30: 259-62. [CrossRef]
- Oxford LE, McClay J. Medical and surgical management of subperiosteal orbital abscess secondary to acute sinusitis in children. *Int J Pediatr Otorhinolaryngol* 2006; 70: 1853-61. [CrossRef]
- McKinley SH1, Yen MT, Miller AM, Yen KG. Microbiology of pediatric orbital cellulitis. *Am J Ophthalmol* 2007; 144: 497-501. [CrossRef]
- Younis RT, Anand VK, Davidson B. The role of computed tomography and magnetic resonance imaging in patients with sinusitis with complications. *Laryngoscope* 2002; 112: 224-9. [CrossRef]
- Chaaban MR, Baroody FM, Gottlieb O, Naclerio RM. Blood loss during endoscopic sinus surgery with propofol or sevoflurane: a randomized clinical trial. *JAMA Otolaryngol Head Neck Surg* 2013; 139: 510-4. [CrossRef]
- Kinsella SM. Lateral tilt for pregnant women: why 15 degrees?. *Anaesthesia* 2003; 58: 835-6. [CrossRef]
- Ismi O, Vayisoglu Y, Dinc E, Unal M. Central retinal artery occlusion and irreversible blindness due to paranasal sinus infection in a pregnant woman. *J Craniofac Surg* 2014; 25:e557-9. [CrossRef]