






Intraosseous Mucoepidermoid Carcinoma of the Jaw: Report of Three Cases

Çenenin İntraosseöz Mukoepidermoid Karsinomu: Üç Olgu Sunumu

Bora Başaran¹ , Can Doruk¹ , Eren Yılmaz² , Ecem Sünnetçiöğlü³ , Bilge Bilgiç³ 

¹Department of Otorhinolaryngology, İstanbul University İstanbul School of Medicine, İstanbul, Turkey

²Clinic of Otorhinolaryngology, Bitlis Tatvan State Hospital, Bitlis, Turkey

³Department of Pathology İstanbul University İstanbul School of Medicine, İstanbul, Turkey

Case Report 
Olgu Sunumu

Abstract

Mucoepidermoid carcinoma (MEC) is the most common malignant tumor of the salivary glands and is seen most commonly in the parotid gland. Intraosseous MECs can be rarely seen and is mostly detected in the posterior part of the mandible. This condition can be acknowledged as an entity different from salivary gland MECs. In this case series, we delineated

three patients of intraosseous MEC, two mandible tumors and one maxillary tumor and discussed the diagnostic characteristics and treatment methods of this rare entity.

Keywords: Mucoepidermoid carcinoma, mandibular neoplasms, maxillary neoplasms, salivary gland neoplasms

Öz

Mukoepidermoid karsinom (MEK) tükürük bezlerinin en sık görülen malign tümördür ve en sık olarak parotis glandında gözükür. Çok nadir olarak MEK intraosseöz yerleşimli olarak görülür. Bu nadir durum en sık mandibulada, mandibulanın posteriorunda, görülür ve tükürük bezi MEK'lerinden tamamen farklı bir antitedir. Bu olgu serisinde ikisi mandibula ve biri

maksillada olmak üzere üç intraosseöz mukoepidermoid karsinomlu olguyu sunarken, bu nadir patolojinin tanı kriterleri ve tedavi yöntemlerini gözden geçirdik.

Anahtar kelimeler: Mukoepidermoid karsinom, mandibula neoplazileri, maksilla neoplazileri, tükürük bezi neoplazileri



ORCID IDs of the authors:

B.B. 0000-0003-0251-5895;
C.D. 0000-0002-4983-3666;
E.Y. 0000-0002-5349-9699;
E.S. 0000-0001-9028-4390;
B.B. 0000-0001-9231-1743

Cite this article as: Başaran B, Doruk C, Yılmaz E, Sünnetçiöğlü E, Bilgiç B. Intraosseous Mucoepidermoid Carcinoma of the Jaw: Report of Three Cases. Turk Arch Otorhinolaryngol 2018; 56: 42-6.

Corresponding Author/Sorumlu Yazar:
Can Doruk; can.doruk@istanbul.edu.tr

Received Date/Geliş Tarihi: 09.10.2017

Accepted Date/Kabul Tarihi: 16.11.2017

© Copyright 2018 by Official Journal of the Turkish Society of Otorhinolaryngology and Head and Neck Surgery Available online at www.turkarchotolaryngol.net

© Telif Hakkı 2018 Türk Kulak Burun Boğaz ve Baş Boyun Cerrahisi Derneği Makale metnine www.turkarchotolaryngol.net web sayfasından ulaşılabilir.

DOI: 10.5152/tao.2018.2902

Introduction

Mucoepidermoid carcinoma (MEC) is the most common malignant tumor of the salivary glands and is most commonly seen in the parotid gland; followed by minor salivary glands of the palate, submandibular glands, and sublingual glands consecutively (1). A very rare location of MEC is the jaw bones. The mandible is affected more commonly than the maxilla, and the posterior part of the mandible is the most common location of intraosseous MECs (2-4).

In this report, we present three patients with the diagnosis of intraosseous MEC treated with surgery and a literature review. Informed written consent was obtained from all the patients.

Case Presentations

Case 1

A 48-year-old woman presented to the Dentistry faculty for tooth implantation. Routine pan-

oramic jaw X-ray digital radiography showed an incidental cystic mass at the right alveolar process of the maxilla, which was curetted. The pathology was reported as MEC, and the patient was referred to our clinic for further treatment. A paranasal sinus computed tomography (CT) scan (Figure 1) and a contrast paranasal sinus magnetic resonance imaging (MRI) scan (Figure 2) were performed, which showed a 23×15×19-mm expansive lytic mass making indentations to the maxillary sinus floor and damaging the lateral cortex of the sinus wall.

The patient underwent an inferior partial maxillectomy, and a prefabricated palatal obturator prosthesis was used for the reconstruction. The patient had started oral intake on the first postoperative day and was discharged on the second postoperative day. The final histopathologic examination was reported as a low-grade intraosseous MEC with a Ki-67 value of 19% (Figure 3);

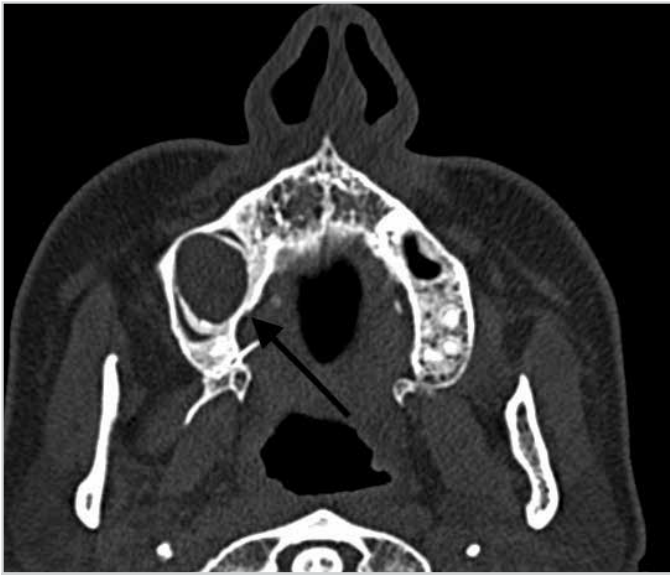

Figure 1. Axial paranasal computed tomography section showing a mass lesion

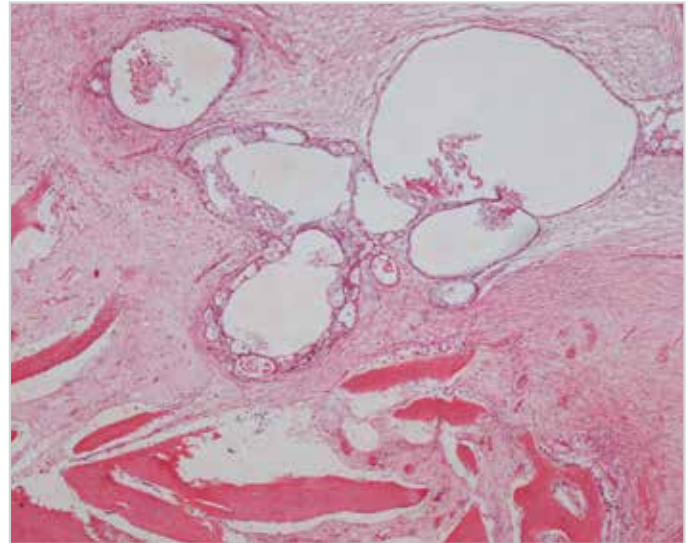


Figure 3. Bone lamellae showing osteoblastic activity and epithelial cells rich in mucin-forming glandular structures in the neighboring fibrous stroma in Case 1 under X4 magnification

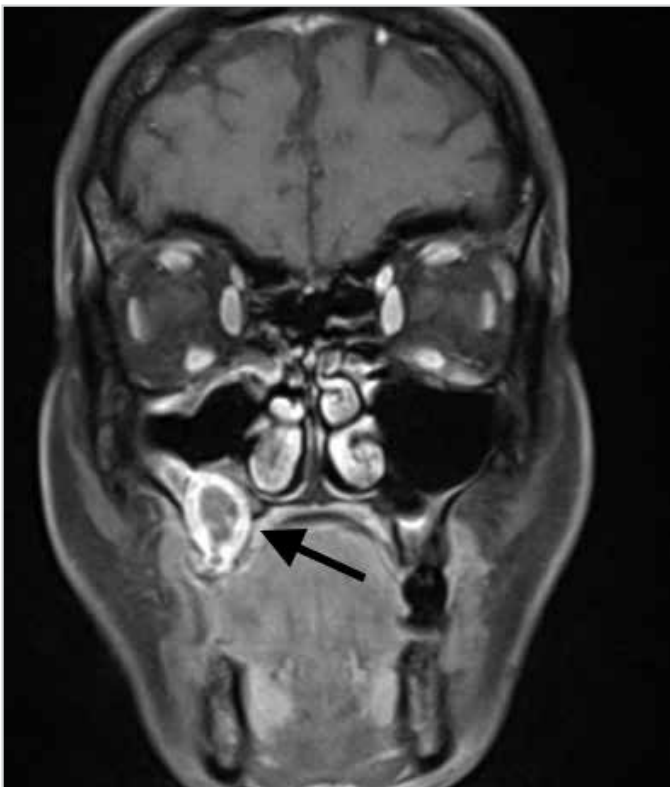

Figure 2. T1-contrasted coronal magnetic resonance imaging section of an expansile lytic mass lesion originating from the maxillary sinus floor

the bony surgical margins were clear, and the patient did not receive any adjuvant therapy. She was free of the disease at the two-year follow-up.

Case 2

A 54-year-old man presented to the Dentistry faculty with jaw pain for five years. Upon physical examination, an expansile mass lesion was found at the ramus of the left mandible, and a biopsy was performed by the dental surgeon. He was referred

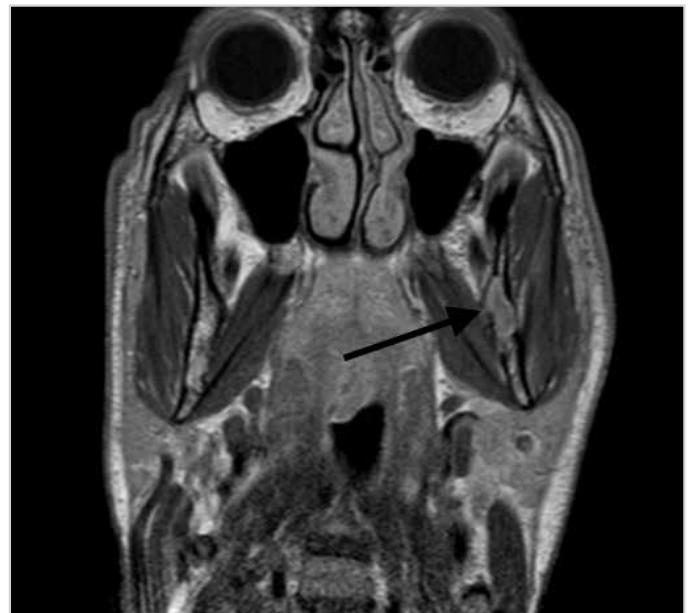

Figure 4. T1-contrasted coronal magnetic resonance imaging section showing a noninvasive cystic mass involving the ramus of the left mandible

to our clinic for further treatment after the histopathologic examination was reported as intraosseous MEC. A contrasted MRI scan showed a noninvasive cystic mass involving both the ramus and angulus portions of the left mandible. (Figure 4) The tumor was resected with a left segmental mandibulectomy and a left supraomohyoid selective neck dissection was performed. Pectoralis muscle myocutaneous flap was used for the reconstruction of the defect. Postoperative histopathology was reported as low-grade intraosseous MEC with a Ki-67 value of 17% (Figure 5). The bony surgical margins were clear, and the patient did not receive any adjuvant therapy. He was decannulated on the seventh postoperative day, and oral feeding was started on the tenth day. He was free of the disease at the three-year follow-up.

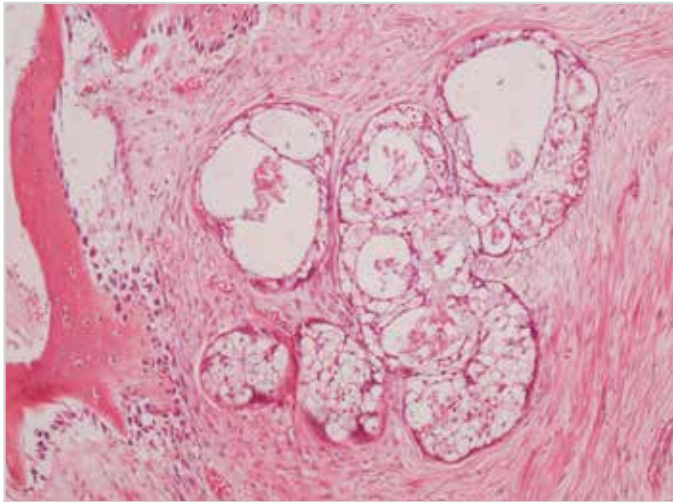


Figure 5. Bone lamellae showing osteoblastic activity and epithelial cells rich in mucin-forming glandular structures in the neighboring fibrous stroma in Case 2 under X10 magnification

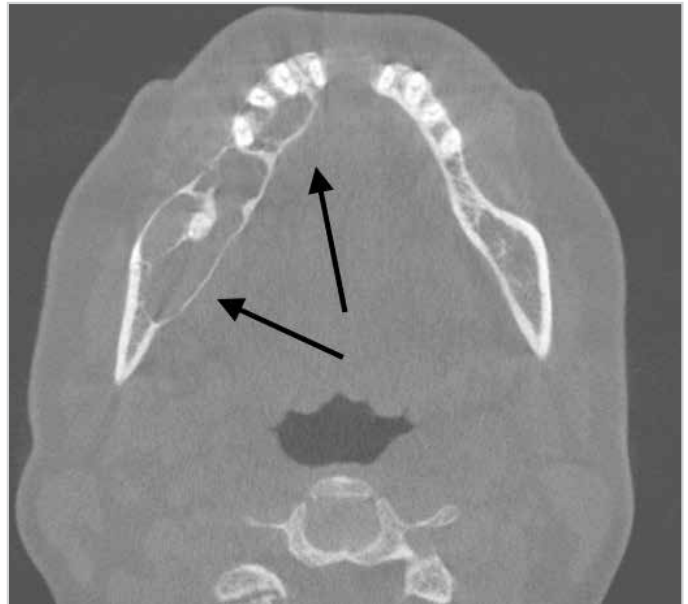

Figure 7. Axial paranasal computed tomography section showing the intraosseous tumor with intact cortical plates

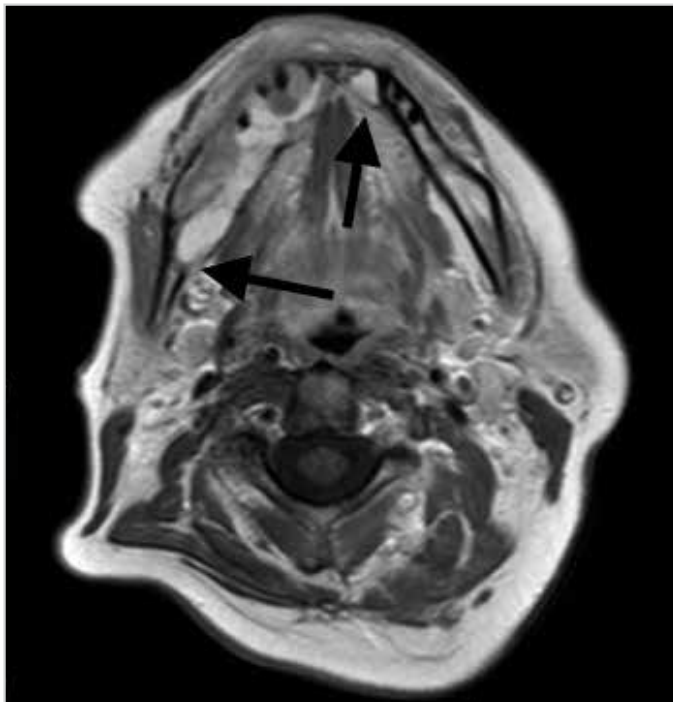


Figure 6. T1-contrasted axial MRI scan showing a mass originating from the symphysis of the mandible extending up to the level of the angle of mandible on the right side and to the left canine tooth on the left side

Case 3

A 49-year-old woman was referred to our clinic from the Dentistry faculty with a diagnosis of intraosseous MEC. The patient had no complaints other than a mass which was encountered after the first right molar tooth removal. MRI and CT scans showed a mass originating from the symphysis of the mandible extending up to the level of angle of mandible on the right side and to the left canine tooth on the left side (Figure 6, 7). The tumor was resected with a subtotal mandibulectomy, and bilateral supraomohyoid selective neck dissection was performed; a fibula osseo-septo-cutaneous free flap was used for the reconstruction. She was decannulated on the fifteenth postoperative day, and oral feeding was started on the sixteenth day. The final

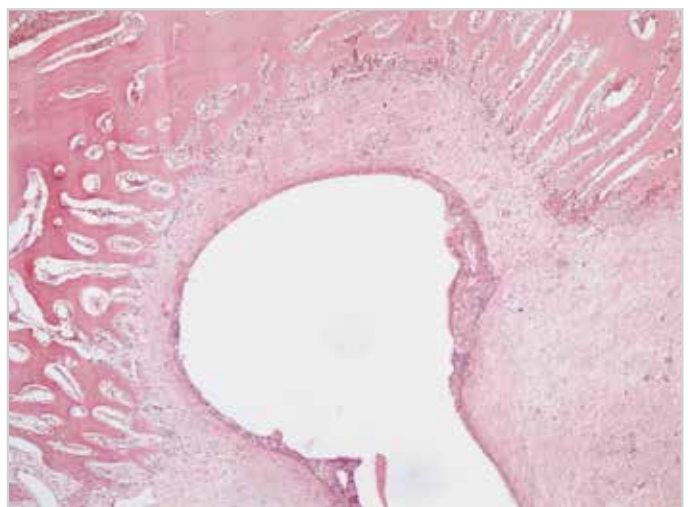


Figure 8. Bone lamellae showing osteoblastic activity and epithelial cells rich in mucin-forming glandular structures in the neighboring fibrous stroma in Case 3 under X4 magnification with H&E stain

histopathologic examination was reported as intraosseous low-grade MEC with a Ki-67 value of 3% and the bony surgical margins were clear. No neck metastasis was observed (Figure 8). She did not receive any adjuvant chemoradiotherapy. She was free of the disease at the two-year follow-up.

Discussion

The mandible, particularly the posterior part, is the most common location of intraosseous MECs. Women are more commonly affected than men, and although the most common age group for this tumor is the fourth and fifth decades, there were patients between the first and seventh decades reported in literature (4-7). In our cases, the distribution of patients was consistent with literature; two patients were women and one was man; two patients had tumors in the mandible and one had the tumor in the maxilla. Furthermore, one of the patients with the

mandibular disease had a tumor at the angle of the mandible, which was also consistent with the literature. However, the other patient had a tumor originating from the symphysis of the mandible, and this is a rare location for this tumor.

The most common symptoms of intraosseous MEC are painless swelling in the oral cavity, pain, paresthesia, numbness, and loose teeth (8). Although one of our patients presented with chronic jaw pain, the other patient was asymptomatic, and the mass was found incidentally during a radiological evaluation of the face for dental implantation. In the third patient, a painless mass was encountered while extracting a non-vital tooth, which was thought to be due to the tumor.

Different from the other oral cavity neoplasms, due to the intraosseous character, diagnosis of such a tumor may be challenging. Routine fine needle aspiration biopsies and incisional or punch biopsies directly from the tumor are often impossible for this type of malignancies. Open biopsies through the bones covering the tumor or true-cut biopsies are necessary for the preoperative histopathological diagnosis. Therefore, diagnostic criteria for intraosseous MEC were defined by Alexander et al. (9) and modified by Browand and Waldron (5) and are as follows: (a) intact cortical plates on CT, (b) radiographic evidence of bony destruction, (c) exclusion of another primary tumor whose metastasis could histologically mimic the central tumor, (d) exclusion of an odontogenic tumor, (e) histopathologic confirmation, and (f) detectable intracellular mucin. Radiologic findings of intraosseous MEC are unilocular or multilocular masses that can be associated with impacted tooth or cysts in 50% of the cases (1). Brookstone and Huvos have prepared a classification system based on the radiographic properties of the tumor, and this classification system is now used for determining the prognosis. According to this classification, the lesions with an intact cortex layer and without any bony expansions are categorized as stage 1 and have the best prognosis. Lesions that expand the bone but do not disturb the integrity of the cortex are stage 2. Lesions that disrupt the integrity of the periosteum or cause cortical perforation with or without nodal involvement and masses with nodal involvement are accepted as stage 3, with the poorest prognosis (8). All of our patients in this study were evaluated using an MRI scan preoperatively and diagnosed with stage 1 disease, and no local recurrence after surgical excision was observed.

Treatment modality of intraosseous MEC is surgical en bloc resection with clear margins, even for low-grade tumors. Recurrence was observed up to 40%-45% of cases, when treated with conservative therapy modalities, such as curettage or enucleation, and thus conservative modalities are not recommended (5, 8, 10). Recurrence rates were reduced to 13% after en bloc tumor resection with clear margins (8). Considering the intraosseous localization of the tumor, it is necessary to perform composite resection of the involved bone with enclosing borders of the tumor. As the most common location of this tumor is mandible, segmental resection of the mandible is necessary in most cases (8, 10). In our cases, one patient with the tumor located

at the symphysis of the mandible underwent subtotal mandibulectomy, and the patient with a lesion at the ramus of the mandible underwent segmental mandibulectomy. The patient with maxillary intraosseous MEC was treated with an inferior partial maxillectomy.

There are two major indications for neck dissection: therapeutic neck dissection should be performed for patients with regional lymph node metastasis, and an elective neck dissection is recommended for patients with high-grade tumors (5, 11, 12). Freije et al. (12) suggested the need of adjuvant radiotherapy only for high-grade tumors. We performed elective neck dissection in both patients with mandibular intraosseous MEC since the preoperative histological grading of the tumor was dubious. For the patient with maxillary MEC, safe margins were achieved with an inferior maxillectomy, and neck dissection was not required. Postoperative histopathology results of all the three patients were low-grade intraosseous MEC, and no regional neck metastasis was observed in two patients. None of the patients had postoperative adjuvant radiotherapy.

Prognosis of salivary gland MEC is associated with the clinical stage and histological grade (10). In contrast, this is not applicable to central MEC. The classification system created by Brookstone and Huvos (5, 8) is the most commonly used method to determine the prognosis. Nevertheless, since there is no real staging method for this tumor, it is not always easy to determine the prognosis. Although the 5-year survival rates for low-grade lesions are up to 95%, this ratio drops to 40% for high-grade tumors. The main reasons for death are uncontrolled local recurrence and brain invasion (5). The rate of regional metastasis is about 9%, and metastasis is seen usually to the ipsilateral neck. Even though these tumors have a good overall prognosis, patients must be followed for long periods due to the high rates of local recurrence and regional metastasis (5, 8, 10). Although our follow-up time was short, no local recurrence or systemic metastasis was observed during the follow-up.

Conclusion

Intraosseous MEC is a rarely seen bone tumor, which cannot be easily differentiated from primary dentigerous tumors of the jaw. When dealing with intraosseous tumors, physicians should be prudent and must consider that the tumor may be malignant and perform a biopsy before any curative therapy.

Informed Consent: Written informed consent was obtained from patients who participated in this study.

Peer-review: Externally peer-reviewed.

Author Contributions: Concept - B.B., B.B.; Design - B.B., E.Y.; Supervision - B.B., B.B.; Resource - C.D., E.S.; Materials - E.S.; Data Collection and/or Processing - E.S., C.D.; Analysis and/or Interpretation - B.B., B.B.; Literature Search - E.Y., C.D.; Writing - E.Y., C.D.; Critical Reviews- B.B., B.B., C.D., E.S., E.Y.

Conflict of Interest: No conflict of interest was declared by the authors.

Financial Disclosure: The authors declared that this study has received no financial support.

Hasta Onamı: Yazılı hasta onamı bu alıřmaya katılan hastalardan alınmıřtır.

Hakem Deęerlendirmesi: Dıř baęımsız.

Yazar Katkıları: Fikir - B.B., B.B.; Tasarım - B.B., E.Y.; Denetleme - B.B., B.B.; Kaynaklar - C.D., E.S.; Gereler - E.S.; Veri Toplanması ve/veya İřlemesi - E.S., C.D.; Analiz ve/veya Yorum - B.B., B.B.; Literatür Taraması - E.Y., C.D.; Yazıyı Yazan - E.Y., C.D.; Eleřtirel İnceleme - B.B., B.B., C.D., E.S., E.Y.

ıkar atıřması: Yazarlar ıkar atıřması bildirmemiřlerdir.

Finansal Destek: Yazarlar bu alıřma iin finansal destek almadıklarını beyan etmiřlerdir.

Kaynaklar

1. Eversole LR. Mucoepidermoid carcinoma: review of 815 reported cases. *Oral Surg Oral Med Oral Pathol* 1970; 28: 490-5.
2. Raut D, Khedkar SA. Primary intraosseous mucoepidermoid carcinoma of the maxilla: a case report and review of literature. *Dentomaxillofac Radiol* 2009; 38: 163-8. [\[CrossRef\]](#)
3. Pires FR, Paes de Almeida O, Lopes MA, Elias da Cruz Perez D, Kowalski LP. Central mucoepidermoid carcinoma of the mandible: Report of four cases with long term follow up. *Int J Oral Maxillofac Surg* 2003; 32: 378-82. [\[CrossRef\]](#)
4. Gingell JC, Beckerman T, Levy BA, Snider LA. Central mucoepidermoid carcinoma. Review of literature and report of a case associated with an apical periodontal cyst. *Oral Med Oral Surg and Oral Pathol* 1984, 57: 436-40. [\[CrossRef\]](#)
5. Waldron CA, Koh ML. Central mucoepidermoid carcinoma of the jaws: report of four cases with analysis of the literature and discussion of the relationship to mucoepidermoid, sialodontogenic, and glandular odontogenic cysts. *J Oral Maxillofac Surg* 1990; 48: 871-7. [\[CrossRef\]](#)
6. Chundru NS, Prasanth T, Nandan S, Rajesh A. Central mucoepidermoid carcinoma. *J Can Res Ther* 2015; 11: 657. [\[CrossRef\]](#)
7. Polat ř, Serin G, Aksoy E, Üneri C. Central mucoepidermoid carcinoma: A case report. *Fırat Tıp Dergisi* 2011; 16: 41-3.
8. Brookstone MS, Huvos AG. Central salivary tumors of the maxilla and mandible: A clinicopathologic study of 11 cases with an analysis of the literature. *J Oral Maxillofac Surg* 1992; 50: 229-36. [\[CrossRef\]](#)
9. Alexander RW, Dupuis RH, Holton H. Central mucoepidermoid tumor (carcinoma) of the mandible. *J Oral Surg* 1974; 32: 541-7.
10. Caccamese JF Jr, Ord RA. Paediatric mucoepidermoid carcinoma of the palate. *Int J Oral Maxillofac Surg* 2002; 31: 136-9. [\[CrossRef\]](#)
11. Waldron CA, Mustoe TA. Primary intraosseous carcinoma of mandible with probable origin in an odontogenic cyst. *Oral Surg Oral Med Oral Pathol* 1989; 67: 716-24. [\[CrossRef\]](#)
12. Freije JE, Campbell BH, Yousif NJ, Clowry LJ Jr. Central mucoepidermoid carcinoma of the mandible. *Otolaryngol Head Neck Surg* 1995; 112: 453-6. [\[CrossRef\]](#)