

Through-and-Through Mattress Suturing Versus Tie-Over Dressing in Full-Thickness Skin Graft Reconstruction

Tam Kat Deri Grefti Rekonstrüksiyonunda Bohça Pansuman Yerine Boydan Boya Matris Sütür Uygulaması

Siew Min Keh¹, Neil Giblett², Syed Farhan Ahsan³

¹Department of Otorhinolaryngology, Raigmore Hospital, Inverness, UK

²Department of Otorhinolaryngology, Queen Elizabeth Hospital, Birmingham, UK

³Department of Otorhinolaryngology, Princess Royal Hospital, Telford, UK

Original Investigation

Özgün Araştırma

Abstract

Objective: To compare the outcomes of securing full-thickness skin grafting (FTSG) with through-and-through mattress suturing versus the classic tie-over and pressure dressing and identify the associated risk factors of graft failure.

Methods: A single-institution, retrospective case series of patients who had undergone excision of head and neck skin lesions requiring FTSG over a 10-year period was reviewed.

Results: In total, 128 FTSG reconstructions were performed. The follow-up period ranged from 1 to 192 weeks. The observed graft take rate was 86.4%.

There was no significant difference in the outcome when the surgical fixation technique was compared. Age, sex, or defect area did not affect the graft take rate. Smoking and the use of anticoagulants were not found to be contributory factors to graft failure.

Conclusion: Simple through-and-through mattress suturing provides adequate graft take, while minimizing tissue handling of the graft and reducing surgical time in comparison to the traditional tie-over and pressure technique.

Keywords: Reconstruction, skin graft, facial plastics

Öz

Amaç: Bu çalışmanın amacı tam kat deri greftinin (TKDG) stabilizasyonunda klasik bohça (tie-over) pansuman yerine boydan boya matris sütür uygulamasını karşılaştırmak ve greft başarısızlığıyla ilişkili risk faktörlerini belirlemektir.

Yöntemler: Bu tek merkezli geriye dönük çalışmada, on yıllık bir periyotta TKDG gerektiren baş ve boyun deri lezyonları eksizyonu yapılan hastalardan oluşan seri incelendi.

Bulgular: Toplam olarak 128 TKDG rekonstrüksiyonu yapıldı. İzlem süresi 1 ile 192 hafta arasında değişti. Greftin kabul oranı %86.4 olarak saptandı. Cerrahi

fiksasyon tekniği karşılaştırıldığında istatistiksel olarak anlamlı bir fark bulunmadı. Yaş, cinsiyet veya defekt alanının greftin kabul edilme oranında etkili faktörler olmadığı tespit edildi. Sigara ve antikoagülan kullanımı ile greft başarısızlığı arasında bir ilişki bulunmadı.

Sonuç: Geleneksel baskılı bohça pansuman tekniği ile karşılaştırıldığında, greft dokusu ile ilgili çalışmayı ve cerrahi süresini azaltarak, basit boydan boya matris sütür uygulaması yeterli greft kabulünü sağlar.

Anahtar kelimeler: Rekonstrüksiyon, deri grefti, yüz plastik cerrahisi



Cite this article as: Keh SM, Giblett N, Ahsan SF. Through-and-Through Mattress Suturing Versus Tie-Over Dressing in Full-Thickness Skin Graft Reconstruction. Turk Arch Otorhinolaryngol 2017; 55: 119-24.

Address for Correspondence/Yazışma Adresi:

Neil Giblett
E-mail: n.giblett@doctors.org.uk

Received Date/Geliş Tarihi: 10.01.2017
Accepted Date/Kabul Tarihi: 26.06.2017
Available Online Date/Çevrimiçi Yayın Tarihi: 16.08.2017

© Copyright 2017 by Official Journal of the Turkish Society of Otorhinolaryngology and Head and Neck Surgery Available online at www.turkarchotorhinolaryngol.org

© Telif Hakkı 2017 Türk Kulak Burun Boğaz ve Baş Boyun Cerrahisi Derneği Makale metnine www.turkarchotorhinolaryngol.org web sayfasından ulaşılabilir.

DOI: 10.5152/tao.2017.2285

Introduction

Full-thickness skin grafting (FTSG) is one of the most popular techniques used to reconstruct an area of skin loss. The success rate is dependent on a thorough understanding of the principle of grafting and good surgical technique by ensuring that the area of the defect is well covered, a healthy blood supply to the recipient site is preserved, and any shearing forces or hematoma formation be-

tween the bed and the graft is reduced. To attain this, many surgeons use the tie-over dressing technique with an emphasis on a "pressure" dressing to achieve successful graft take (1, 2). In recent years, the necessity of applying various ingenious methods in constructing a tie-over dressing on FTSG has been questioned because of comparable results achieved with simple suturing and quilting techniques (3-5). Considering this, local practice of securing FTSG has been modified into a simple

suturing technique by performing a through-and-through mattress suture without the need for any pressure dressing. Therefore, it is considered that securing FTSG with a simple mattress suturing technique is as effective as tie-over fixation and pressure dressings.

The aims of this study were to compare the outcomes of securing FTSG with simple through-and-through mattress suturing versus the conventional tie-over and pressure dressing and identify any associated risk factors of graft failure.

Methods

A single-institution, retrospective case series was reviewed, which included 128 patients over a 10-year period undergoing excision of suspicious skin lesions requiring FTSG. All excised lesions were obtained from the head and neck region under local anesthesia by two consultant surgeons. Three graft donor sites were used for reconstruction; the majority was obtained from the postauricular region and the remainder from either the supraclavicular or the preauricular region. Alternative closure methods were deemed not possible or considered likely to produce poorer cosmetic results. The observed graft take rate and failure rate for both the through-and-through mattress suturing technique and conventional tie-over dressing technique were extracted from patients' medical records. A central quilting suturing technique was used in areas wherein central through-and-through suturing was impossible to fix the graft onto the graft bed (e.g., cheek, forehead, scalp, lip, and temple region). Various parameters, such as age, sex, surface area of defect, presence of multiple comorbidities, smoking status, and use of anticoagulants or immunosuppressants, which may have an impact on the graft take rate, were collated.

The local policy regarding anticoagulants during the inclusion period did not enforce suspension of antiplatelet therapy (aspirin/clopidogrel); however, warfarin treatment was suspended 3-5 days prior to the operation. A preoperative international normalized ratio (INR) check on the day of surgery was performed; procedures were postponed and rescheduled only if INR was >1.4 .

The through-and-through suturing method consisted of interrupted monofilament 4/0 or 5/0 nylon perimeter mattress sutures with a single through-and-through suture in the middle of the graft to fix the graft to the wound base. Small stab incisions were made in the center of the graft to prevent any potential hematoma (Figure 1). Polymyxin/bacitracin ointment (Polyfax) was applied to the wound edge at the end of the procedure and prescribed twice daily during the initial postoperative period (7-14 days). No dressing was required to cover the wound. Postoperative antibiotics were not deemed necessary; therefore, they were not routinely given. The stitches were removed 7 days postoperatively in the Ear, Nose, Throat Outpatient Department (Figure 2). In comparison, patients in the tie-over dressing group had their dressing removed 7 days postoperatively, with a 7-day course of Polyfax ointment twice daily commenced at the time of dressing removal.

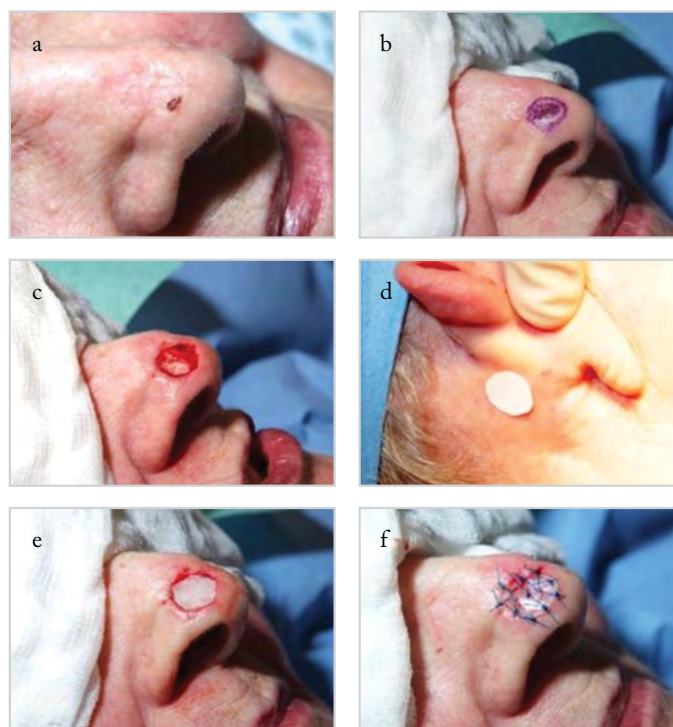


Figure 1. a-f. Intraoperative photographs of through-and-through FTSG suturing. (a) preoperative lesion, (b) excision markings with margins, (c) immediate excision of lesion, (d) postauricular graft planning, (e) placement of full-thickness skin graft, (f) through-and-through suturing of graft

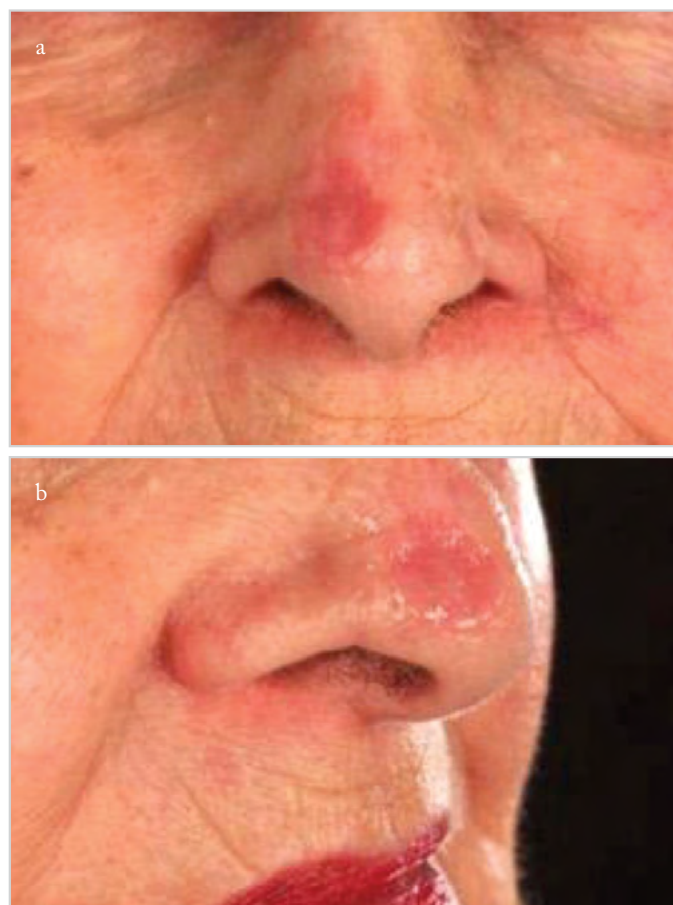

Figure 2. a, b. Postoperative photographs at 2 months. (a) portrait view, (b) oblique view

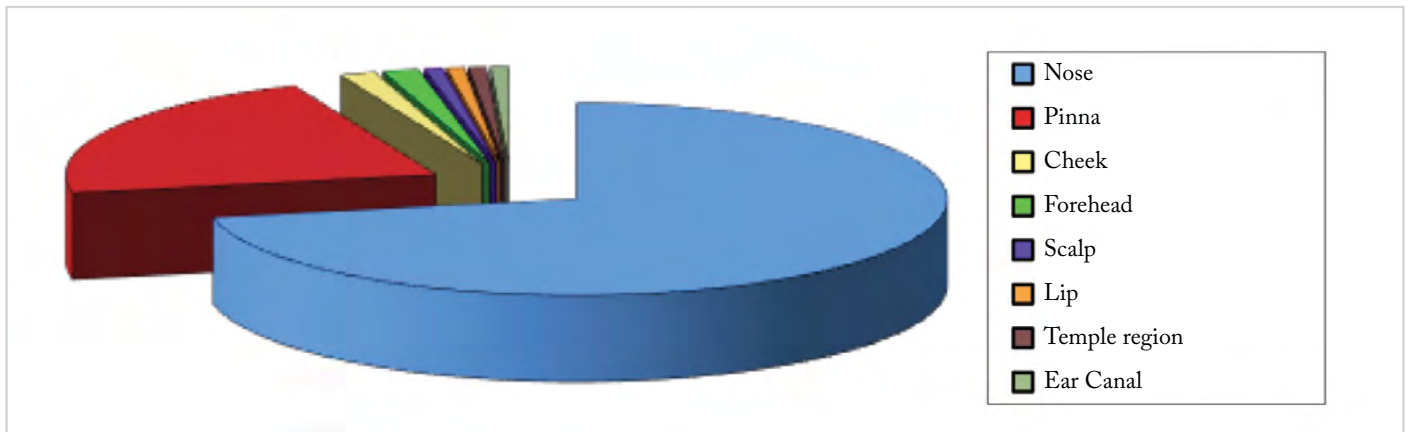


Figure 3. Pie chart to illustrate the graft recipient sites in the case series

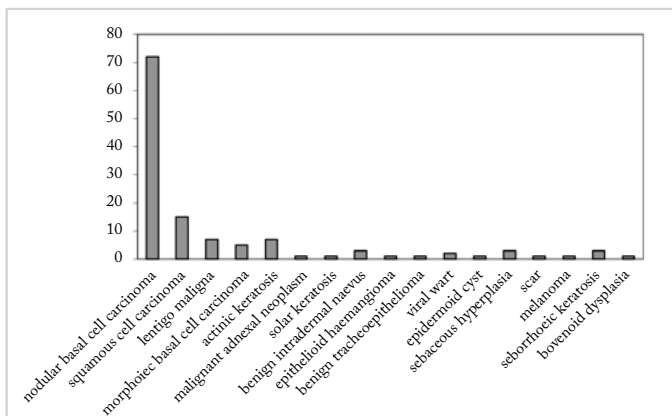


Figure 4. Histopathology of excised lesions (n)

Data were analyzed using the R Foundation for Statistical Computing software (Vienna, Austria, 2008). A univariate analysis was performed to identify potential risk factors of graft failure. A generalized linear model (logistic regression) was applied with respect to each single covariate, wherein the response variable was successful or failed in the treatment. The goodness of fit of this model was compared with that of a model containing only a constant term (e.g., no covariate). The covariate to graft survival was considered statistically significant if p value was <0.05.

This study was regarded as a service evaluation by the local independent research committee, and ethical approval was deemed unnecessary. Patient data remained anonymous throughout and informed consent was gained accordingly.

Results

In total, 128 skin lesions were excised and reconstructed with FTSG from the head and neck regions; nasal lesions were the most common site (Figure 3). Overall, 61.7% of patients were males with a median age of 71 years [standard deviation (SD), ±11.9]; the surgical area defect ranged from 36 to 3600 mm² (median±SD, 187.0±414.7 mm²). Histological diagnosis confirmed most tumors to be nodular basal cell carcinoma (BCC; 57.6%), followed by squamous cell carcinomas (Figure 4). The median follow-up was 10 weeks (range, 1-192 weeks). Three patients failed to attend their follow-up appointments and were

therefore excluded from the analysis. Overall, 100 patients underwent through-and-through mattress suturing and 25 underwent conventional tie-over dressing to secure FTSG. There was no significant difference in sex distribution or patient age between the two groups. The majority of graft donor sites were the postauricular region (92.8%), with the remainder taken from either the supraclavicular (4.8%) or preauricular region (2.4%).

The observed graft take rate was 86.4% (completely taken, 81.6%; partially taken, 4.8%). Complete graft take rate was observed in 82% in patients who underwent through-and-through mattress suturing and 76% in those who underwent conventional tie-over dressing. Partially taken grafts were defined as those with >60% graft take rate. Seventeen of 125 (13.6%) FTSGs failed to take the graft, which were identified at the initial postoperative review; 15 of these FTSGs healed by secondary intention, the remaining two were referred for Plastic surgery for further surgical treatment. No statistical significance was found between surgical techniques for securing FTSG (p=0.75). Age, sex, or defect area did not affect the graft take rate (p=0.72, p=0.13, p=0.20, respectively). In those with failed FTSG, one was an active smoker, nine were ex-smokers (stopped >12 months prior to surgery), and the remaining three were non-smokers. Seven of the 13 patients were taking anticoagulant or antiplatelet therapies, and one patient was on immunosuppressant treatment because of chronic lymphocytic leukemia. None of the variables had any significant effect on the graft failure rate (p>0.05).

Fifteen cases (12%) had incomplete excision of their primary tumor (Table 1). Seven of these cases had a histological diagnosis of BCC, of which five recurred and required further excision. Two patients died before the follow-up was completed (cause of death were unrelated to their neoplastic skin disease).

Discussion

Reconstruction of any facial defect following adequate surgical clearance of tumor can be challenging due to the need for obtaining satisfactory cosmetic result and maintaining the functional purpose. In addition, a high number of these skin lesions present at an advanced stage, particularly among the elderly population as seen in this case series, thus require sacrifice of a significantly larger area of skin to obtain macroscopic clearance (6).

Table 1. Details of incomplete excision cases

	Age (years)	Sex	Anatomical site	Diagnosis	Graft take	Recurrence	Outcome
1	82	M	Nasal tip	BCC	Full	No	Discharge to GP
2	61	F	Nasal tip	BCC	Full	Yes. 2 years 4 months	Re-excision
3	69	M	Pinna	SCC	Full	-	Died of unrelated cause
4	88	M	Forehead	Malignant adnexal neoplasm	Partial	-	Refer for further
5	56	M	Pinna	BCC	Full	No	Discharge to GP
6	83	M	Nasal tip	BCC	Full	No	Discharge to GP
7	83	M	Nasal dorsum	BCC	Full	Yes. 18 months	Re-excision
8	77	M	Pinna	SCC	Full	Yes. 3 months	Subtotal pinnectomy
9	78	M	Nasal tip	Morphoeic BCC	Failed	-	Refer to Plastic surgery for further excision
10	60	M	Nasal alar sidewall	Morphoeic BCC	Full	-	Further excision. Disease free at 5 months review
11	78	M	Nasal tip	BCC	Full	Yes. 1 month	Re-excised and repair with composite graft
12	86	F	Cheek	Lentigo maligna	Full	-	Re-excised. Disease free at 1 year review
13	84	F	Nasal dorsum	SCC	Full	-	Re-excised and disease free at 2 year review
14	68	F	Nasal tip	BCC	Full	Yes. 5 months	Re-excision
15	62	M	Pinna	SCC	Full	-	Re-excised and repair with pedicle flap

M: male; F: female; BCC: basal cell carcinoma; GP: general practitioner; SCC: squamous cell carcinoma

Table 2. Summary of graft takes rate from literature review

	Sample size	Technique	Size of defect	Partial take rate %	Failed %	Complete graft take rate %
Davenport et al. (3) 1988	40	Quilt vs tie-over dressing	-	2.5 (quilt)	2.5 (tie-over)	95
Langtry JA et al. (4) 1998	30	Perimeter suturing with either a light dressing or no dressing	8-43 mm (mean 20 mm) diameter	3.3	3.3	93.3
Mehta HK et al. (5) 1979	109	Central with paracentral sutures	1.2-3.5 cm diameter	0	0	100
Robinson JK et al. (9) 2002	400	Immediate vs delayed grafting	3-5 cm ²	20.5 (30% immediate; 11% delayed)	18 (12.5% immediate; 5.5% delayed)	61.5
Case series 2017	128	Through-and-through vs tie-over dressing	36-3600 mm ²	4.8	13.6	81.6

The majority of skin lesions in this study occurred on the nose, particularly in the nasal tip region, wherein local flap closure was not possible. Fortunately, FTSG in this area provides a favorable cosmetic result, and patients are generally satisfied with the outcome. The majority of grafts harvested in this series were obtained from the postauricular crease for a number of reasons. Firstly, this area was deemed the best skin match to the do-

nor site, particularly with regard to thickness, texture, and color; secondly, a generous piece of tissue could be harvested to cover larger defects; and finally, the donor site itself heals satisfactorily with no cosmetically visible scar or disfigurement.

All methods of securing FTSG to the recipient bed utilize the principle of complete adherence of the graft to its bed until the

union occurs (7). With the tie-over dressing, it is difficult to uniformly distribute the pressure exerted by the bolster on the graft to its recipient bed, particularly when covering a large defect. Facial wounds are also not always amenable for postoperative pressure dressing. For example, external fixation devices cannot be relied upon in wound-on concavities (e.g., medial canthus). The through-and-through mattress suturing technique is an alternative to maintain graft-to-bed approximation while overcoming these challenges. The central fixation with its perimeter suturing enables fixation of the graft to irregular shapes and variable sizes in difficult sites (e.g., nasocanthal region), while assuring constant approximation and immobility of the graft to its bed; additionally, it has been posed that this may reduce infection risk (8).

The aim of this study was to evaluate the clinical outcome of through-and-through mattress suturing of FTSG in the head and neck region in comparison to the traditional techniques, and while this seems locally adequate, it would be reasonable to compare the local practice to outcomes elsewhere. Current literature shows that complete graft take rate in FTSG reconstruction ranges from 70% to 100%; therefore, local outcomes are considered comparable (3-5, 9, 10) (Table 2).

When examining potential factors that may contribute to graft necrosis and therefore graft failure, it was found that none of the variables (age, sex, surface area defect, technique, presence of multiple comorbidities, smoking, and use of anticoagulant or immunosuppressant) were allied to a poorer outcome.

Stephenson et al. (11) found that FTSG applied to the periorbital area and nose contracted more than those applied to the scalp and temple areas, which may result in a poor cosmetic outcome. No differences in contraction were found between the donor sites, methods of fixation, and sex or those taking steroids or non-steroidal anti-inflammatory medication. Out of the 125 cases in this study, three patients (3.2%) were unhappy with their surgical outcome. Three patients had FTSG applied to the nasal tip and one to the nasal ala all four were sutured using the through-and-through method. Further corrective surgery was offered to all four patients, one patient received dermabrasion due to graft hypertrophy, one proceeded to tip augmentation, and the remaining two patients declined further treatment. Short-term recipient-site complications in this study were comparatively lower compared to other centers, and despite an aging population, there were no reported recipient-site wound infections (12).

One-third of the patients in this series were taking aspirin at the time of procedure but this did not have any negative effect on the graft outcome. This contradicts a previous study in which it was found that aspirin intake at the time of surgery to resect cutaneous head and neck lesions, confers a small but statistically increased risk of postoperative hemorrhage (13).

It is believed that a larger defect with larger grafts are more prone to partial failure as these grafts are less easily affixed

uniformly and hence less capable of adequate vascularization. Moreover, the blood supply to the different aesthetic units of the face is also believed to be variable within each subunit (14). This series did not find any correlation between the size of defect and graft take rate. Similarly, no particular recipient area was associated with a better outcome although 11 of the 17 graft failures involved the nasal tip.

The association between cigarette smoking and graft necrosis has also been examined previously, with the incidence of graft necrosis observed in active smokers being reported as three times more frequent compared to a non-smoking population (15, 16). In contrast to these findings, no association between smoking and graft failure was seen among this population, as only one of the 17 patients with graft necrosis was an active smoker.

There was a substantial difference in the population size of the two graft fixation techniques utilized. As this is a retrospective review, patients were not randomized into the two treatment groups equally and local practice favored the through-and-through technique. Incidentally, these two patient groups had similar demographics with an equal male:female ratio. The other limitation in the retrospective design of this study is the simultaneous presence of other variables (e.g., defect size and aspirin use) that may affect the analysis of the effects of one variable (e.g., technique) on the clinical outcome.

Conclusions

The tie-over pressure dressing does not appear essential for FTSG survival in the areas of the head and neck that were studied. The through-and-through mattress suturing technique therefore provides a suitable alternative that offers favorable outcomes in addition to minimizing tissue handling of the graft and reducing operative time.

This study failed to highlight any significant risk factors associated with graft failure; however, the authors advise caution in smoking and anticoagulant groups, and all patients should be informed accordingly.

Ethics Committee Approval: This study was exempt from the ethics committee approval by the local independent research committee.

Informed Consent: Written informed consent was obtained from patients who participated in this study.

Peer-review: Externally peer-reviewed.

Author Contributions: Concept - S.F.A.; Design - S.F.A., S.M.K.; Supervision - S.F.A.; Materials - S.F.A.; Data Collection and/or Processing - S.M.K.; Analysis and/or Interpretation - S.M.K., N.G.; Literature Search - S.M.K., N.G.; Writing - S.M.K., N.G.; Critical Reviews - S.F.A., N.G.

Conflict of Interest: No conflict of interest was declared by the authors.

Financial Disclosure: The authors declared that this study has received no financial support.

Etik Komite Onayı: Bu çalışma, yerel bağımsız araştırma komitesi tarafından etik komite onayından muaf tutulmuştur.

Hasta Onamı: Yazılı hasta onamı bu çalışmaya katılan hastalardan alınmıştır.

Hakem Değerlendirmesi: Dış bağımsız.

Yazar Katkıları: Fikir - S.F.A.; Tasarım - S.F.A., S.M.K.; Denetleme - S.F.A.; Gereçler - S.F.A.; Veri Toplanması ve/veya İşlemesi - S.M.K.; Analiz ve/veya Yorum - S.M.K., N.G.; Literatür Taraması - S.M.K., N.G.; Yazıyı Yazan - S.M.K., N.G.; Eleştirel İnceleme S.F.A., N.G.

Çıkar Çatışması: Yazarlar çıkar çatışması bildirmemişlerdir.

Finansal Destek: Yazarlar bu çalışma için finansal destek almadıklarını beyan etmişlerdir.

References

1. Blair VP. The full thickness skin graft. *Ann Surg* 1924; 80: 298-324. [CrossRef]
2. Greeley PW. The full-thickness skin graft. *Plast Reconstr Surg* 1952; 9: 64-7.
3. Davenport M, Daly J, Harvey I, Griffiths RW. The bolus tie-over "pressure" dressing in the management of full thickness skin grafts. Is it necessary? *Br J Plast Surg* 1988; 41: 28-32. [CrossRef]
4. Langtry JA, Kirkham P, Martin IC, Fordyce A. Tie-over bolster dressings may not be necessary to secure small full thickness skin grafts. *Dermatol Surg* 1998; 24: 1350-3. [CrossRef]
5. Mehta HK. A new method of full thickness skin graft fixation. *Br J Ophthalmol* 1979; 63: 125-8. [CrossRef]
6. Dhiwakar M, Khan NA, McClymont LG. Surgery for head and neck skin tumors in the elderly. *Head Neck* 2007; 29: 851-6. [CrossRef]
7. Salasche SJ, Egan CA, Gerwels JW. Surgical pearl: use of a sponge bolster instead of a tie-over bolster as a less invasive method of securing full-thickness skin grafts. *J Am Acad Dermatol* 1998; 39: 1000-1. [CrossRef]
8. Atherton D, Sreetharan V, Mosahebi A, Prior S, Willis J, Bishop J, et al. A randomised controlled trial of a double layer of Allevyn™ compared to Jellonet and proflavin as a tie-over dressing for small skin grafts. *J Plast Reconstr Aesthet Surg* 2008; 61: 535-9. [CrossRef]
9. Robinson JK, Dillig G. The advantages of delayed nasal full-thickness skin grafting after Mohs micrographic surgery. *Dermatol Surg* 2002; 28: 845-51. [CrossRef]
10. Dhillion M, Carter CP, Morrison J, Hislop WS, Currie WJ. A comparison of skin graft success in the head & neck with and without the use of a pressure dressing. *J Maxillofac Oral Surg* 2015; 14: 240-2. [CrossRef]
11. Stephenson AJ, Griffiths RW, La Hausse-Brown TP. Patterns of contraction in human full thickness skin grafts. *Br J Plast Surg* 2000; 53: 397-402. [CrossRef]
12. Leibovitch I, Huilgol SC, Richards S, Paver R, Selva D. The Australian mohs database: short-term recipient-site complications in full-thickness skin grafts. *Dermatol Surg* 2006; 32: 1364-8. [CrossRef]
13. Dhiwakar M, Khan NA, McClymont LG. Surgical resection of cutaneous head and neck lesions: does aspirin use increase hemorrhagic risk? *Arch Otolaryngol Head Neck Surg* 2006; 132: 1237-41. [CrossRef]
14. Silapunt S, Peterson SR, Alam M, Goldberg LH. Clinical appearance of full-thickness skin grafts of the nose. *Dermatol Surg* 2005; 31: 177-83. [CrossRef]
15. Goldminz D, Bennett RG. Cigarette smoking and flap and full-thickness graft necrosis. *Arch Dermatol* 1991; 127: 1012-5. [CrossRef]
16. Kinsella JB, Rassekh CH, Wassmuth ZD, Hokanson JA, Calhoun KH. Smoking increases facial skin flap complications. *Ann Otol Rhinol Laryngol* 1999; 108: 139-42. [CrossRef]