

Defect Reconstruction of the Nose After Surgery for Nonmelanoma Skin Cancer: Our Clinical Experience

Melanom Dışı Cilt Kanseri Cerrahisi Sonrası Burun Defektlerinin Onarımı: Klinik Tecrübemiz

Original Investigation
 Özgün Araştırma

İsa Kaya, Mustafa Uslu, Fazıl Apaydın

Department of Otorhinolaryngology, Ege University School of Medicine, İzmir, Turkey

Abstract

Objective: This study aimed to investigate reconstruction methods according to nasal subunits in patients who were surgically treated with diagnosis of non-melanoma skin cancer of the nose.

Methods: All patients were retrospectively investigated. This study was conducted between April 2004 and December 2010; 180 patients who were surgically treated with diagnoses of skin basal cell carcinoma, squamous cell carcinoma, cancer of skin appendages, and precancerous lesions and 194 lesions were included. The types of repair performed were divided into seven main groups: Secondary healing, primary closure, skin graft, local flap, auricular composite graft, subtotal reconstruction and prosthesis application.

Results: Among the 180 patients, 110 (61.1%) were males and 70 (38.9%) were females. The mean duration of follow-up was 39.8 (range, 32-81) months. Repair was by a

local flap, a primary suture, a skin graft, and an auricular composite graft in 133, 16, 38, and 2 defects, respectively. Four defects were left for secondary healing. A prosthesis was applied to one patient. Totally, 194 defects were treated by surgery.

Conclusion: Although nonsurgical treatment options such as radiotherapy or cryotherapy may be effectively used, surgery is the main treatment option for cancer of the nasal skin. Nasal subunits have distinct characteristics; thus, optimal reconstruction should be preferred for each subunit. The objective of the reconstruction is not only closing the defect. Closing the defect appropriately with the optimal flap and in proper with the aesthetic subunits is the most important point in reconstruction of the nose.

Keywords: Cancer of nose, skin cancer, reconstructive surgical procedures, basal cell carcinoma

Öz

Amaç: Bu çalışmada cerrahi ile tedavi edilen melanom dışı burun cilt kanserli hastalarda nazal alt ünitelere göre rekonstrüksiyon yöntemlerini araştırmak amaçlandı.

Yöntemler: Bütün hastalar geriye dönük olarak araştırıldı. Bu çalışma Nisan 2004-Aralık 2010 arasında yapıldı ve cilt bazal hücreli kanseri, skuamöz hücreli kanseri, deri eki kanserleri ve prekanseröz lezyonlar nedeniyle cerrahi yöntemlerle tedavi edilen 180 hasta ve 194 lezyon çalışmaya dahil edildi. Uygulanan onarım yöntemleri yedi ana gruba ayrıldı: Sekonder iyileşme, primer kapama, cilt grefti, lokal flep, aurikuler kompozit greft, subtotal rekonstrüksiyon ve protez uygulaması.

Bulgular: 180 hastadan 110'u (%61.1) erkek, 70'i (38.9%) kadın hastaydı. Ortalama izlem süresi 39.8 (32-81) aydı. Onarım lokal flep, primer sütür, cilt grefti ve aurikuler kom-

pozit greft ile sırasıyla 133, 16, 38 ve iki defekt için gerçekleştirildi. Dört defekt sekonder iyileşmeye bırakıldı. Bir hastada total protez kullanıldı. Toplamda 194 defekt cerrahi ile tedavi edildi.

Sonuç: Burun cildinin kanserlerinde radyoterapi, kriyoterapi gibi cerrahi dışı tedavi yöntemleri etkili bir şekilde kullanılabilirse de cerrahi temel tedaviyi oluşturur. Burun alt üniteleri farklı cilt özellikleri taşır, bu nedenle her alt ünite için optimal rekonstrüksiyon yöntemi seçilmelidir. Onarımın amacı defekti sadece kapatmak değildir. Defekti uygun şekilde ve estetik alt ünitelere uygun şekilde, uygun fleple kapatmaktır.

Anahtar kelimeler: Burun kanseri, cilt kanseri, rekonstrüksiyon, bazal hücreli kanser

Introduction

Although basal cell carcinoma (BCC) is the most common skin cancer, squamous cell carcinoma (SCC), basosquamous carcinoma, and malignant

melanoma are other frequent types (1). The course of malignant melanoma is more aggressive than that of the others, and it has a different clinical picture. Therefore, in general, skin cancers can be



Cite this article as: Kaya İ, Uslu M, Apaydın F. Defect Reconstruction of the Nose After Surgery for Nonmelanoma Skin Cancer: Our Clinical Experience. *Turk Arch Otorhinolaryngol* 2017; 55: 111-8.

Address for Correspondence/Yazışma Adresi:

Mustafa Uslu
 E-mail: drmustafauslu@gmail.com

Received Date/Geliş Tarihi: 16.04.2017

Accepted Date/Kabul Tarihi: 17.07.2017

© Copyright 2017 by Official Journal of the Turkish Society of Otorhinolaryngology and Head and Neck Surgery Available online at www.turkarchotorhinolaryngol.org

© Telif Hakkı 2017 Türk Kulak Burun Boğaz ve Baş Boyun Cerrahisi Derneği Makale metnine www.turkarchotorhinolaryngol.org web sayfasından ulaşılabilir.

DOI: 10.5152/tao.2017.2513

divided into two types: 1) melanoma and 2) nonmelanoma skin cancer (NMSC). BCC, SCC, basosquamous carcinoma, and other rare subtypes such as Merkel cell carcinoma, cutaneous lymphoma, and Kaposi sarcoma are included under NMSC (2).

Basal cell carcinoma includes nodular, superficial, infiltrative and micronodular subtypes (2). Superficial and nodular BCCs have low rates of recurrence, while infiltrative and micronodular subtypes are more frequently associated with recurrence (1). Nodular BCC is most frequently seen (3).

The face is divided into well-defined subunits. The nose, cheek, ear, forehead, periocular region, temporal region, and mental region are the facial subunits. The nose is the unit where head and neck NMSCs are most frequently seen. The reason for this is that, this part of the face is more intensely exposed to the sun. According to the National Comprehensive Cancer Network (NCCN), recurrence rates of skin cancers seen in the nose and periocular and periauricular regions are higher compared with M area such as cheeks, forehead scalp neck and L area such as trunk, extremities (4).

Sunlight has the most powerful effect on the development of NMSC. Chronic exposure to sunlight increases the risk of skin cancer to a great extent. Therefore, the incidence of skin cancer increases in individuals working outdoors for long hours and in individuals who work outdoors professionally (such as farmers). In addition, the longer the duration of sun exposure, the higher the incidence of the disease (risk increase, 1.47-fold in >45 years BCC and 3.5-fold SCC) (5, 6).

Primary treatment for NMSC is surgery; however, some effective nonsurgical methods also exist (7-10). The primary aim of surgery is adequate resection of the tumor, while the secondary aim is reconstruction of the defect (11). The repair of defects varies according to the time when repair is performed, the region and size of the defect, and the characteristics of the surrounding skin. The best esthetic and functional results are obtained in the repair of defects included in the same subunit. Further, fitting of the incision and junction lines to the tension lines of the skin provides successful esthetic results (12). While local flaps can be used for repairing defects with larger sizes, skin grafts, particularly in patients with advanced age, and primary closure for repairing small defects can also be used. Free flaps can be used for repairing very big defects (13). Repairing nasal skin defects is even more difficult as it is the most attractive subunit and its functional importance is greater than that of other facial subunits. Primary repair can also be used in the skin of the nose for small defects, while leaving the area for secondary healing or using skin grafts are other options. Local flaps can also be used for repairing large defects or defects including more than one nasal subunit. Some of these flaps are nasolabial flaps, paramedian forehead flaps, bilobed flaps, and glabellar flaps (13).

Several methods have been reported for treating NMSC and repairing defects. This study aimed to evaluate some of these methods used for repairing nasal skin defects and the efficacy of

different methods and share our results of the management of nonmelanoma skin cancer of the nose.

Methods

This study was conducted between April 2004 and December 2010; 180 patients who were surgically treated with diagnoses of skin BCC, SCC, cancer of skin appendages, and precancerous lesions and 194 lesions were included. Eight patients who were nonsurgically treated were excluded. The study was approved by the Ethics Committee of the university. Demographic characteristics, histopathological examination results, surgical methods applied, and tumor and defect localizations were retrospectively evaluated and noted. Simultaneous tumors in different nasal subunits were detected in four of the 180 patients and were treated in the same session. New tumors were detected in different nasal subunits during the follow-up in six patients, and they were treated. Recurrence was found in five (2.8%) patients, and re-intervention was performed in four of them. One patient with recurrence underwent three distinct surgical excisions due to the detection of recurrence, and two distinct reconstruction methods were performed in three patients in two sessions. One-hundred ninety-four lesions were detected in the 180 patients, and surgical interventions and reconstruction methods were performed. Tumors were detected in different facial subunits in 18 (10%) of the 180 patients, and they were treated in the same session. Local anesthesia and general anesthesia were used to excise 165 (85.1%) and 29 (14.9%) lesions, respectively.

All patients were photographed by the same professional medical photographer prior to and after surgery. No informed consent was obtained from the patients as this was a retrospective study; however, all patients signed informed consents for the use of photographs in medical publications and the literature prior to surgery.

Reconstruction was planned in all patients prior to surgery; drawings were done on the patients, and these were photographed using a ruler. Local anesthesia, including 1% lidocaine and 1:100.000 epinephrine for vasoconstriction and hydrodissection, was used in the planned region prior to surgical field sterilization. Following surgical field sterilization, excision and the repair method that was previously planned were performed. BCC and SCC were excised by the classic excision method with 3-5 mm and 8-10 mm margins, respectively. Reconstruction was delayed for a month in patients with a large defect to reduce the size of the defect and in patients who did not wish to undergo immediate repair. The planned reconstruction method was performed after the defect decreased in size. In some patients, the defect was left for secondary repair. Sutures were removed in 7 or 10 days depending on the tension of the wound in patients undergoing repair.

The types of repair performed were divided into seven main groups: secondary healing, primary closure, skin graft, local flap, auricular composite graft, subtotal reconstruction, and prosthesis application.

Follow-up visits were performed every 3, 6, and 12 months in the first year, every six months in the second year, and every 12 months in the third to fifth years. During each visit, photographs of the patients were taken in addition to performing their general examination.

Results

Among the 180 patients, 110 (61.1%) were males and 70 (38.9%) were females. Their mean age was 63.8 (range, 29-88) years. The mean follow-up period was 39.8 (range, 32-81) months. Totally, 163 lesions (84%) were diagnosed to be BCC, 19 to be SCC (9.8%), seven (3.6%) to be basosquamous carcinoma, three (1.6%) to be actinic keratosis, and two (0.1%) to be keratoacanthoma. Among the 194 lesions that were surgically treated, surgical margins were found to be positive in 12 (6.2%) and one of those recurred during the follow-up. Localization of the lesions was to the right half of the nose in 79 (40.7%) lesions and to the left half of the nose in 64 (33%) lesions, and 51 (26.3%) lesions were located at the midline. Histopathologic diagnosis of tumors among nasal subunits is summarized in Table 1.

Reconstruction was performed using a local flap, primary suture, skin graft, and auricular composite graft in 133, 16, 38, and two defects, respectively. Four defects were left for secondary healing. Prosthesis was applied in one patient as the defect involved all nasal subunits. A paramedian forehead flap was used in 19 defects (Figure 1). Tumors with cartilage destruction were present in all patients who had a paramedian forehead flap. The nasal roof was reconstructed using cartilage grafts during the reconstruction of defects following the resection of the lesions. In addition, cartilage grafts were used as the supportive tissue under the flap in nine lesions in which limited cartilage destruction with a small size was present in the nasal tip and ala nasi. Twenty-four cartilage grafts were taken from the concha auricularae; the septal cartilage was used as the supportive structure in three patients, and the costal cartilage was used due to the width of the defect in one patient. Flap pedicle was cut under local anesthesia in the fifth postoperative week in patients who received a paramedian forehead flap. Necrosis developed at the distal part of the flap in one patient who received a forehead flap, and it was resolved by debridement and wound care with frequent dressing changes. Other flaps used are listed according to the nasal subunits in Table 2.

Skin grafts were used in four patients. In these patients, sutures were used to approximate wound edges, and the graft was ap-

Table 1. Distribution of the pathology among nasal subunits

| Nasal subunit | BCC (n=163) (%) | SCC (n=19) (%) | Other (n=12) (%) |
|----------------|-----------------|----------------|------------------|
| Alar region | 48 (24.7) | 6 (3.1) | 2 (1.1) |
| Nasal sidewall | 40 (20.8) | 4 (2.1) | 3 (1.5) |
| Nasal dorsum | 35 (18.1) | 5 (2.6) | 3 (1.5) |
| Nasal tip | 35 (18.1) | 3 (1.5) | 2 (1.1) |
| Columella | 5 (2.6) | 1 (0.1) | 2 (1.1) |

BCC: basal cell carcinoma; SCC: squamous cell carcinoma; Other: actinic keratosis and keratoacanthoma

plied after two weeks. During this period, the wound was filled with granulation tissue (Figure 2).

Bilobed flaps were used in defects smaller than two cm. Although glabellar advancement flaps that were used in 16 patients necessitated dissection in a larger area, they left lesser scar tissue during the postoperative period because the incisions were suitable with the esthetic subunits and relaxed skin tension lines in repair using this type of flap. Malar advancement flaps were used in the reconstruction of nine defects with diameters of up to two cm in the sidewall and three defects in ala nasi extending to the sidewalls. Patients with these defects were mostly elderly and had high skin elasticity. Further, island flaps were used in the reconstruction of five defects with a diameter of less than two cm in the sidewalls. An anchor flap was used in the repair of a defect with a diameter of 1.5 cm at the nasal tip.

Primary repair was used in four of 50 lesions in the nasal sidewall and in 12 of 44 lesions in the nasal dorsum. None of these defects were larger than 1 cm.

Reconstruction methods according to the regions are summarized in Figure 3.

Discussion

Skin cancers are the most common cancers and are most frequently localized to the head and neck region (14). Recently, their incidence has been gradually increasing (15). Sunlight is the most effective and recognized cause (16). Therefore skin cancers are very frequently seen in individuals working in conditions with increased sun exposure (16). Skin cancer is most frequent among farmers (17). Its incidence increases with age (5, 6). In a study conducted by Cakir et al. (18) 4% and 8% of people older than 40 and 70 years, respectively, were diagnosed with skin cancer. The findings of that study such as a mean age of 63.8 years and 69 patients being farmers support literature data. However, actinic keratosis was seen in a 29-year-old patient. The course is known to be more aggressive, and they tend to be multiple in patients who are younger than 40 and the recurrence rate increases in skin cancers among this population (18). In addition, familial ten-

Table 2. Distribution of flaps among nasal subunits

| Flap | Nasal dorsum | Alar region | Nasal tip | Sidewall | Columella | Total |
|----------------------------|--------------|-------------|-----------|----------|-----------|-------|
| Bilobed flap | 5 | 7 | 13 | 6 | 0 | 31 |
| Nasolabial flap | 0 | 34 | 0 | 1 | 3 | 38 |
| Glabellar advancement flap | 12 | 1 | 2 | 1 | 0 | 16 |
| V-Y advancement flap | 0 | 0 | 0 | 8 | 0 | 8 |
| Malar advancement flap | 0 | 3 | 0 | 9 | 0 | 12 |
| Island flap | 0 | 0 | 0 | 8 | 0 | 8 |
| Anchor flap | 0 | 0 | 1 | 0 | 0 | 1 |
| Paramedian forehead flap | 6 | 5 | 4 | 4 | 0 | 19 |

BCC: basal cell carcinoma; SCC: squamous cell carcinoma; Other: actinic keratosis and keratoacanthoma

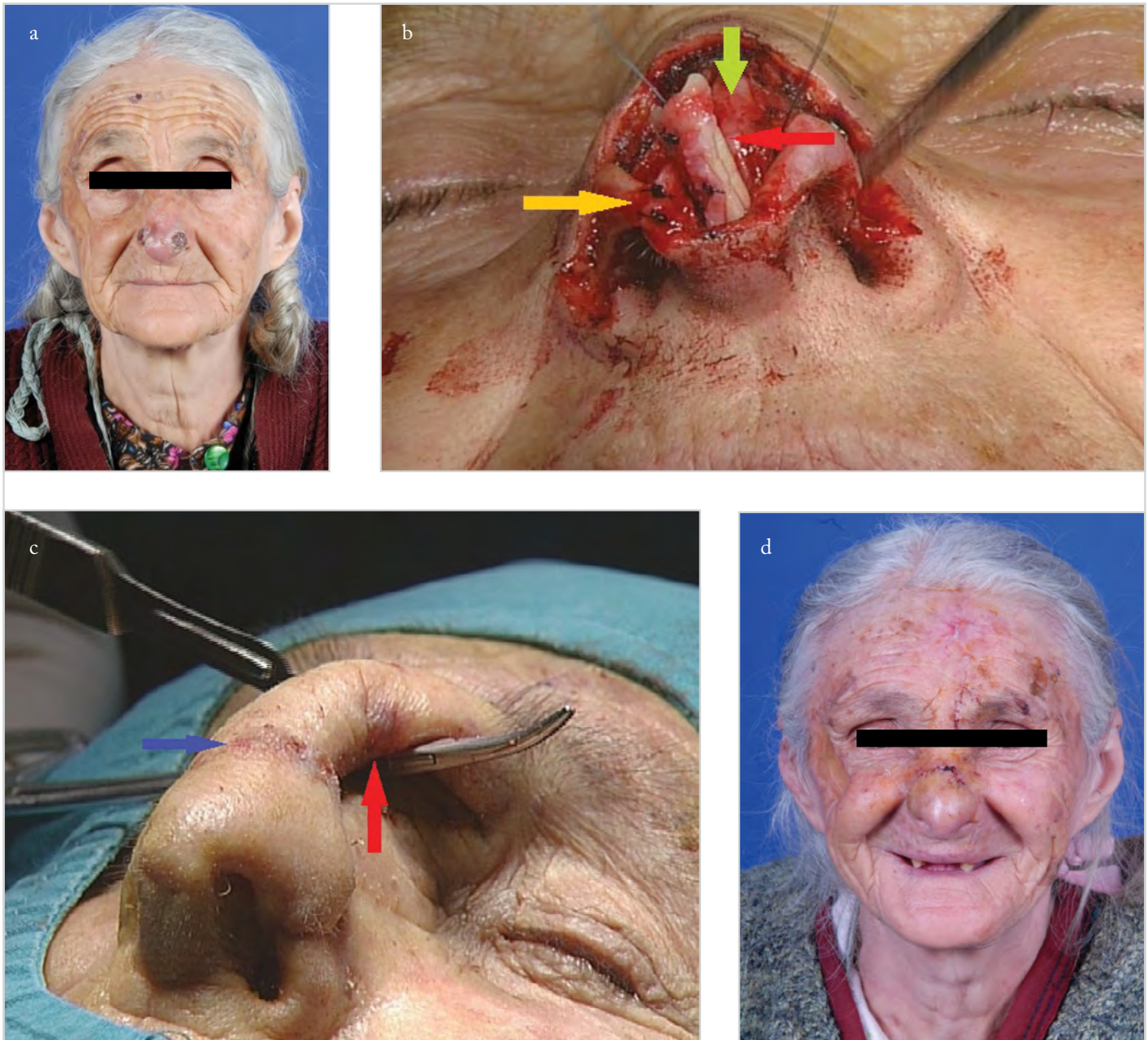

Figure 1. a-d. A patient who had widespread squamous cell carcinoma in the nasal tip and supratip region. A paramedian forehead flap was used for reconstruction. (a) Frontal view of the patient and lesion; (b) After tumor excision and the usage of a septal graft as a strut graft; the red arrow indicates the septal extension graft and strut graft, the green arrow indicates the remaining cartilage septal dorsum, and yellow arrow indicates the reconstructed right alar cartilage; (c) Cutting of the paramedian forehead flap pedicle; the red arrow indicates the pedicle of the flap, and the blue arrow indicates the upper limit of the defect; (d) Two months after pedicle division

dency to skin cancer is more prevalent, particularly in BCC (19, 20). In our study actinic cheilitis was found in one patient at the age of 29. Although BCC was not found in this patient, actinic keratosis carries a risk of skin cancer in the future. Other than the above-mentioned data, 61.1% of the patients included in the present were males. Buettner and Raasch (21) and, Leiter and Garbe (22) found that life-long risk of BCC was 33-39% in men and 23-28% in women, while the corresponding values for life-long risk of SCC were 9-14% and 4-9% in men. The values found in this study support those found in previous studies (21, 22).

The most commonly seen NMSC is BCC (80%), which is followed by SCC (10%) (22). BCC is most frequently seen in the

skin of the head and neck (24). The values of BCC and SCC were 82.7% and 9.9%, respectively, in our study and this finding was similar with findings in the literature.

As the nose is one of the most remarkable facial structures, nasal deformities and scars are rarely accepted by individuals. Therefore, the repair of defects following surgical excision is particularly important in the nasal region. The first point to be considered in the treatment of cancer is to completely excise the lesion and not to limit the excision of the lesion considering the repair method because the primary goal is to completely excise the tumor and not to close the defect (11). Prior to surgery, various methods should be considered to repair defects. Following this priority, a region

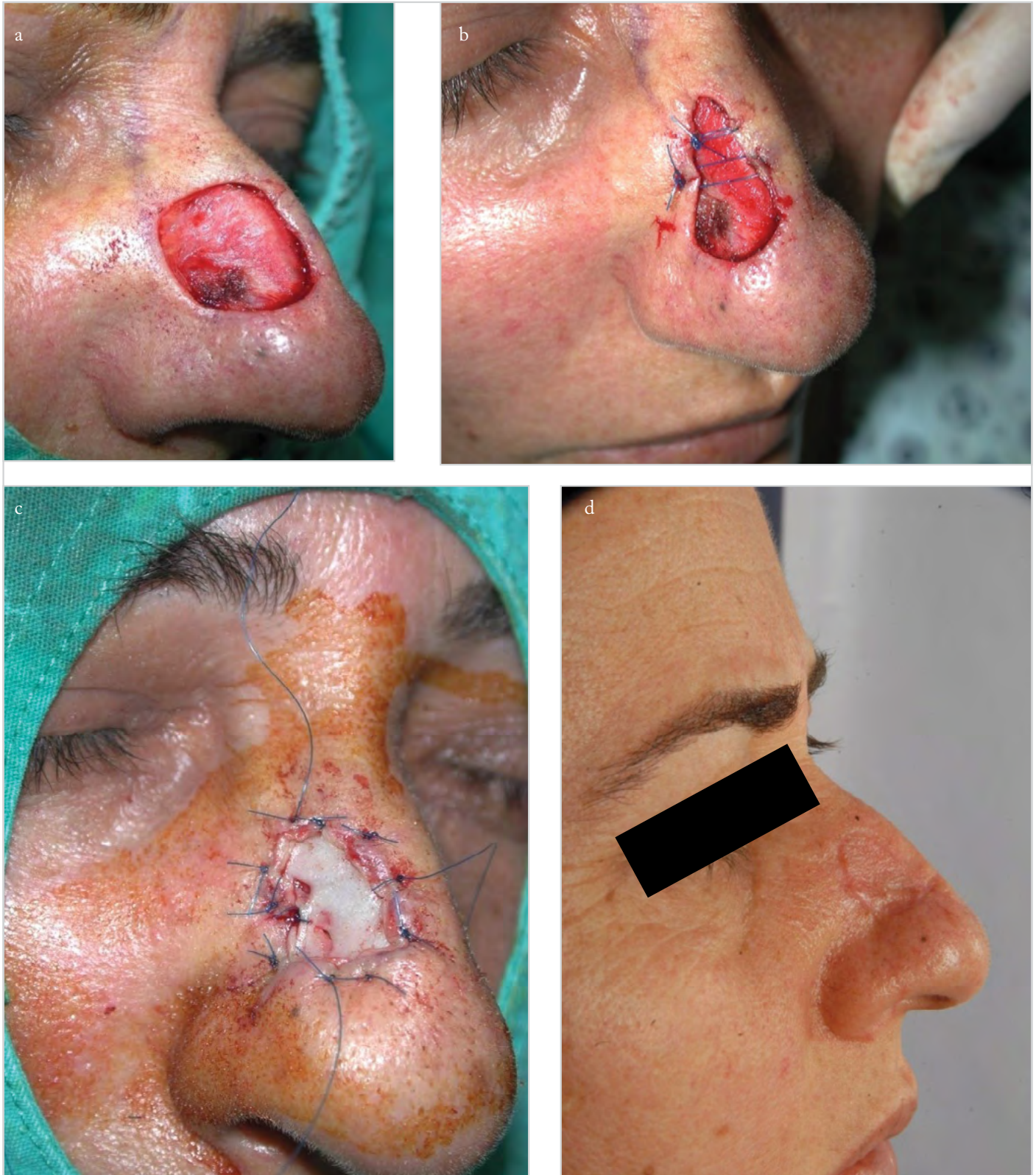

Figure 2. a-d. Basal cell carcinoma involving the nasal sidewall. (a) After tumor excision, the defect was seen; (b) A nonabsorbable suture was used to reduce the size of the defect; (c) A skin graft was used after defect reduction; (d) Four months after skin grafting

in a similar quality which has excess tissue as much as possible should be determined to repair the defect and an appropriate flap should be selected that complies with basic techniques (12). The preferred flap should show good functional and esthetic results and should be applied with the simplest appropriate technique. Thus, in general, local flaps are considered for repairing nasal de-

fects. Using partial-thickness or full-thickness skin grafts in place of a complex flap that may be unfamiliar to the surgeon might be a good alternative in some cases. The main advantage of local flaps is the similarity of the skin properties of the defect site and donor site. Moreover, wound contraction is less commonly seen during healing (12, 13). Therefore, using flaps more commonly in

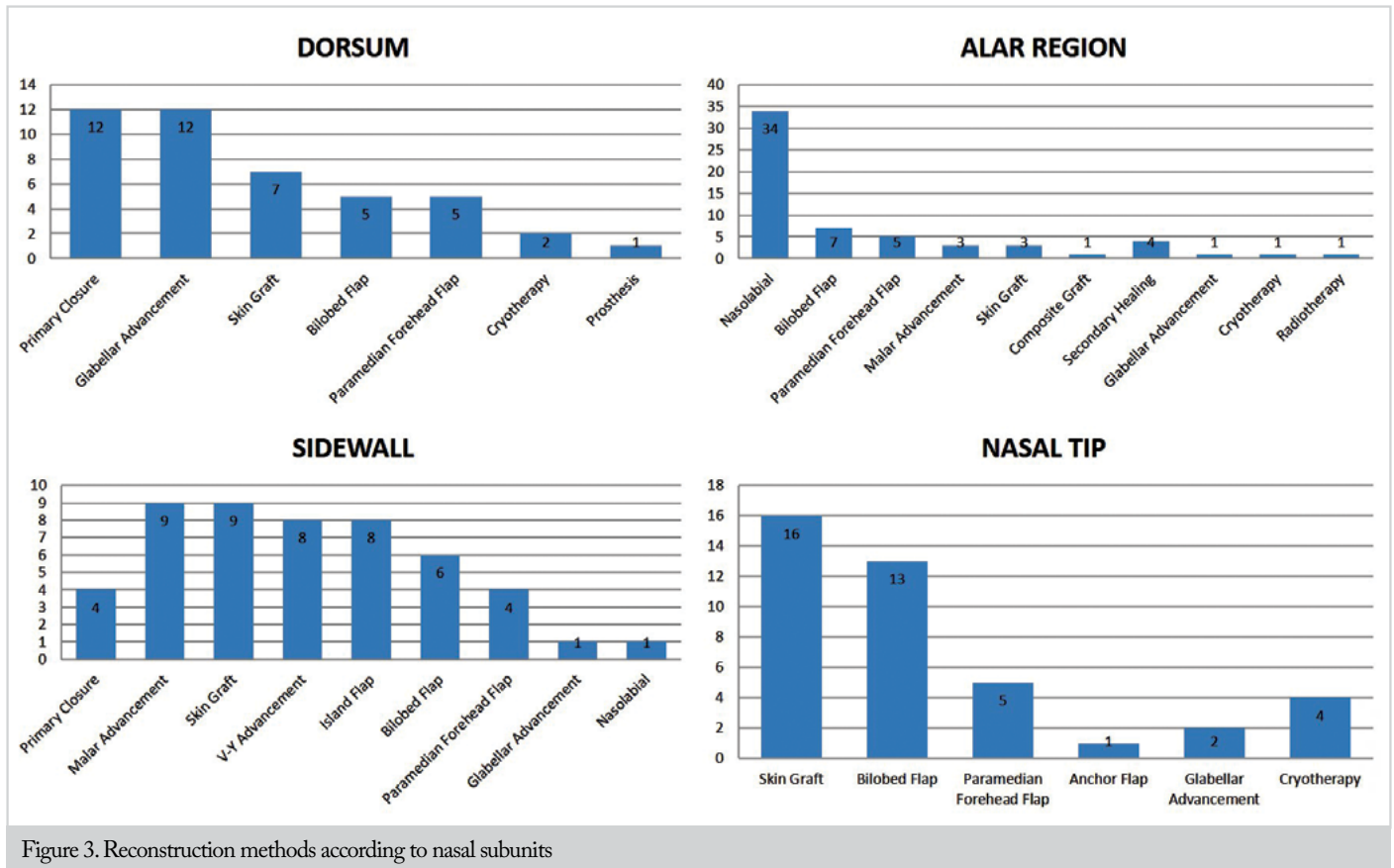


Figure 3. Reconstruction methods according to nasal subunits

the repair of defects in the face is comprehensible. In this study, most defects were repaired using flaps and this might be due to similar concerns. Further, as our clinic is a tertiary referral clinic, the time of presentation of the patients might be delayed and this may also increase the size of the lesion and thus the defect. Local flaps were used in wide defects as primary repair and skin grafts cannot be used frequently in these defects.

New skin cancers were found in different nasal subunits during follow-up in 6 (3.3%) of the 180 patients. Recurrence of the primary tumor was noticed in five patients (2.8%) during follow-up. A new tumor of the nasal skin was seen in approximately 5.8% of all patients. The risk of development of a second lesion in 2-5 years following the development of a first lesion has increased to up to 50% in the literature (25). In addition, Rowe et al. (26) reported recurrence rates to be 3-5% in small lesions and 9-10% in large lesions. The recurrence rates seen in this study resemble those rates in the study of Rowe et al.; however, most lesions seen in the patients included in this study were large. Thus, it can be considered that the recurrence rate in the present study is low. Further, a positive surgical margin was found in 12 patients, and recurrence was seen in only one of those patients. Pascal et al. (27) reported recurrence rates according to surgical margins by microscopic magnification. They reported a 33% recurrence in patients with a positive surgical margin. In addition, in another study, the recurrence rate increased up to 26% in patients with positive surgical margins (28). Further, Stratigos et al. (29) reported that in cutaneous SCC, the minimal surgical excision margins should be five-mm, even in low-risk tumors. In our routine practice and in this study, we used a five-mm surgical margin for BCC and 10

mm surgical margin for SCC. However, in the NCCN guidelines, a 10 mm surgical margin was recommended in high-risk regions such as nasal skin (4). Thus, the surgical margin was adequate for SCC; however, it seemed that the five mm margin was not sufficient for the skin of the nose. Therefore, margin positivity might be due to an inadequate surgical margin. Recurrence in only one patient among those with positive surgical margin or it might be due to the fact that the lesion was away from the microscopic surgical margin at the site that had been deemed to have a positive surgical margin as mentioned by Pascal (27). Methods such as Mohs surgery or 3D histology, in which all margins can be evaluated, can be used in excisions to overcome all problems stated above (30).

The wound was left open for secondary healing following resection in four patients (2.2%); three lesions were in the ala nasi and one was in the columellar region. No complications were seen in any patients who were treated with secondary healing, which is recommended for only small defects as it may cause asymmetry during healing due to cicatrization. However, dressings should be frequently changed using pomades including antibiotics to prevent crust formation. Van Der Eerden et al. (31) reported a satisfactory result in 43% of defects left for secondary healing.

When treatment methods are analyzed, primary closure was used in 16 (8.9%) patients. Primary closure is a quite beneficial and simple method following resection of superficial and small tumors in all regions of the nose. An important point in this technique is the necessity of designing incisions that are suit-

able with loosened skin tension lines. Further, tissues around the wound should be freed; thus, the tension in the suture line is decreased. It is frequently used in small defects in the dorsum and sidewall, although it is not recommended in large defects and in defects in the nasal tip and ala nasi as it may cause asymmetry (12, 13). Lesions were located in the nasal dorsum and sidewall in all 16 patients for whom we performed primary closure.

In the present study, 38 nasolabial flaps, 31 bilobed flaps, 19 paramedian forehead flaps, 16 glabellar advancement flaps, 12 malar advancement flaps, eight V-Y advancement flaps, five island flaps, and one anchor flap in a patient with a nasal tip lesion were used.

Nasolabial flaps are suitable for use in the repair of defects up to 2 cm in diameter in the ala nasi, although they are inconvenient to use in the nasal tip and upper part of the nose (32). Nasolabial flaps were used in 34, one, and three lesions in the ala nasi, sidewall, and columella, respectively, in the present study.

Bilobed flaps make use of the laxity of tissues in two planes perpendicular to each other; thus, to take advantage of the excess tissue from the lateral nose extending to the cheek, they have been used with considerable success for repairing defects of the nasal wing. This flap, which was first defined by Esser (33), was developed by various authors, and its final form was developed by Burget and Meninck (34). We used bilobed flaps in the reconstruction of lesions of 31 patients. Bilobed flap reconstruction was performed following tumor resection most frequently in nasal tip defects not greater than two cm in diameter (n=13), followed by defects in the ala nasi (n=7), nasal sidewall (n=6), and dorsum (n=5).

Although it requires dissection of a larger area, glabellar advancement flaps that leave a lesser scar in the postoperative period as the incisions are compatible with the margins of esthetic units and relaxed skin tension lines were found to be used in 16 patients in this present study. We found that it was particularly used in defects with a diameter that might be greater than two cm located in the dorsum. Among those patients, the lesion was in the dorsum in 12, sidewall in one, nasal tip in two, and ala nasi in one.

V-Y advancement flaps were used in eight patients with a lesion in the nasal sidewall. V-Y advancement flaps move into the defect with minimal tension; thus, it does not cause a dog-ear deformity. Its postoperative results are considerable good as the defect is covered with skin that is closest to the defect (35).

The most practical flap is the paramedian forehead flap for subtotal and total nasal reconstruction in aggressive tumors that might involve several nasal units at the same time and that might cause large cartilaginous destruction (36).

Paramedian forehead flaps with their high rate of acceptance due to their rich vascularity and as they provide large tissue support were used in 19 patients with defects in the ala nasi in five,

dorsum in six, and nasal tip and sidewall in four each. The lesion involved several subunits in all patients and caused cartilage destruction. The nasal skeletal structure was reformed by cartilage grafts, and no total flap necrosis was found in any patient. This, in turn, demonstrates that the vascular support of paramedian forehead flap is reliable and might be safely used even during total nasal reconstruction.

Conclusion

Nasal subunits have distinct characteristics; thus, the optimal reconstruction method should be preferred for each subunit. The objective of the reconstruction is not only closing the defect. Closing the defect appropriately with the optimal flap and in proper with the aesthetic subunits is the most important point in reconstruction of the nose.

Ethics Committee Approval: Ethics committee approval was received for this study from the ethics committee of Ege University.

Informed Consent: Informed consent was not received due to the retrospective nature of the study.

Peer-review: Externally peer-reviewed.

Author Contributions: Concept - I.K.; Design - I.K., M.U., F.A.; Supervision - F.A.; Resource - I.K., F.A.; Materials - I.K., F.A.; Data Collection and/or Processing - I.K.; Analysis and/or Interpretation - I.K., M.U.; Literature Search - I.K., M.U.; Writing - I.K., M.U.; Critical Reviews - F.A.

Conflict of Interest: No conflict of interest was declared by the authors.

Financial Disclosure: The authors declared that this study has received no financial support.

Etik Komite Onayı: Bu çalışma için etik komite onayı Ege Üniversitesi Etik Komitesi'nden alınmıştır.

Hasta Onamı: Çalışmanın geriye dönük tasarımından dolayı hasta onamı alınmamıştır.

Hakem Değerlendirmesi: Dış bağımsız.

Yazar Katkıları: Fikir - I.K.; Tasarım - I.K., M.U., F.A.; Denetleme - F.A.; Kaynaklar - I.K., F.A.; Gereçler - I.K., F.A.; Veri Toplanması ve/veya İşlemesi - I.K.; Analiz ve/veya Yorum - I.K., M.U.; Literatür Taraması - I.K., M.U.; Yazıyı Yazan - I.K., M.U.; Eleştirel İnceleme - F.A.

Çıkar Çatışması: Yazarlar çıkar çatışması bildirmemişlerdir.

Finansal Destek: Yazarlar bu çalışma için finansal destek almadıklarını beyan etmişlerdir.

References

1. Urbach F. Incidence of non melanoma skin cancer. *Dermatol Clin.* 1991; 9: 751-5.
2. Dourmishev LA, Rusinova D, Botev I. Clinical variants, stages, and management of basal cell carcinoma. *Indian Dermatol Online J* 2013; 4: 12-7. [CrossRef]

3. Shvartzman, L. Non-melanoma cancer of the skin. *Northeast Florida Medicine*. 2007; 58: p.37-9.
4. National Comprehensive Cancer Network (NCCN). NCCN Clinical Practice Guidelines in Oncology, Non melanoma skin cancer, 2007. <http://www.nccn.org>. Accessed [March 10, 2008].
5. Kricger A, Armstrong BK, English DR, Heenan PJ. A dose response curve for sun exposure and basal cell carcinoma. *Int J Cancer* 1995; 60: 482-8. [\[CrossRef\]](#)
6. English DR, Armstrong BK, Kricger A, Winter MG, Heenan PJ, Randell PL. Case-control study of sun exposure and squamous cell carcinoma of the skin. *Int J Cancer* 1998; 77: 347-53. [\[CrossRef\]](#)
7. Knox JM, Freeman RG, Heaton CL. Curettage and electrodesiccation in the treatment of skin cancer. *South Med J* 1962; 55: 1212-5. [\[CrossRef\]](#)
8. Thissen MR, Neumann MH, Schouten LJ. A systematic review of treatment modalities for primary basal cell carcinomas. *Arch Dermatol* 1999; 135: 1177-83. [\[CrossRef\]](#)
9. National Comprehensive Cancer Network (NCCN). NCCN Clinical Practice Guidelines in Oncology. Non melanoma skin cancer. 2016; National Comprehensive Cancer Network. https://www.nccn.org/store/login/login.aspx?ReturnURL=https://www.nccn.org/professionals/physician_gls/pdf/nmsc.pdf.
10. Bath-Hextall F, Leonardi-Bee J, Somchand N, Webster A, Delitt J, Perkins W. Interventions for preventing non-melanoma skin cancers in high-risk groups. *Cochrane Database Syst Rev*. 2007; 17:CD005414. [\[CrossRef\]](#)
11. Brodland DG, Zitelli JA. Surgical margins for excision of primary cutaneous squamous cell carcinoma. *J Am Acad Dermatol*. 1992 Aug;27(2 Pt 1):241-8. [\[CrossRef\]](#)
12. Salgarelli AC, Bellini P, Multinu A, Magnoni C, Francomano M, Fantini F, Consolo U, Seidenari S. Reconstruction of Nasal Skin Cancer Defects with Local Flaps. *J Skin Cancer*. 2011; 2011: 181093. Published online 2011 Jun 7.
13. Zitelli JA, Fazio MJ. Reconstruction of the Nose with Local Flaps. *Dermatol Surg*; 1991; 17: 184-9. [\[CrossRef\]](#)
14. Ferlay J, Shin HR, Bray F, Forman D, Mathers C, Parkin DM. GLOBOCAN 2008 v1.2: Cancer Incidence and Mortality Worldwide: IARC Cancer base No.10. Lyon, France: International Agency for Research on Cancer; 2010.
15. Diffey BL, Langtry JA. Skin cancer incidence and the aging population. *Br J Dermatol* 2005; 153: 679-80. [\[CrossRef\]](#)
16. Doran CM, Ling R, Byrnes J, Crane M, Searles A, Perez D, et al. Estimating the economic costs of skin cancer in New South Wales, Australia. *BMC Public Health* 2015; 15: 952. [\[CrossRef\]](#)
17. Enamett EA. Ultraviolet radiation as a cause of skin tumors. *CRC Crit Rev Toxicol* 1973; 2:211-55. [\[CrossRef\]](#)
18. Cakir BÖ, Adamson P, Cingi C. Epidemiology and economic burden of nonmelanoma skin cancer. *Facial Plast Surg Clin North Am* 2012; 20: 419-22. [\[CrossRef\]](#)
19. Corona R, Dogliotti E, D'Errico M, Sera F, Iavarone I, Baliva G, et al. Risk factors for basal cell carcinoma in a Mediterranean population: role of recreational sun exposure early in life. *Arch Dermatol* 2001; 137: 1162-8. [\[CrossRef\]](#)
20. Han J, Colditz GA, Hunter DJ. Risk factors for skin cancers: a nested case-control study within the nurses' health study. *Int J Epidemiol* 2006; 35: 1514-21. [\[CrossRef\]](#)
21. Buettner PG, Raasch BA. Incidence rates of skin cancer in Townsville, Australia. *Int J Cancer* 1998; 78: 587-93. [\[CrossRef\]](#)
22. Leiter U, Garbe C. Epidemiology of melanoma and nonmelanoma skin cancer—the role of sunlight. *Adv Exp Med Biol* 2008; 624:89-103. [\[CrossRef\]](#)
23. Rudolph C, Schnoor M, Eisemann N, Katalinic A. Incidence trends of nonmelanoma skin cancer in Germany from 1998 to 2010. *J Dtsch Dermatol Ges* 2015; 13: 788-97. [\[CrossRef\]](#)
24. Scrivener Y, Grosshans E, Cribier B. Variations of basal cell carcinomas according to gender, age, location and histopathological subtype. *Br J Dermatol* 2002; 147: 41-7. [\[CrossRef\]](#)
25. Raasch BA, Buettner PG. Multiple nonmelanoma skin cancer in an exposed Australian population. *Int J Dermatol* 2002; 41: 652-8. [\[CrossRef\]](#)
26. Rowe DE, Carroll RJ, Day CL Jr. Prognostic factors for local recurrence, metastasis, and survival rates in squamous cell carcinoma of the skin, ear, and lip. Implications for treatment modality selection. *J Am Acad Dermatol* 1992; 26: 976-90. [\[CrossRef\]](#)
27. Pascal RR, Hobby LW, Lattes R, Crikelair GF. Prognosis of incompletely excised basal cell carcinoma. *Plast Reconstr Surg* 1968; 41: 328-32. [\[CrossRef\]](#)
28. Bozan A, Gode S, Kaya I, Yaman B, Uslu M, Akyildiz S, et al. Long-term follow-up of positive surgical margins in basal cell carcinoma of the face. *Dermatol Surg* 2015; 41: 761-7. [\[CrossRef\]](#)
29. Stratigos A, Garbe C, Lebbe C, Malveyh J, del Marmol V, Pehamberger H, et al. Diagnosis and treatment of invasive squamous cell carcinoma of the skin: European consensus-based interdisciplinary guideline. *Eur J Cancer* 2015; 51: 1989-2007. [\[CrossRef\]](#)
30. Breuninger H, Adam P. 3D histology Evaluation of Dermatologic Surgery. 2013. Springer-Verlag London 2013. [\[CrossRef\]](#)
31. Van der Eerden PA, Lohuis PJ, Hart AA, Mulder WC, Vuyk H. Secondary intention healing after excision of nonmelanoma skin cancer of the head and neck: statistical evaluation of prognostic values of wound characteristics and final cosmetic results. *Plast Reconstr Surg*; 2008; 122: 1747-55. [\[CrossRef\]](#)
32. Yotsuyanagi T, Yamashita K, Urushidate S, Yokoi K, Sawada Y. Nasal reconstruction based on aesthetic subunits in Orientals. *Plast Reconstr Surg*; 2000; 106: 36-44. [\[CrossRef\]](#)
33. Esser JFS. Gestielte lokale Nasenplastik mit zweizipfligem Lappen, Deckung des sekundären Defektes vom Ersten Zipfel Durch den zweiten. *Dtsch Z Chir* 1918; 143: 385-90. [\[CrossRef\]](#)
34. Burget GC, Menick FJ. Repair of small surface defects. In: Burget GC, Menick FJ, editors. *Aesthetic reconstruction of the nose*. St. Louis: Mosby; 1994. p. 117-56.
35. Zook EG, Van Beek AL, Russell RC, Moore JB. V-Y advancement flap for facial defects. *Plast Reconstr Surg* 1980; 65: 786-97. [\[CrossRef\]](#)
36. Brodland DG. Paramedian forehead flap reconstruction for nasal defects. *Dermatol Surg* 2005; 31: 1046-52. [\[CrossRef\]](#)