

Unilateral Pedunculated Lymphangiectatic Fibrolipomatous Polyp of the Palatine Tonsil: A Rare Case

Palatin Tonsilin Unilateral Pediküllü Lenfanjektatik Fibrolipomatöz Polibi: Nadir Bir Olgu

Case Report
Olgu Sunumu

Nesibe Gül Yüksel Aslier, Mustafa Aslier
Clinic of Otorhinolaryngology, Silopi State Hospital, Şırnak, Turkey

Abstract

Lymphangiomas are rare benign hamartomatous tumors of the palatine tonsils that can cause significant distress to the patients such as sore throat, foreign body sensation, a lumpy feeling in the throat region, dysphagia, and eventual suffocation. In this paper, the case of a 17-year-old male who came to the outpatient clinic with a complaint of difficulty in swallowing, eventual vomiting, and occasions of hematemesis is presented. On physical examination, the patient had a smooth-surface, polypoid, pedunculated tumoral lesion originating from the middle pole of the left palatine tonsil and protruding into the

oropharyngeal isthmus. The patient underwent left tonsillectomy. Histopathological examination of the surgical specimen showed typical features of a lymphangiectatic fibrolipomatous polyp. The case reported herein with the brief literature review points out the clinical and the benign, non-neoplastic characteristics of the lymphangiectatic fibrolipomatous polyp, which can be cured by surgical excision along with tonsillectomy.

Keywords: Dysphagia, hamartoma, palatine tonsil, polyp, tonsillectomy

Öz

Lenfanjiyomatöz polipler, hastalarda boğaz ağrısı, yabancı cisim hissi, boğaz bölgesinde topaklanma hissi, disfaji ve boğulma gibi ciddi rahatsızlıklara neden olabilen, palatin tonsillerin nadir benign hamartomatöz tümörleridir. Bu yazıda; yutma, kusma ve hematemez yakınmaları nedeniyle polikliniğe başvuran 17 yaşındaki genç bir erkek olgu sunulmaktadır. Fizik muayenede, hastanın sol palatin tonsil orta kutbundan kaynaklanan ve orofaringeal açıklığa sarkan, pürüzsüz yüzeyli, pediküllü polipoid tümöral lezyon mevcuttu.

Hastaya sol tonsillektomi yapıldı. Cerrahi örneğin histopatolojik incelemesi, lenfanjektatik fibrolipomatöz polibin tipik özelliklerini gösterdi. Burada kısa bir literatür taramasıyla sunulan olgu ile, tonsillektomi ile cerrahi eksizyonu sağlanabilen lenfanjektatik fibrolipomatöz polibin klinik ve selim, non-neoplastik özelliklerine dikkat çekilmiştir.

Anahtar Kelimeler: Disfaji, hamartom, palatin tonsil, polip, tonsillektomi

Introduction

Squamous papillomas are the common benign tumors of the tonsils. Lymphangiomas are the next most common lesions followed by epidermal inclusion cysts (1). They sometimes carry different names such as lymphangioma, hamartomatous tonsillar polyp, lymphangiomas polyp, lymphangiectatic fibrous polyp, lymphangiectatic fibrolipomatous polyp, and so on according to their stromal components (2). Lymphangiomas polyps generally present as a pale or pink pedunculated lesion attached to the palatine tonsil. They

consist of dilated amorphous lymphatics with fibrous, lymphoid, and/or adipose stroma, and they are considered to be a hamartoma or, to some authors, an acquired lymphangiectatic malformation (3-7). Because of the eccentric histopathological features of these polyps, there is still difficulty in describing them with a common terminology and in classifying them correctly. Therefore, in light of our case, the clinical, surgical, and histopathological features of a lymphangiectatic fibrolipomatous polyp are described so as to contribute to the literature pool of these uncommon benign lesions of the palatine tonsil.



Address for Correspondence/Yazışma Adresi:

Nesibe Gül Yüksel Aslier
E-mail: nesibe.gul.yuksel@gmail.com

Received Date/Geliş Tarihi: 24.01.2016

Accepted Date/Kabul Tarihi: 13.02.2017

Available Online Date

Çevrimiçi Yayın Tarihi: 22.05.2017

© Copyright 2017 by Official Journal of the Turkish Society of Otorhinolaryngology and Head and Neck Surgery Available online at www.turkarchotorhinolaryngol.org

© Telif Hakkı 2017 Türk Kulak Burun Boğaz ve Baş Boyun Cerrahisi Derneği Makale metnine www.turkarchotorhinolaryngol.org web sayfasından ulaşılabilir.

DOI: 10.5152/tao.2017.2323

Case Presentation

A 17-year-old male came to the Ear Nose and Throat Diseases outpatient clinics of Silopi State Hospital with the chief complaint of a difficulty in swallowing, plus some occasions of vomiting and bloody saliva for the past few months. On inspection, an approximately 3×2×1 cm pale polypoid lesion with its stalk attached to the left tonsil was observed (Figure 1). On palpation, the mass was soft to firm, smooth-surfaced, mobile, and non-pulsatile. It had an attachment to the left tonsil with a ~1 cm thick pedicle. Other physical examinations, including fiber

optic endoscopic work for dysphagia and hematemesis, revealed no evidence of trismus, cervical lymphadenopathy, or accompanying head and neck pathology. Systemic examination did not disclose any significant abnormalities.

All routine hematological and other biochemical investigations were normal. Computed tomography of the neck showed a 26×14 mm hypodense polypoid soft tissue lesion protruding from the oropharyngeal inlet and extending from the uvular level to the epiglottal tip (Figure 2) but no pathological lymph nodes or additional lesions.

The patient underwent left tonsillectomy with the excision of the polyp by preserving its attachment to the tonsil. The operation was performed under general anesthesia and was uncomplicated. The tonsil was removed using the conventional cold dissection method, and bipolar cautery was used for hemostasis. Blood loss was minimal. The surgical specimen is shown in Figure 3. Dimensions of the polypoid mass was 3×2×1.5 cm post-operatively.

The macroscopic pathology of the specimen was reported as a 2.5×1.8×1.2 cm polypoid lesion with a smooth white cut surface and an 0.8 cm peduncle through which it was attached to a 2.5×2.3×1.5 cm piece of left tonsillectomy material. Histologically, the overlying surface epithelium was squamous. There were dilated ductal structures and colonies of small lymphocytes packed into submucosal spaces as well as small groups of adipose tissue in the fibrous stroma. The tumor showed no stromal infiltration and extension into its peduncle or the tonsil. The overall histopathology of the lesion was reported as “lymphangiectatic fibrolipomatous polyp,” and the left tonsillectomy material was reported as “chronic tonsillitis”. The patient has been asymptomatic for a year since the surgery.

Informed consent was obtained from both the patient and his father as a written document.

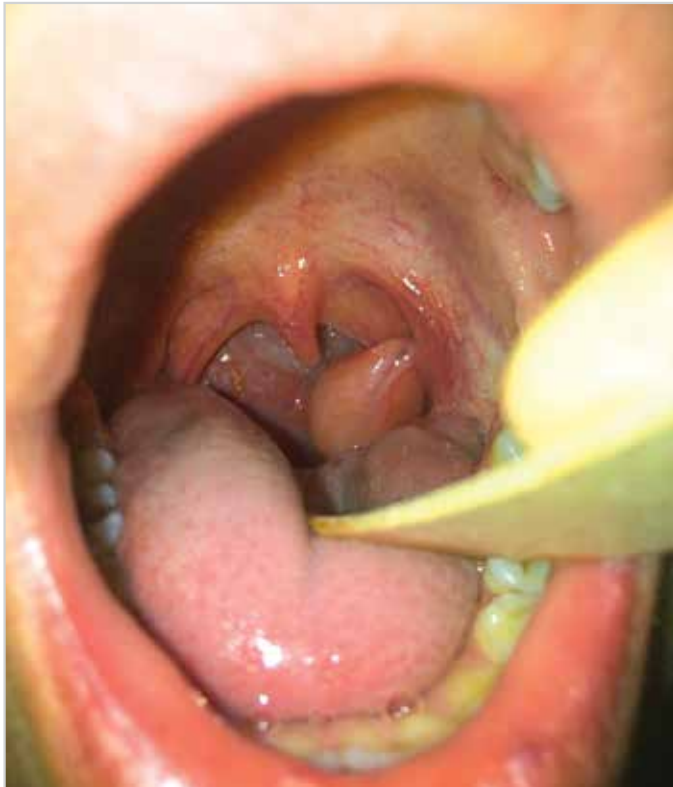

Figure 1. Oral cavity examination revealed a pale pink polypoid soft tissue originating from the left tonsillar fossa

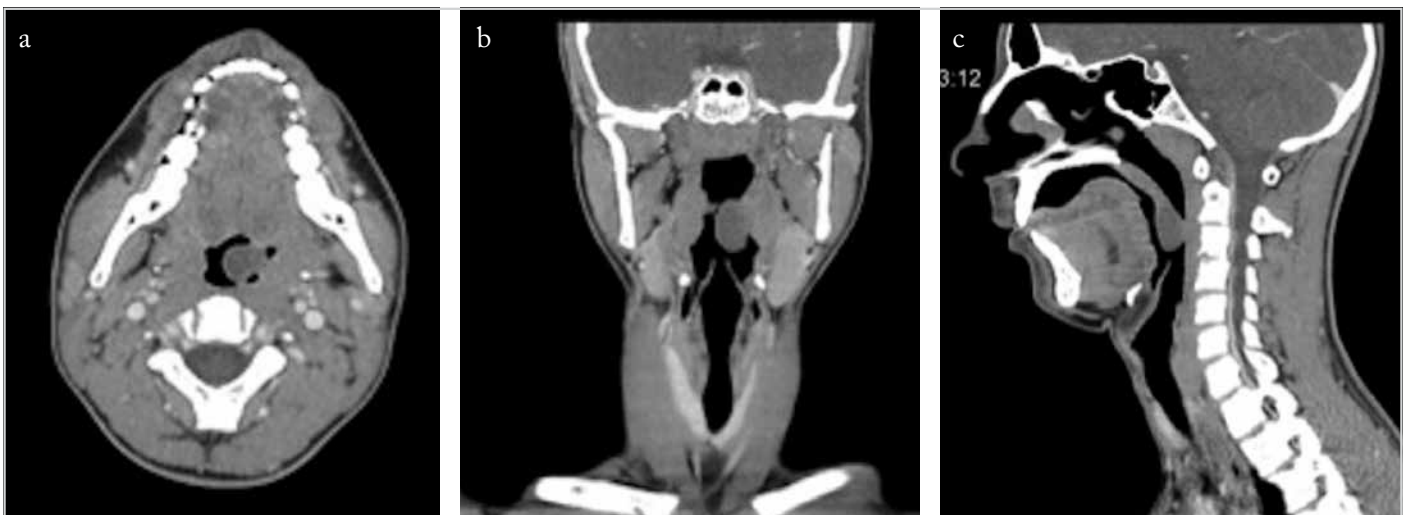


Figure 2. a-c. Axial (a), coronal (b), and sagittal (c) sections of computed tomography of the neck showed a hypodense polypoid lesion in the left tonsillar region extending to the level of the epiglottis just above the oropharyngeal inlet

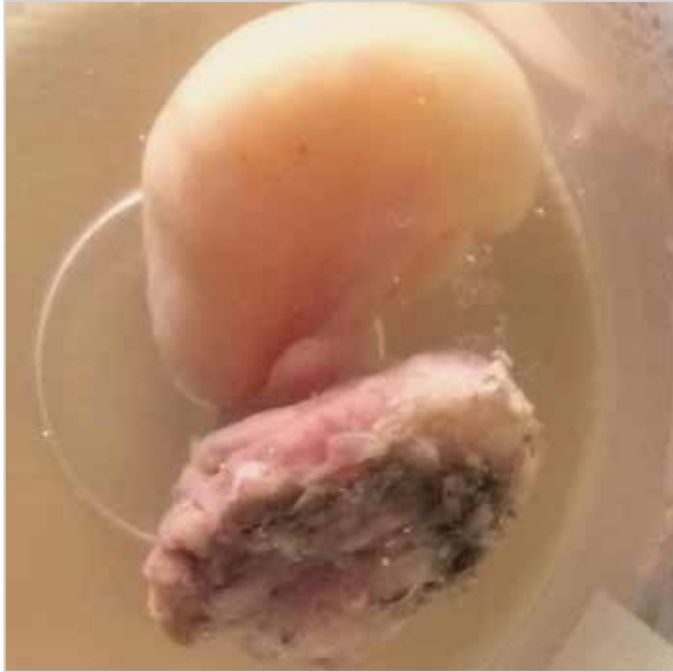

Figure 3. Surgical specimen of left tonsillectomy, including the polypoid mass, just after fixation

Discussion

Most head and neck lymphangiomatous lesions are located in the skin and subcutaneous tissues, and the palatine tonsil is a relatively less common site. Pedunculated polypoid lesions of the tonsil, although presented under various types of nomenclature, are relatively rare tumors (7).

The pathogenesis and classification of lymphangiomatous lesions is still unclear. Because they are composed of abnormal cells and tissue proliferations found in the location of their origin, here the tonsil, we agree that these tumors are reasonably hamartomatous (3-7). While chronic inflammation and obstruction of the lymphatics of the tonsillar surface are accused for development of these tumors, as seen in this case there is not always associated chronic tonsillitis or any tonsillar pathology in the patient's history, which suggests that these are not the mechanisms of lymphomatous polypoid proliferation.

The clinical presentation varies, including simple sore throat, dysphagia, stepwise deglutition, and eventual suffocation or vomiting, especially if the patient is young (4, 8). These tumors occasionally become large, as was the case here, and cause obstructive symptoms and sometimes present as bilateral (4, 5, 9). The reported cases have mostly been in adults with only a few exceptions (2-8). The present case also expressed that he had experienced occasions of bloody saliva, especially after meals. Among the tissue components of the lymphangiomatous polyps, the stalk might be responsible for this symptom because it has vascular formations and loose fibrous tissues inside of it. In the stalk region from the specimen presented here, a thick-walled artery and smooth muscle hyperplasia appeared. It has been shown that the polyp itself has poor blood flow and chron-

ic inflammatory features and thus is not expected to be responsible for hemorrhage (6).

These tumors generally look similar to any polypoid lesion attached to the surface of the tonsillar bed or to the lateral pharyngeal wall, including a pedicle, a smooth surface, and a pale or pink color (1, 2, 4, 6). The presented case was a good example of these definitions (Figure 1). Although a supplementary study is not crucial for diagnosis, immunocytochemical antibodies might have a role in differentiating the components of the ductal structures and the stroma so as to provide a specific pathologic diagnosis of the subtypes (2, 4). Nevertheless, immunohistochemical examination was not applicable for this case because of the medical and technical conditions of the local Pathology clinic. In addition to the other subtypes of lymphangiomatous polyps, differential diagnosis of such a lesion of the tonsil includes other benign tonsillar lesions like fibroma, fibroepithelial polyp, hairy polyp, hemangiomas hamartoma, fibrovascular polyp, lipoma, neurofibroma, schwannoma, and plasma cell granuloma (2, 10).

Surgical removal of the lesion is claimed to be curative for lymphomatous polyps and other benign neoplastic or non-neoplastic lesions of the palatine tonsils (8). However, because lymphangiomatous polyps have their pedicles attached to the palatine tonsil, ipsilateral tonsillectomy which also includes the excision of the lesion would be preferable (4, 9). In the presented case, because there was no history of recurrent tonsillitis, only left tonsillectomy was chosen. The patient has been symptom and disease free for a year.

Conclusion

Lymphangiectatic fibrolipomatous polyps of the palatine tonsil are rare benign tumors that generally cause a lumpy feeling in the throat region but might also lead to obstructive symptoms. Histopathologically, they consist of dilated lymphatic channels with fibrous, lymphoid, and adipose stromal tissue. They can safely be cured by surgical excision with associated tonsillectomy.

Informed Consent: Written informed consent was obtained from patients' parents who participated in this study.

Peer-review: Externally peer-reviewed.

Author Contributions: Concept - N.G.Y.A., M.A.; Design - N.G.Y.A., M.A.; Supervision - N.G.Y.A., M.A.; Resource - N.G.Y.A., M.A.; Materials - N.G.Y.A., M.A.; Data Collection and/or Processing - N.G.Y.A., M.A.; Analysis and/or Interpretation - N.G.Y.A., M.A.; Literature Search - N.G.Y.A., M.A.; Writing - N.G.Y.A., M.A.; Critical Reviews - N.G.Y.A., M.A.

Conflict of Interest: No conflict of interest was declared by the authors.

Financial Disclosure: The authors declared that this study has received no financial support.

Hasta Onamı: Yazılı hasta onamı bu çalışmaya katılan hastanın ailesinden alınmıştır.

Hakem Değerlendirmesi: Dış bağımsız.

Yazar Katkıları: Fikir - N.G.Y.A., M.A.; Tasarım - N.G.Y.A., M.A.; Denetleme - N.G.Y.A., M.A.; Kaynaklar - N.G.Y.A., M.A.; Gereçler - N.G.Y.A., M.A.; Veri Toplanması ve/veya İşlemesi - N.G.Y.A., M.A.; Analiz ve/veya Yorum - N.G.Y.A., M.A.; Literatür Taraması - N.G.Y.A., M.A.; Yazıyı Yazan - N.G.Y.A., M.A.; Eleştirel İnceleme - N.G.Y.A., M.A.

Çıkar Çatışması: Yazarlar çıkar çatışması bildirmemişlerdir.

Finansal Destek: Yazarlar bu çalışma için finansal destek almadıklarını beyan etmişlerdir.

References

1. Roth M. Lymphangiomatous polyp of the palatine tonsil. *Otolaryngol Head Neck Surg* 1996; 115: 172-3. [\[CrossRef\]](#)
2. Kardon DE, Wenig BM, Heffner DK, Thompson LD. Tonsillar lymphangiomatous polyps: A clinicopathologic series of 26 cases. *Mod Pathol* 2000; 13: 1128-33. [\[CrossRef\]](#)
3. Heffner DK. Pathology of the tonsils and adenoids. *Otolaryngol Clin North Am* 1987; 20: 279-86.
4. Duggal P, Chakravorty S, Sharma S, Ahluwalia RK. Pedunculated hamartomatous polyp of palatine tonsil in a child: A new presentation. *Int J Pediatr Otorhinolaryngol Extra* 2008; 3: 120-3. [\[CrossRef\]](#)
5. Shara KA, al-Muhana AA, al-Shennawy M. Hamartomatous tonsillar polyp. *J Laryngol Otol* 1991; 105: 1089-90. [\[CrossRef\]](#)
6. Hiraide F, Inouye T, Tanaka E. Lymphangiectatic fibrous polyp of the palatine tonsil. A report of three cases. *J Laryngol Otol* 1985; 99: 403-9. [\[CrossRef\]](#)
7. Stal S, Hamilton S, Spira M. Hemangiomas, lymphangiomas, and vascular malformations of the head and neck. *Otolaryngol Clin North Am* 1986; 19: 769-96.
8. Park E, Pransky SM, Malicki DM, Hong P. Unilateral lymphangiomatous polyp of the palatine tonsil in a very young child: a clinicopathologic case report. *Case Rep Pediatr* 2011; 2011: 451542. [\[CrossRef\]](#)
9. Chen HH, Lovell MA, Chan KH. Bilateral lymphangiomatous polyps of the palatine tonsils. *Int J Pediatr Otorhinolaryngol* 2010; 74: 87-8. [\[CrossRef\]](#)
10. Farboud A, Trinidad A, Harris M, Pfeleiderer A. Fibroepithelial polyp of the tonsil: case report of a rare, benign tonsillar lesion. *J Laryngol Otol* 2010; 124: 111-2. [\[CrossRef\]](#)