

Successful Treatment of a Case with Cervical Lymphatic Malformation: Repeated Bleomycin Sclerotherapy

Servikal Lenfatik Malformasyonlu Bir Olgunun Başarılı Tedavisi: Yinelenen Bleomisin Skleroterapisi

Case Report
Olgu Sunumu

Mustafa Mert Başaran¹, Selmin Özgürsoy Karataylı¹, Arzu Pampal², Şefik Halit Akmansu¹

¹Department of Otorhinolaryngology, Ufuk University School of Medicine, Ankara, Turkey

²Department of Paediatric Surgery, Ufuk University School of Medicine, Ankara, Turkey

Abstract

Lymphatic malformations (LM) are benign congenital malformations of the lymphatic system. They are frequently seen in the neck and sometimes can be life-threatening due to compression to the airway. Treatment modalities are widespread including surgical excision, radiotherapy, laser therapy, and application of intralesional sclerosing agents. We report the suc-

cessful treatment of cervical LM in a 3-year-old boy who presented with a sudden onset of a large cystic mass in the posterior cervical triangle and was treated with repeated injections of intralesional bleomycin.

Keywords: Bleomycin, lymphatic malformation, neck, sclerotherapy

Öz

Lenfatik malformasyonlar (LM) lenfatik sistemin benign konjenital oluşum bozukluklarıdır. Sıklıkla boyunda görülürler ve bazen havayolun basısı ile yaşamı tehdit edebilirler. Tedavisinde; cerrahi eksizyon, radyoterapi, lazer uygulaması ve intralezyonel sklerozan ajanlar gibi çeşitli yöntemler vardır. Burada tekrarlayıcı

intralezyonel bleomisin enjeksiyonları ile başarıyla tedavi edilen, posterior servikal üçgende aniden gelişen büyük bir kistik kitle ile başvuran servikal LM'li üç yaşında bir erkek çocuk sunuldu.

Anahtar kelimeler: Bleomisin, lenfatik malformasyon, boyun, skleroterapi

Introduction

Lymphatic malformations (LM) are benign congenital malformations of lymphatic system that occur in one in every 60.000 births. Nearly half of the cases are diagnosed at birth and more than 90% before the age of two years. LMs are mostly seen in the head and neck and are generally presented as non-tender, slowly expanding, fluctuating cystic masses. They are generally asymptomatic but symptoms depend on localization of the lesion (1, 2).

Diagnosis can be made with either ultrasonography (US) or magnetic resonance imaging (MRI) and computed tomography (CT) (3). Ultrasonography is an ideal tool to diagnose LM but it lacks the panoramic view and information of adjacent structures. As CT scan can cause radiation exposure, MRI gives further details about the anatomic extension and relation with adjacent structures and is helpful in terms of treatment modalities (4).

Treatment modalities include surgical excision of the mass and/or sclerosing therapy. If total excision of the mass is not available, multiple operations, combination of surgery and sclerotherapy, or consecutive sclerotherapies can be applied (1). Most commonly used sclerosing agents are bleomycin, an antitumor agent, and OK-432, a lyophilized product of group A *Streptococcus pyogenes* strain.

We present a 3-year-old boy with a cystic LM in the posterior cervical and supraclavicular triangle, who was treated with two consecutive doses of intralesional bleomycin.

Case Presentation

A 3-year-old boy presented to our clinic with a large swelling in the right supraclavicular region, extending to posterior cervical region for 15 days. The swelling was believed to have a sudden onset and was related to a minor trauma to the shoul-



Cite this article as: Başaran MM, Özgürsoy Karataylı S, Pampal A, Akmansu ŞH. Successful Treatment of a Case with Cervical Lymphatic Malformation: Repeated Bleomycin Sclerotherapy. Turk Arch Otorhinolaryngol 2017; 10.5152/tao.2017.2360

Address for Correspondence/Yazışma Adresi:
Mustafa Mert Başaran
E-mail: mbasaran88@gmail.com

Received Date/Geliş Tarihi: 01.02.2017
Accepted Date/Kabul Tarihi: 10.08.2017
Available Online Date/Çevrimiçi Yayın Tarihi: 02.10.2017

© Copyright 2017 by Official Journal of the Turkish Society of Otorhinolaryngology and Head and Neck Surgery Available online at www.turkarchotorhinolaryngol.org

© Telif Hakkı 2017 Türk Kulak Burun Boğaz ve Baş Boyun Cerrahisi Derneği Makale metnine www.turkarchotorhinolaryngol.org web sayfasından ulaşılabilir.

DOI: 10.5152/tao.2017.2360

der by the family. Neither pain nor movement restriction was stated. His physical examination revealed a well-circumscribed, multilobulated, 5×3 cm, immobile, non-tender, non-pulsatile, fluctuating, cystic mass in right posterior cervical and supraclavicular region (Figure 1). The mass was evaluated with US and MRI scans. The US scan revealed a 55×40×35 mm, multiloculated, homogenous, cystic mass on posterolateral border of the sternocleidomastoid (SCM) muscle in the right supraclavicular region (Figure 2), whereas the MRI scan showed a 63×52×40 mm, well-circumscribed, septated, cystic mass in the lateral border of SCM muscle superior to the clavicle and anterior to supraspinatus muscle suggesting a hemorrhagic LM (Figure 3). Use of bleomycin as a sclerosing agent for LM was approved by the General Directorate for Pharmaceuticals and Pharmacy of Turkey (75642246-518.01-E.154480). After taking informed consent from the parents, the patient was taken to the operating room. After induction of general anesthesia and endotracheal intubation, an 18G catheter was inserted under real-time US visualization. Approximately 60 mL of serohemorrhagic fluid was aspirated through macrocysts and 0.25 mg/kg of bleomycin (Bleocin-S 15mg®; Nippon Kayaku Co., Tokyo, Japan) in 20 mL of normal saline was injected via the same catheter. The patient was followed overnight for possible side effects for bleomycin and discharged without any problem on the next day. The cytologic evaluation revealed cystic fluid rich in erythrocytes and lymphocytes.

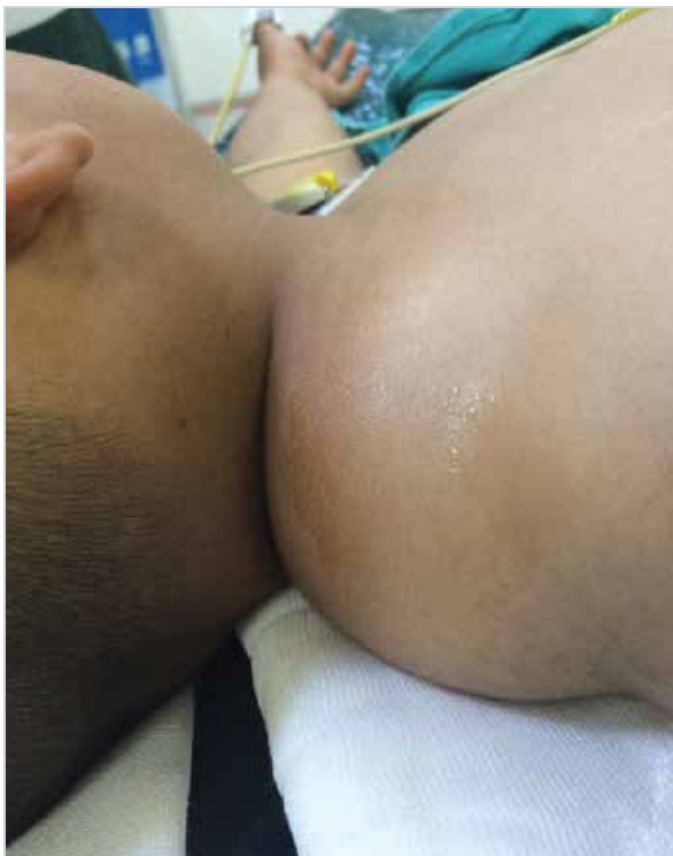

Figure 1. A well-circumscribed, multilobulated, 5×3 cm, immobile, non-tender, non-pulsatile, non-compressible, fluctuant, cystic in consistency mass in the right posterior cervical and supraclavicular regions

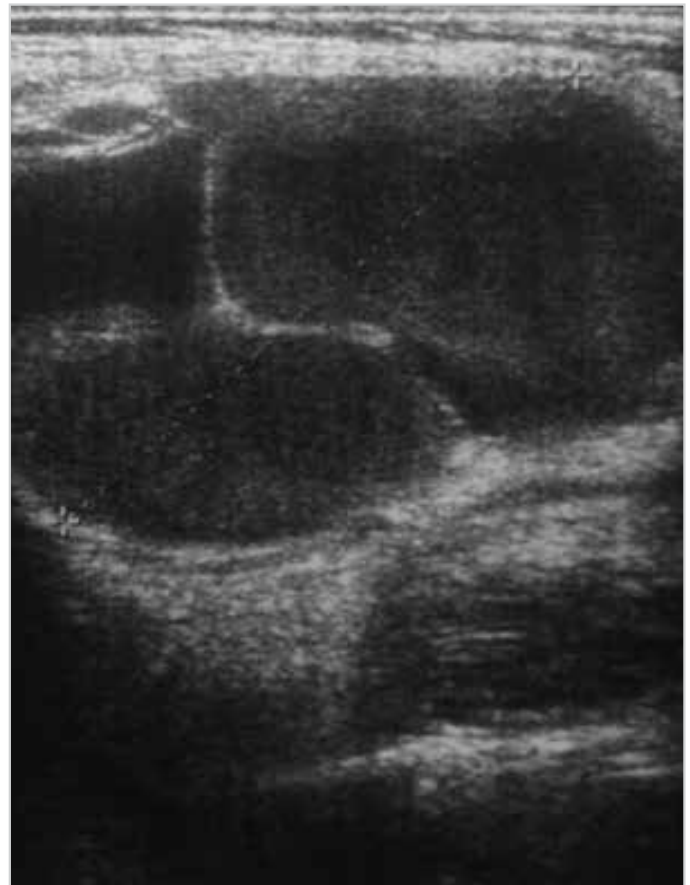

Figure 2. Ultrasound scan showing a 55×40×35 mm, multilobulated, homogenous, cystic mass on posterolateral border of sternocleidomastoid (SCM) muscle in the right supraclavicular region

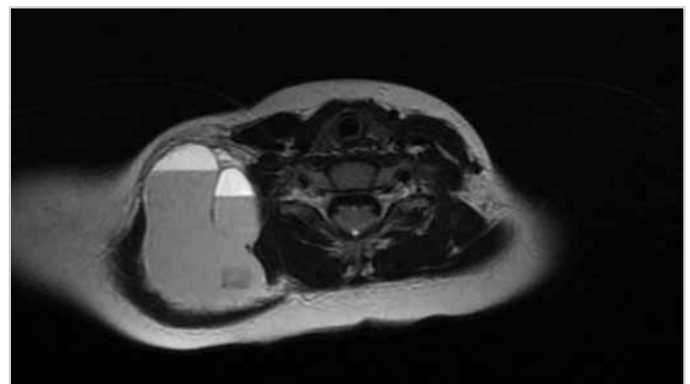


Figure 3. MRI scan showing 63×52×40 mm, well-circumscribed, septated, cystic mass in the lateral border of sternocleidomastoid muscle superior to clavicle and anterior to supraspinatus muscle

The patient was seen again after four weeks. A smaller swelling in the right supraclavicular region was noticed, and the ultrasound scan revealed a 3.5×1.5 cm lobulated cystic mass in the right supraclavicular fossa. After taking informed consent from the parents, the second application of Bleomycin was performed under general anesthesia with the same method. The patient was evaluated after 3 months postoperatively (Figure 4), and as no recurrence was seen, a yearly follow-up was suggested. After two years of follow-up, there were no signs of recurrence or side effects of the drug.

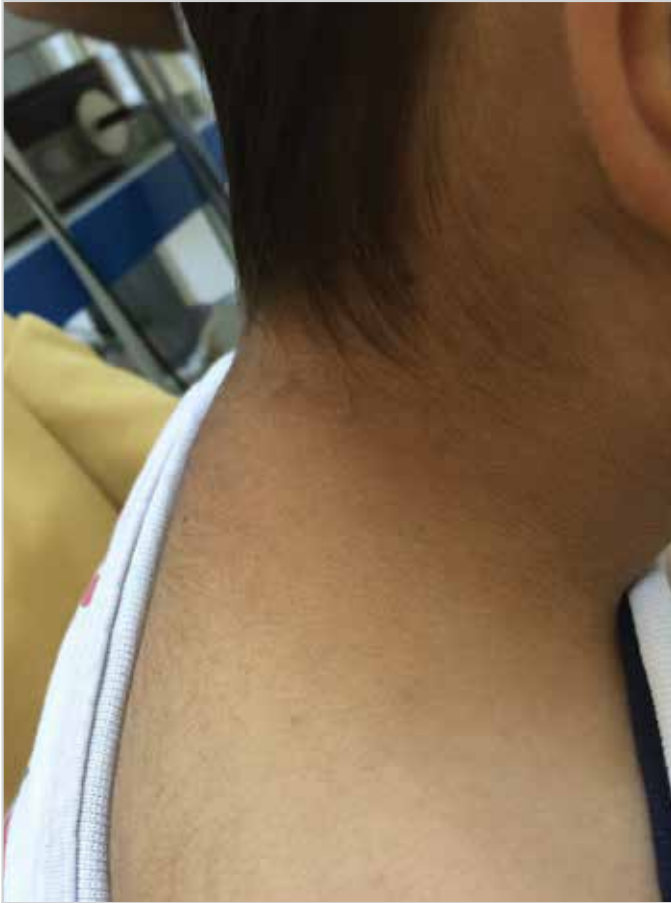

Figure 4. Physical examination at the third postoperative month revealing no recurrence

Discussion

Lymphatic malformations are benign hamartomas of lymphatic vessels. They are believed to originate from sequestration and cystic dilation of fetal lymphaticovenous sacs that fail to communicate either remaining lymphatic or venous system (1). Because the spontaneous regression of LM is very rare, treatment is often necessary.

Surgical treatment has been the traditional choice for LM. Either aspiration/drainage or surgical excision has been presented in literature with different complications according to their localizations (3). Surgical mortality is reported to be 2%-6%, and postoperative recurrence is up to 27% (5). Because of the probability of incomplete resection and possible nerve and main vessels injury, alternative therapies are considered for LM. The literature review reveals moderate to high success rates of LM therapy with radiation, laser, and sclerosing agents (3). Especially intralesional sclerotherapy has promising results with low complication rates (6).

Sclerotherapy is performed by entering the cystic cavity with a direct puncture, aspirating fluid, and injecting the sclerosing agent. The most common complications of this therapy are skin necrosis, local neuropathy, and cardiopulmonary toxicity (1). Sodium morrhuate was the first agent recommended for treatment of LM (7). Since then, many agents, such as steroids, alcohol,

bleomycin sulfate, tetracycline, and OK-432, have been introduced (6).

Bleomycin is an antimetabolite agent acting on DNA synthesis inhibition. It is also known to have irritant effects on endothelial cells probably causing non-specific inflammation that result in fibrosis of LM. As a sclerosing agent in the head and neck diseases, it was first used with success in 1977 (7). Even though a total dose up to 50 mg is recommended, the amount of dose is a matter of debate in the literature. In a systematic review by Churchill et al. (8) the preferred doses of bleomycin were reported to be varying from 0.25 to 3 mg/kg with maximum doses ranging from 1.5 to 6 mg/kg for repeated applications. The overall success with the mentioned doses was reported to be 72% for head and neck LMs. All authors reported better outcomes with low failure rates and minor side effects. Paragraf başı yağalım, lütfen. about LM treatment with intralesional bleomycin as a sclerosing agent but all differ in effective dose of bleomycin. The minimal effective dose for bleomycin in the literature was presented by Sanlialp et al. (9). A dose of 0.25 mg/kg bleomycin in physiological saline (PS) was reported to be applied intralesionally to the patients. They applied bleomycin and PS compound equally and maximum 20 mL compound according to the amount of aspirated cystic fluid. Fever (9%), local inflammatory reactions (3.6%), and vomiting (1.8%) were the only early complications that they encountered. They attributed their lower complication rates to lower dosing regimen they used and longer intervals between injections (>4 weeks). The mean number of injections was reported to be 2.87 ± 2.03 (ranging 1-7) for their series. In addition, Sayan et al. (6) used 0.5 mg/kg bleomycin for 4 to 6 weeks and found that in 76.5% cases the lesion was dissolved and in 23.5% there was a decrease in the size of the lesion. Generally advised procedure consists of three to five 0.3 to 0.6 mg/kg dosage of bleomycin repeated after 3 weeks (10). We chose the least effective dose presented by the literature for our patient and we repeated the dose in four weeks' interval. After two years of follow-up, he showed no signs of cervical mass with no complication.

The most serious adverse effect of the drug is related with pulmonary system. Pulmonary fibrosis and interstitial pneumonia are the most serious side effects of bleomycin. However, no such complication for LMs is reported, as this complication is thought to be dose-dependent. In order to avoid such complications, the effective minimum dose must be chosen carefully in order to avoid repeated injections for LM and the need for bleomycin as an antitumor agent for the rest of the life.

Conclusion

Lymphatic malformations which are frequently seen in the neck are benign congenital malformations of the lymphatic system. Treatment modalities are widespread including surgical excision, radiotherapy, laser therapy, and application of intralesional sclerosing agents.

In our study, we preferred intralesional sclerotherapy against macrocystic LM and used bleomycin as a sclerosing agent. There is an increasing choice of sclerotherapy especially as a treatment

for pediatric lymphatic malformations (10). There are many reports about the effective dosage of bleomycin. In our case, to prevent adverse effects of the drug, we used the minimum effective dose presented in the literature; 0.25 mg/kg of bleomycin; and the disease was treated with no recurrence or complications after 2 years. To define the adequate dosage of bleomycin, more reviews about different amounts of dosage in various cases must be done.

Informed Consent: Written informed consent was obtained from patients' parents who participated in this study.

Peer-review: Externally peer-reviewed.

Author Contributions: Concept - A.P., S.H.A.; Design - S.K.O., A.P.; Supervision - S.K.O., S.H.A.; Resource - M.M.B., A.P.; Materials - M.M.B., A.P.; Data Collection and/or Processing - M.M.B., A.P.; Analysis and/or Interpretation - S.K.O., A.P.; Literature Search - M.M.B., A.P.; Writing - M.M.B., A.P.; Critical Reviews - S.H.A.

Conflict of Interest: No conflict of interest was declared by the authors.

Financial Disclosure: The authors declared that this study has received no financial support.

Hasta Onamı: Yazılı hasta onamı bu çalışmaya katılan hastanın ailesinden alınmıştır.

Hakem Değerlendirmesi: Dış bağımsız.

Yazar Katkıları: Fikir - A.P., S.H.A.; Tasarım - S.K.O., A.P.; Denetleme - S.K.O., S.H.A.; Kaynaklar - M.M.B., A.P.; Gereçler - M.M.B., A.P.; Veri Toplanması ve/veya İşlemesi - M.M.B., A.P.; Analiz ve/veya Yorum - S.K.O., A.P.; Literatür Taraması - M.M.B., A.P.; Yazıyı Yazan - M.M.B., A.P.; Eleştirel İnceleme - S.H.A.

Çıkar Çatışması: Yazarlar çıkar çatışması bildirmemişlerdir.

Finansal Destek: Yazarlar bu çalışma için finansal destek almadıklarını beyan etmişlerdir.

References

1. Elluru RG, Balakrishnan K, Padua HM. Lymphatic malformations: diagnosis and management. *Semin Pediatr Surg* 2014; 23: 178-85. [\[CrossRef\]](#)
2. Trenor CC 3rd, Chaudry G. Complex lymphatic anomalies. *Semin Pediatr Surg* 2014; 23: 186-90. [\[CrossRef\]](#)
3. Unuvar S, Tanrıverdi Hİ, Senel U, Ince DA, Takci S, Cakmak B. Intralesional bleomycin injection at newborn with huge cystic hygroma: case report. *CausePedia* 2014; 3: 777.
4. Romeo V, Maurea S, Guarino S, Sirignano C, Mainenti PP, Piccardi M, et al. A case of lower-neck cystic lymphangioma: correlative US, CT and MR imaging findings. *Quant Imaging Med Surg* 2013; 3: 224-7.
5. Giguère CM, Bauman NM, Smith RJ. New treatment options for lymphangioma in infants and children. *Ann Otol Rhinol Laryngol* 2002; 111: 1066-75. [\[CrossRef\]](#)
6. Sayan A, Ozdemir T, Can M, Arıkan A, Bayol U. Intralesional bleomycin injection in lymphangiomas treatment in children. *Tepecik Eğit Hast Derg* 2009; 19: 127-32. [\[CrossRef\]](#)
7. Okada A, Kubota A, Fukuzawa M, Imura K, Kamata S. Injection of bleomycin as a primary therapy of cystic lymphangioma. *J Pediatr Surg* 1992; 27: 440-3. [\[CrossRef\]](#)
8. Churchill P, Otal D, Pemberton J, Ali A, Flageole H, Walton JM. Sclerotherapy for lymphatic malformations in children: a scoping review. *J Pediatr Surg* 2011; 46: 912-22. [\[CrossRef\]](#)
9. Sanlıalp I, Karnak I, Tanyel FC, Senocak ME, Büyükpamukçu N. Sclerotherapy for lymphangioma in children. *Int J Pediatr Otorhinolaryngol* 2003; 67:795-800. [\[CrossRef\]](#)
10. Divarcı E, Çelik A, Kısmalı E, Ergün O. Management strategies in childhood lymphangiomas. *Çocuk Cerrahisi Dergisi* 2009; 23: 143-7.